

Pseudoaneurysm of the Petrous Internal Carotid: A Co-occurrence or a Complication of Chronic Otitis Media: A Case Report

KAMANA JYOTSNA DEVI¹, LOKESH KUMAR PENUBARTHI², GAYATHRI RAJANGAM³, ARUN ALEXANDER⁴



ABSTRACT

Although rare, a Petrous Internal Carotid Artery (ICA) pseudoaneurysm is a possible complication following chronic otitis media. A 57-year-old woman was brought to the Emergency Department with multiple painless episodes of right ear bleeding and epistaxis over the last two months. Upon evaluation, bony dehiscence was observed over the petrous carotid's first (proximal) genu, along with a pseudoaneurysm detected in the Magnetic Resonance Angiography (MR angiogram). The Balloon Occlusion Test (BTO) showed no cross-flow from the opposite side. Consequently, the patient was considered for high-flow bypass surgery between the external carotid artery and the M2 segment of the Middle Cerebral Artery (MCA), utilising a radial artery graft in the neurosurgery specialty. The present rare case report emphasises the significance of maintaining a high index of suspicion and implementing prompt intervention through a multidisciplinary approach. It also raises an open-ended question about whether the petrous carotid pseudoaneurysm is a complication of chronic otitis media or merely a co-occurrence.

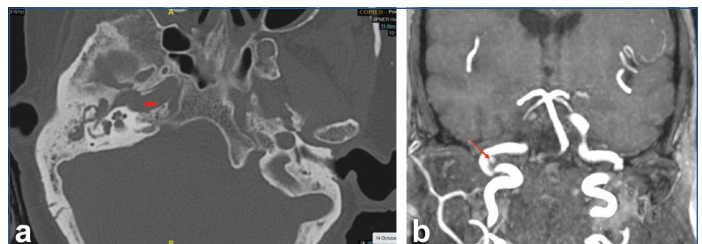
Keywords: Angiography, Bony dehiscence, Epistaxis, Occlusion test

CASE REPORT

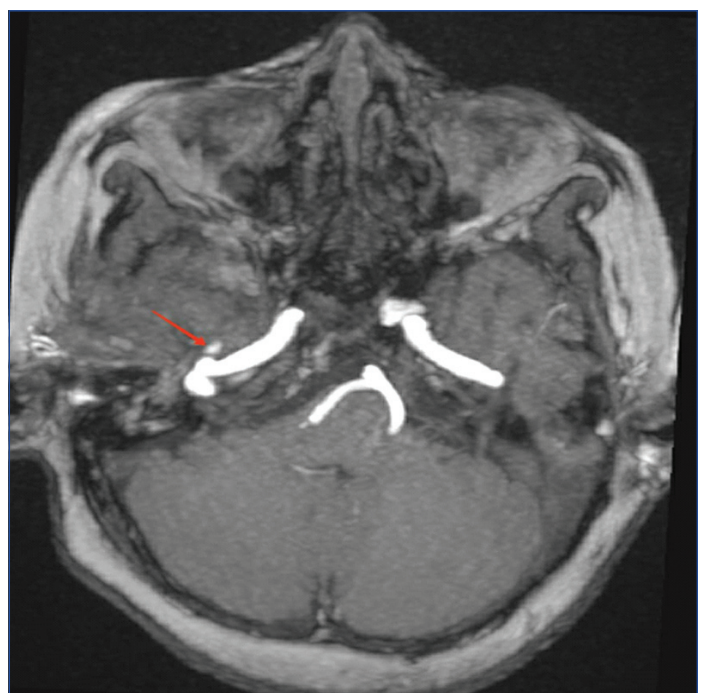
A 57-year-old diabetic woman presented to the Emergency Department of a tertiary care teaching hospital with a two month history of sudden, severe, and painless bleeding from her right ear and nose. Initially, the bleeding was minor but progressively worsened with each episode, always stopping spontaneously. There was no history of trauma to the ear or self-cleaning practices. Upon further inquiry, the patient disclosed a long-standing history of intermittent ear discharge, the exact duration of which was unclear, but it had not been bothersome enough in the past to seek medical attention. The patient denied experiencing hearing impairment, vertigo, headache, or any other symptoms typically associated with complications of chronic otitis media.

Upon examination, the patient was conscious and fully oriented. She appeared pale, and her pulses were feeble, with a heart rate of approximately 100 beats per minute and a blood pressure of 110/70 mmHg. Examination of the right ear revealed a normal ear canal, a subtotal perforation, and multiple clots within the ear canal and hypotympanum. The middle ear mucosa appeared slightly oedematous, while the attic region showed no abnormalities. Nasal and nasopharyngeal examinations were unremarkable, except for recent blood stains due to a bleeding episode.

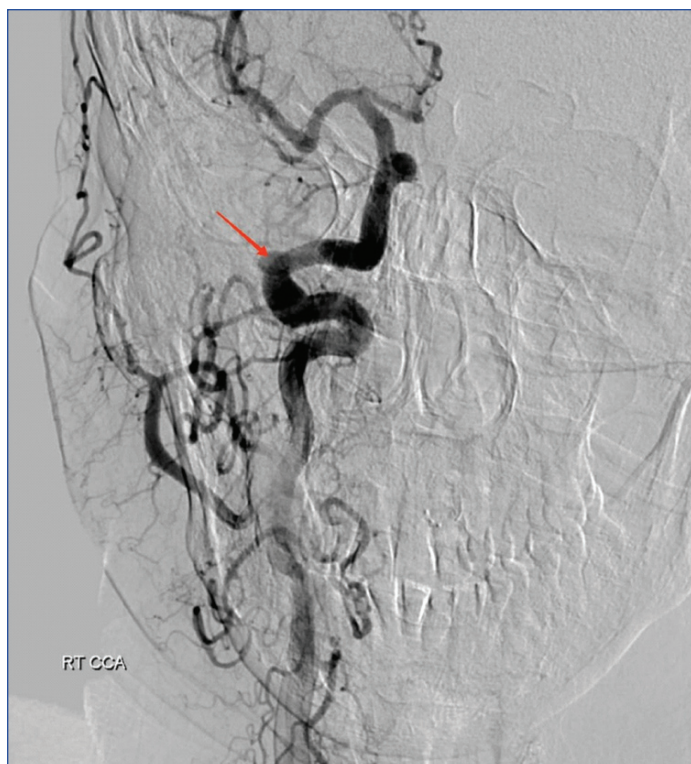Laboratory results indicated a recent haemoglobin level of 5 g/dL and a random blood sugar level of 189 mg/dL. High Resolution Computed Tomography (HRCT) of the temporal bone revealed erosion of the carotid plate at the proximal genu of the petrous carotid [Table/Fig-1a,b]. Additionally, MR angiogram identified a small outpouching measuring approximately 6.4×5.3×4.6 mm from the carotid artery, corresponding to the bone erosion observed in the Computed Tomography (CT) scan, confirming the presence of a pseudoaneurysm originating from the carotid artery [Table/Fig-2]. An attempt to coil the pseudoaneurysm was made, and the location and size of the pseudoaneurysm were confirmed through Digital Subtraction Angiography (DSA) [Table/Fig-3]. However, the coiling procedure was deferred due to a negative result on



[Table/Fig-1]: a) High-resolution CT showing carotid plate erosion over the proximal genu of the right petrous part of the internal carotid artery (red arrow), b) High resolution CT (coronal view) showing carotid plate erosion over the petrous part of right internal carotid artery (arrow).



[Table/Fig-2]: MR angiogram (axial view) showing outpouching from the lateral portion of the right petrous internal carotid artery (arrow).



[Table/Fig-3]: Digital Subtraction Angiography (DSA) showing an irregular aneurysm arising from the right petrous of internal carotid artery (arrow).

the BTO, indicating the absence of cross-circulation across the circle of Willis. The patient was subsequently referred to the Neurosurgery Department for high-flow bypass surgery, involving the connection between the external carotid artery and the M2 segment of the MCA using a radial artery graft. Postoperatively, the patient recovered well, and there were no further episodes of ear bleeding during her last follow-up six months after the above-mentioned surgery.

DISCUSSION

Petrous ICA is less susceptible to aneurysms than other intracranial arteries [1]. The petrous ICA can develop a pseudoaneurysm due to a gunshot wound, arterial dissection, an invasive tumour, radiation treatment, fibromuscular disease, or a surgical complication [2,3]. There have been very few case reports about pseudoaneurysms in atticotranal chronic otitis media with intracranial complications. Oyama H et al., noted a similar case of chronic otitis media associated with a pseudoaneurysm involving the petrous ICA. They also performed DSA with coil embolisation of the distal ICA and ligation of the proximal ICA with ECA-MCA bypass using a vein graft [4]. Postoperative/post-intervention outcomes of these petrous ICA aneurysms are usually good if intervened appropriately [5,6]. After the surgery, authors patient also did not experience ear bleeding, as seen in present case. Direct pressure of the pseudoaneurysm on the nerves can cause nerve function disturbances such as facial numbness, diplopia, seventh cranial nerve dysfunction, and auditory dysfunction [7]. Early detection and management are essential prerequisites to avoid mortality in these cases [8,9]. In cases of life-threatening haemorrhage, surgical or endovascular ICA occlusion is possible if the patient passes a Balloon Test Occlusion (BTO) [10].

The management of petrous ICA pseudoaneurysms has included several surgical and endovascular techniques. Endovascular procedures include balloon embolisation, coil embolisation, stand-alone stenting, and stent-assisted coiling [11]. In the present case, the patient failed BTO, so embolisation and coiling were deferred. After discussion in the multidisciplinary meeting involving otolaryngology, neuroradiology, and neurosurgery, it was decided

to perform a high-flow External Carotid and Middle Cerebral Artery (ECA-M2) bypass. Other surgical options available in failed BTO cases are Extra-to Intracranial (EC-IC) bypass surgery, using saphenous vein or radial artery grafts; bypasses can be performed from the superficial temporal artery to the MCA or from the external carotid artery to the MCA [12,13].

Authors patient presented late to us after episodes of sentinel bleeds. Authors saved patient by immediately diagnosing and treating her with a multidisciplinary approach. Theoretically, there is a possibility that chronic infection around the carotid or any major artery can weaken its wall, thereby forming a pseudoaneurysm called infectious pseudoaneurysms. The pseudoaneurysm of the petrous carotid as a complication of chronic otitis media has not been mentioned in any of the standard textbooks of otology and neurotology. As the pseudoaneurysm was found along with the subtotal perforation and haziness in the mastoid air cells (CT findings), authors hypothesised it could be secondary to chronic otitis. Nevertheless, through present case report, authors left an open-ended question to the readers about whether the petrous carotid pseudoaneurysm is a complication of chronic otitis media or a co-incidence.

CONCLUSION(S)

Patients who experience recurring sentinel ear bleeds should undergo a comprehensive investigation. An infrequent complication in chronic otitis media is the development of a petrous ICA aneurysm. A combination of CT, Magnetic Resonance Imaging (MRI), and DSA must be considered to plan the appropriate treatment approach. Managing such cases necessitates a multidisciplinary approach involving neurosurgery and vascular surgery, particularly when high-flow bypass surgeries are required, as was the case here. This instance underscores the significance of maintaining a high level of suspicion, promptly implementing interventional radiology procedures, and coordinating the efforts of various medical specialties to manage such critical cases.

Acknowledgement

I would like to thank Dr. K Nagarajan, Professor, Department of Radiodiagnosis for his efforts and generous support for the case report.

REFERENCES

- [1] Traumatic cerebral aneurysms - PMC [Internet]. [cited 2022 Dec 16]. Available from: <https://www.ncbi.nlm.nih.gov/pmc/articles/PMC494287/>.
- [2] Chiappetta F, Vangelista S, Pirrone R. Recurrent massive otorrhagia caused by a petrous carotid aneurysm. *J Neurosurg Sci*. 1982;26(3):205-07.
- [3] Auyeung KM, Lui WM, Chow LCK, Chan FL. Massive epistaxis related to petrous carotid artery pseudoaneurysm after radiation therapy: Emergency treatment with covered stent in two cases. *AJNR Am J Neuroradiol*. 2003;24(7):1449-52.
- [4] Oyama H, Hattori K, Tanahashi S, Kito A, Maki H, Tanahashi K. Ruptured pseudoaneurysm of the petrous internal carotid artery caused by chronic otitis media. *Neurol Med Chir (Tokyo)*. 2010;50(7):578-80. Doi: 10.2176/nmc.50.578. PMID: 20671385.
- [5] Kimmelman CP, Grossman R. Intratemporal carotid aneurysm as a complication of chronic otitis media: Treatment with balloon catheter obliteration. *Otolaryngol Head Neck Surg*. 1983;91(3):306-08.
- [6] Costantino PD, Russell E, Reisch D, Breit RA, Hart C. Ruptured petrous carotid aneurysm presenting with otorrhagia and epistaxis. *Am J Otol*. 1991;12(5):378-83.
- [7] Mangat SS, Nayak H, Chandna A. Horner's syndrome and sixth nerve paresis secondary to a petrous internal carotid artery aneurysm. *Semin Ophthalmol*. 2011;26(1):23-24.
- [8] Willinsky R, Lasjaunias P, Pruvost P, Boucherat M. Petrous internal carotid aneurysm causing epistaxis: Balloon embolization with preservation of the parent vessel. *Neuroradiology*. 1987;29(6):570-72.
- [9] McGrail KM, Heros RC, Debrun G, Beyerl BD. Aneurysm of the ICA petrous segment treated by balloon entrapment after EC-IC bypass. *Case report. J Neurosurg*. 1986;65(2):249-52.
- [10] Fleischer AS, Guthkelch AN. Management of high cervical-intracranial internal carotid artery traumatic aneurysms. *J Trauma*. 1987;27(3):330-32.
- [11] Alexander MJ, Smith TP, Tucci DL. Treatment of an iatrogenic petrous carotid artery pseudoaneurysm with a Symbiot covered stent: Technical case report. *Neurosurgery*. 2002;50(3):658-62.

[12] Jafar JJ, Russell SM, Woo HH. Treatment of giant intracranial aneurysms with saphenous vein extracranial-to-intracranial bypass grafting: Indications, operative technique, and results in 29 patients. *Neurosurgery*. 2002;51(1):138-44; discussion 144-146.

[13] Regli L, Piepgras DG, Hansen KK. Late patency of long saphenous vein bypass grafts to the anterior and posterior cerebral circulation. *J Neurosurg*. 1995;83(5):806-11.

PARTICULARS OF CONTRIBUTORS:

1. Senior Resident, Department of Ear, Nose and Throat, JIPMER, Puducherry, India.
2. Assistant Professor, Department of Ear, Nose and Throat, JIPMER, Puducherry, India.
3. Junior Resident, Department of Ear, Nose and Throat, JIPMER, Puducherry, India.
4. Professor, Department of Ear, Nose and Throat, JIPMER, Puducherry, India.

NAME, ADDRESS, E-MAIL ID OF THE CORRESPONDING AUTHOR:

Lokesh Kumar Penubarthi,
Dhanvantri Nagar, Puducherry-605006, India.
E-mail: lokesh86p@gmail.com

PLAGIARISM CHECKING METHODS: [\[Jain H et al.\]](#)

- Plagiarism X-checker: Jul 24, 2023
- Manual Googling: Oct 19, 2023
- iThenticate Software: Nov 10, 2023 (2%)

ETYMOLOGY: Author Origin**EMENDATIONS:** 6**AUTHOR DECLARATION:**

- Financial or Other Competing Interests: None
- Was informed consent obtained from the subjects involved in the study? Yes
- For any images presented appropriate consent has been obtained from the subjects. Yes

Date of Submission: **Jul 24, 2023**Date of Peer Review: **Oct 08, 2023**Date of Acceptance: **Nov 13, 2023**Date of Publishing: **Jan 01, 2024**