

# Chondromyxoid Fibroma of the Metatarsal Head: A Rare Case Report

PRADHEER GUPTA<sup>1</sup>, N VISHNU VARDHAN<sup>2</sup>, BIJU RAVINDRAN<sup>3</sup>, KHARIDEHAL DURGA<sup>4</sup>, SAHAJ MARTHATHI<sup>5</sup>

(CC) BY-NC-ND

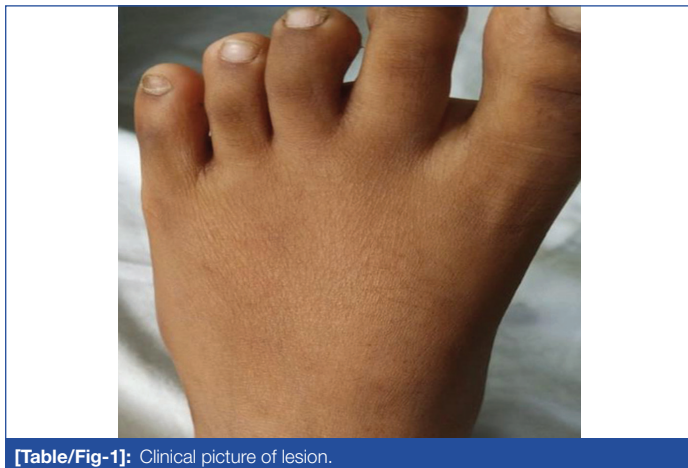## ABSTRACT

Chondromyxoid Fibroma (CMF) is an uncommon non malignant cartilage tumour with a greater predilection for the legs, with about a quarter of cases involving the metatarsals. It accounts for less than 0.5% of all bone tumours and mostly occurs in patients aged 10 to 30 years old. Patients typically present with complaints of pain and swelling in the affected region. Radiologically, a lytic lesion with well-defined margins is observed in the metaphysis. The present case is about an 11-year-old male who presented to the Orthopaedic Outpatient Department (OPD) with a history of pain and swelling over his left foot. Upon examination, a discrete swelling was noted over the lateral aspect of the foot, extending from the head to the shaft of the 4<sup>th</sup> metatarsal. Upon palpation, the swelling was found to be tender and firm in consistency, accompanied by restricted foot movement. Initially, a giant cell tumour of the 4<sup>th</sup> metatarsal bone in the left foot was suspected based on radiography. However, histopathological examination led to the diagnosis of CMF. The lesion was curetted, and a below-knee Plaster of Paris (POP) was applied for one month. No recurrence of the lesion has been observed after five months of follow-up.

**Keywords:** Adolescent chondroblastoma, Bone neoplasm's, Bone exostoses, Giant cell tumour

## CASE REPORT

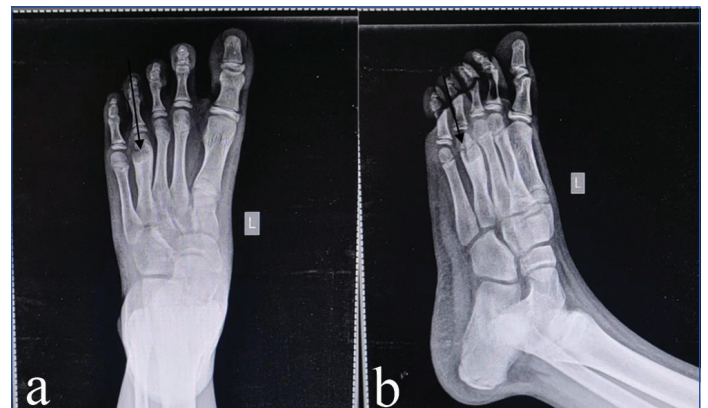
An 11-year-old male patient presented to the Orthopaedic (OPD) with outpatient department with complaints of discomfort, soreness, and swelling on the dorsum of the left foot, which had been present for one year. The swelling was associated with pain. There was no significant previous medical history or any history of trauma. On examination, a discrete swelling was noted over the lateral aspect of the foot, defined margins near the head of the 4<sup>th</sup> metatarsal extending to the shaft. On palpation, the swelling was tender and firm in consistency. Inversion and eversion of the foot were restricted [Table/Fig-1].



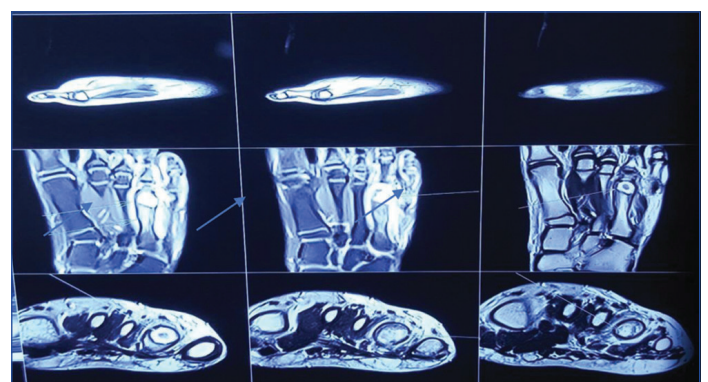
[Table/Fig-1]: Clinical picture of lesion.

Radiological investigations revealed a plain radiograph of the left foot showing a lytic lesion with well-defined margins near the head of the 4<sup>th</sup> metatarsal extending to the shaft. The lesion breached the cortex with sclerosis of margins, suggestive of a benign bone tumour [Table/Fig-2a,b].

Magnetic Resonance Imaging (MRI) of the left foot showed a tiny, irregular, well-defined lytic lesion in the distal metaphysis of the left 4<sup>th</sup> metatarsal. The lesion was approximately 13×11 mm in size and surrounded by widespread bone marrow oedema. The lesion was hyperintense on diffusion-weighted T2 imaging and hypointense on the T1-weighted (T1W) image. The lesion had spread slightly into the surrounding soft tissue. A provisional diagnosis of a giant cell tumour of bone was made [Table/Fig-3].



[Table/Fig-2]: Anteroposterior and oblique view of plain radiograph of left foot showing lesion at head of 4<sup>th</sup> metatarsal bone.



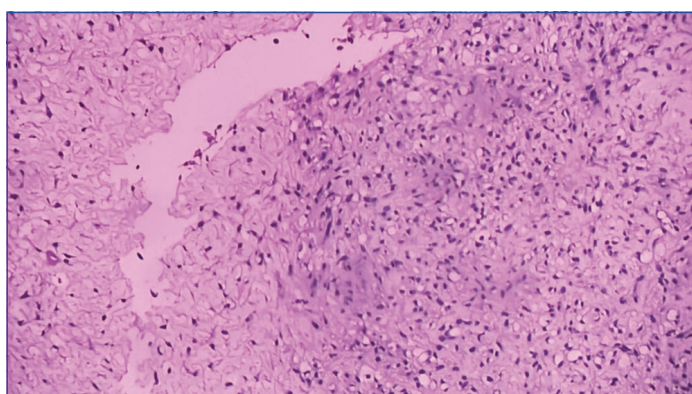
[Table/Fig-3]: MRI image of left foot, coronal and sagittal sections, showing hyperintensity in T2 diffusion-weighted image.

Before the surgical intervention, routine blood investigations were conducted, in which a complete blood count showed Haemoglobin (Hb)-11.4 gm/dL, total leukocyte counts -11,300 cells/cubic mm, and a platelet count of 4.77 lacs/cubic mm. Routine biochemical investigations showed Random Blood Sugar (RBS) of 95.65 mg/dl, Erythrocyte Sedimentation Rate (ESR) was 77 mm, and Human Immunodeficiency Virus (HIV) and Hepatitis B surface Antigen (HBsAg) test were negative. The lesion was curetted and removed, and the specimens were submitted for histopathological evaluation. A below knee Plaster of Paris (POP) slab was applied on the plantar

aspect of the foot, extending from the proximal phalanx of the foot to the level of the tibial tuberosity, with the ankle joint in a neutral position for one month. Full weight-bearing was allowed.

An aspirate was sent for culture, which showed no bacterial growth after 48 hours of aerobic incubation. Grossly, many grey-white bits of bone and soft tissue were received with a total dimension of 0.8x0.8 cm.

The sections were prepared and stained with Haematoxylin and Eosin (H&E). Microscopic examination of the sections showed lobules. The centre of the lobules contained loose myxoid tissue, showing spindle cells and some stellate cells. The periphery of the lobules contained fibrous tissue with fibroblastic septa and enhanced cellularity. Occasional foci exhibited multinucleated large cells of osteoclastic type. Mild nuclear atypia was found in the stromal cells. No mitoses, necrosis, or calcifications were identified. The background appears chondroid, although distinct areas of hyaline cartilage were absent. There was no evidence of malignancy in the sections studied [Table/Fig-4]. Based on the histopathological examination, the final diagnosis was CMF.



**[Table/Fig-4]:** Spindle cells admixed with giant cells in a lobular myxoid background. Mild nuclear atypia noted in the stromal cells along with nodular areas of chondroid tissue separated by fibromyxoid areas (H&E, 100x).

The postoperative timeline was uncomplicated. Currently, the patient is under follow-up and is doing well five months following treatment.

The differential diagnosis for this case includes acute osteomyelitis, aneurysmal bone cyst, enchondroma, chondroblastoma, non ossifying fibroma, and low grade chondrosarcoma. The architecture of CMF contains nodular areas of chondroid tissue separated by fibromyxoid areas.

## DISCUSSION

Chondromyxoid fibroma (CMF) is an uncommon non malignant cartilage tumour, comprising less than 1% of all bone exostoses, and is characterised by incomplete cartilage maturation [1]. Originally characterised by Jaffe HI and Lichtenstein L in 1948 [2], CMF mainly affects adolescents and young adults in the second or third decade of life [2].

The CMF grows within the medullary cavity of the metaphysis and is eccentrically located in the distal part of the thigh bone and proximal tibia. However, it can also occur in areas such as the skull bones, mandible, ilium, ribs, metacarpals, and metatarsals, thereby leading to diagnostic difficulties [3].

Patients frequently complain of a slowly increasing, uncomfortable bump. Usually, CMF is an incidental finding in routine radiography. There is a long history of chronic local pain, swelling, and oedema with a palpable soft-tissue mass and restricted movements in the affected joint. Pathologic fracture may also develop [3].

Radiologically, CMF is described as an eccentric, lobulated, expansive, and lytic lesion with well-defined scalloped or lobulated margins and sclerotic bone formation. CMF appears to elevate the periosteum, with radiolucency [4]. Calcification, partial cortical erosion, and septations are noted in a few cases. In the present case, an MRI scan showed

a tiny, irregular, well-defined lytic lesion in the distal metaphysis surrounded by widespread bone marrow oedema. The differential diagnoses in radiology include giant cell tumour, aneurysmal bone cyst, chondroblastoma, and fibrous dysplasia [4]. In the present case, based on clinical and radiological investigations, a provisional diagnosis of giant cell tumour of bone was made.

The features of CMF on histopathological examination are the lobules of myxoid tissue and cartilage-like tissue surrounded by zones of hypercellular fibrous tissue. Well-defined bodies or osteoid tissue are not seen. Rarely, anaplasia within CMF has been observed [5]. In the present case, histopathological examination showed bone trabeculae with spindle cells and a few stellate cells in a myxoid matrix. Fibroblastic septa with enhanced cellularity were found between these cells. Occasional foci exhibit multinucleated large cells of osteoclastic type. Mild nuclear atypia was detected in stromal cells. The background shows chondroid tissue, although distinct areas of hyaline cartilage were absent. These findings were congruent with the CMF [6,7]. The histopathological differential diagnosis of CMF includes myxoid chondrosarcoma and chondroblastoma. Chondrosarcoma shows lobules with the presence of plump, bizarre cells with multiple nuclei.

The optimal therapy for CMF is curettage with or without bone grafting. The preferred treatment is en-bloc resection with allograft and artificial bone grafts. Radiation therapy is indicated in surgically inaccessible tumours [8]. In the present case, wide curettage of the metatarsal was done to minimise the risk of recurrence.

Han JS et al., published a case of CMF occurring within the cortex of the shaft of the metatarsal in a 17-year-old adolescent, and Dey B et al., reported a similar case in the first metatarsal of a 26-year-old male who complained of a tender bump over the right foot for six years. A radiograph showed an osteolytic lesion in the distal end of the first metatarsal. Both patients were diagnosed on histopathologic assessment following excision of the tumour as CMF [9,10].

The CMF is an uncommon non malignant cartilage tumour that occasionally poses a major diagnostic problem, especially when it arises in odd sites [11]. Radiological findings can occasionally be deceptive, as in the present instance. So, histopathological examination is the gold standard for a definitive diagnosis.

## CONCLUSION(S)

The CMF is a rare benign cartilaginous tumour usually involving the metaphysis. Radiological findings are often misleading, as in the present case, where it was initially reported as a giant cell tumour of the metatarsal. Histopathological examination is required for a definitive diagnosis. As the recurrence rate of CMF is high, a correct diagnosis and wide surgical curettage are required, along with regular follow-up.

## Acknowledgement

The authors are thankful to the patient and guardians for consenting to participate in the present study.

## REFERENCES

- [1] Jadaun G, Gupta H, Kharodia S, Gadhiya V. Rapidly expanding chondromyxoid fibroma of the mandible: A case report of rare entity. *J Oral Maxillofac Pathol.* 2023;27(Suppl 1):S104-08. Doi: 10.4103/jomfp.jomfp\_351\_21. Epub 2023 Feb 4. PMID: 37082290; PMCID: PMC10112688.
- [2] Jaffe HI, Lichtenstein L. Chondromyxoid fibroma of bone; A distinctive benign tumour likely to be mistaken especially for chondrosarcoma. *Arch Pathol (Chic).* 1948;45(4):541-51. PMID: 18891025.
- [3] El-Kouri N, Elghoucha A, Chen S, Shipchandler T, Ting J. Sinonasal Chondromyxoid fibroma: Case report and literature review. *Cureus.* 2019;11[10]:e5841. Doi: 10.7759/cureus.5841. PMID: 31754576; PMCID: PMC6830535.
- [4] Sathia S, Jain M, Nayak M, Purkait S. Chondromyxoid fibroma of a rib. *J Orthop Case Rep.* 2023;13(1):92-95. Doi: 10.13107/jocr.2023.v13.i01.3528. PMID: 37143567; PMCID: PMC10152961.
- [5] Li C, Li S, Hu W. Chondromyxoid fibroma of the cervical spine: A case report. *World J Clin Cases.* 2022;10(17):5748-55. Doi: 10.12998/wjcc.v10.i17.5748. PMID: 35979139; PMCID: PMC9258375.

- [6] Hwang SM, Cho KH, Kim HD, Jung YH, Kim HI. Chondromyxoid fibroma of the finger. *Arch Plast Surg*. 2014;41(3):302-04. Doi: 10.5999/aps.2014.41.3.302. Epub 2014 May 12. PMID: 24883287; PMCID: PMC4037782.
- [7] Oh SJ, Chung SH. Juxtacortical chondromyxoid fibroma in the small bones: Two cases with unusual location and a literature review. *J Pathol Transl Med*. 2022;56(3):157-60. Doi: 10.4132/jptm.2021.12.15. Epub 2022 Jan 21. PMID: 35051327; PMCID: PMC9119803.
- [8] Vasudeva N, Shyam Kumar C, Ayyappa Naidu CR. Chondromyxoid fibroma of distal phalanx of the great toe: A rare clinical entity. *Cureus*. 2020;12(2):e7133. Doi: 10.7759/cureus.7133. PMID: 32257678; PMCID: PMC7105257.
- [9] Han JS, Shim E, Kim BH, Choi JW. An intracortical chondromyxoid fibroma in the diaphysis of the metatarsal. *Skeletal Radiol*. 2017;46(12):1757-62. Doi: 10.1007/s00256-017-2743-1. Epub 2017 Aug 15. PMID: 28808739.
- [10] Dey B, Deshpande AH, Brar RK, Ray A. Chondromyxoid fibroma of the metatarsal bone: A diagnosis using fine needle aspiration biopsy. *J Cytol*. 2018;35(1):67-68. Doi: 10.4103/JOC.JOC\_48\_17. PMID: 29403178; PMCID: PMC5795736.
- [11] Bagewadi RM, Nerune SM, Hippargi SB. Chondromyxoid fibroma of radius: A case report. *J Clin Diagn Res*. 2016;10(5): ED01-02. Doi: 10.7860/JCDR/2016/17967.7728. Epub 2016 May 1. PMID: 27437232; PMCID: PMC4948408.

**PARTICULARS OF CONTRIBUTORS:**

1. Postgraduate, Department of Orthopaedics, Narayana Medical College and Hospital, Nellore, Andhra Pradesh, India.
2. Associate Professor, Department of Orthopaedics, Narayana Medical College and Hospital, Nellore, Andhra Pradesh, India.
3. Professor and Head, Department of Orthopaedics, Narayana Medical College and Hospital, Nellore, Andhra Pradesh, India.
4. Professor and Head, Department of Pathology, Narayana Medical College and Hospital, Nellore, Andhra Pradesh, India.
5. Postgraduate, Department of Orthopaedics, Narayana Medical College and Hospital, Nellore, Andhra Pradesh, India.

**NAME, ADDRESS, E-MAIL ID OF THE CORRESPONDING AUTHOR:**

Dr. N Vishnu Vardhan,  
Associate Professor, Department of Orthopaedics, Narayana Medical College and Hospital, Nellore-524002, Andhra Pradesh, India.  
E-mail: drnvishnuvardhanreddy@gmail.com

**PLAGIARISM CHECKING METHODS:** [Jain H et al.]

- Plagiarism X-checker: Oct 04, 2023
- Manual Googling: Dec 19, 2023
- iThenticate Software: Jan 04, 2024 (20%)

**ETYMOLOGY:** Author Origin**EMENDATIONS:** 6**AUTHOR DECLARATION:**

- Financial or Other Competing Interests: None
- Was informed consent obtained from the subjects involved in the study? Yes
- For any images presented appropriate consent has been obtained from the subjects. Yes

Date of Submission: **Oct 03, 2023**Date of Peer Review: **Dec 16, 2023**Date of Acceptance: **Jan 06, 2024**Date of Publishing: **Mar 01, 2024**