

# Foreign Body causing Diagnostic Dilemma in Koch's Abdomen Patient Presenting with Acute Intestinal Obstruction: A Case Report

RANENDRA HAJONG<sup>1</sup>, KAMTHAMUON NEIHSIAL<sup>2</sup>, ARUP J BARUAH<sup>3</sup>, DATHIADAM TONGPER<sup>4</sup>, PINKY RABHA<sup>5</sup>



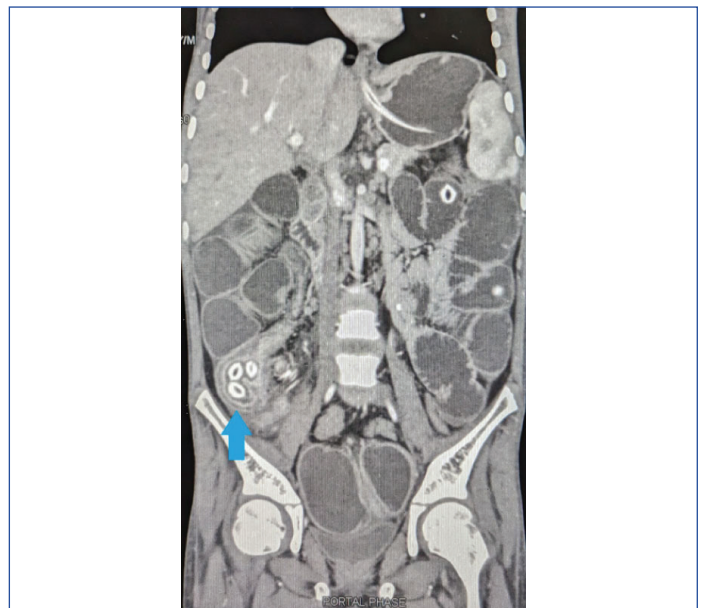## ABSTRACT

The ileocaecal region is the most commonly affected region in Koch's abdomen; however, it can involve any part of the Gastrointestinal Tract (GIT). Patients usually present late with either features of acute or subacute intestinal obstruction or with features of perforation peritonitis. Early diagnosis of abdominal Tuberculosis (TB) is still challenging due to the vague and non specific symptomatology of the disease. Hereby, the authors present a case report of 11-year-old boy who was on Antitubercular Treatment (ATT) for suspected abdominal TB, presented with features of subacute intestinal obstruction which subsequently had to be operated for acute obstruction. However, the cause of obstruction was not due to the complications of abdominal TB but due to the mechanical obstruction caused by the seeds of bayberry, which got obstructed in the relatively narrowed part of the ileocaecal region due to thickening of the bowel wall. No similar case reports have been found in the literature earlier. Hence, the present case is being reported.

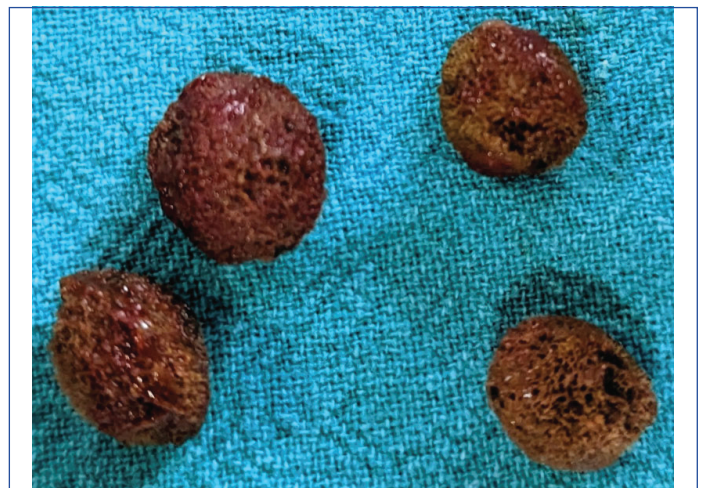
**Keywords:** Abdominal tuberculosis, Local fruits, Pain abdomen, Seeds ingestion, Vomiting

## CASE REPORT

An 11-year-old boy presented to the Emergency Department of the hospital with the chief complaint of pain in his abdomen and abdominal distension for two days. He had 2-3 episodes of vomiting which were non projectile and bilious in nature. The pain was colicky in nature. On examination, there was dehydration with mild pallor. The abdomen was distended with no tenderness or rigidity. He did not pass stool and flatus since then. The patient's father gave a history of Antitubercular Treatment (ATT) for suspected Koch's abdomen for the last two months, as the boy had an evening rise of temperature with a history of contact with a relative who was suffering from pulmonary TB. The patient was kept nil per orally and planned for conservative management along with the insertion of a nasogastric tube for decompression. On investigation, all routine parameters were found to be within normal limits except slightly low haemoglobin, and X-ray abdomen showed dilated small bowel loops. On the third day, the patient complained of an increase in the intensity of pain in the abdomen. Hence, a Computed Tomography (CT) scan of the abdomen was done which showed dilated small bowel loops with a collapsed large bowel. Multiple oval-shaped calcified foci (suspected faecoliths as per the radiologist) were seen within the bowel lumen in the caecum [Table/Fig-1]. Circumferential mural thickening of the terminal ileum and caecum were noted. Multiple enlarged lymph nodes were noted in mesenteric, paraaortic, left gastric, and common hepatic stations, the largest measuring 19 mm in the mesenteric station. Exploratory laparotomy was planned. On opening the abdomen, dilated small bowel loops were seen up to the distal ileum with enlarged mesenteric lymphadenopathy. The caecum was thickened and was firm to hard in consistency. Enterotomy was done approximately 15 cm proximal from the ileocaecal junction as that part of the intestine was normal in thickness. Intestinal content was evacuated from the enterotomy and also the suspected stones were retrieved through the enterotomy. On closer inspection, the suspected stones were found to be seeds of Bayberry (locally known as Sohphie) [Table/Fig-2]. Side-to-side ileo-ascending anastomosis was done to prevent future recurrence of intestinal obstruction as the caecum and terminal ileum were thickened (without resecting the thickened parts and as the ascending colon was healthy). Histopathological examination from the mesenteric



**[Table/Fig-1]:** Computed Tomography (CT) scan showing radiopaque material in right iliac fossa (blue arrow).



**[Table/Fig-2]:** Extracted foreign bodies.

lymph nodes showed multiple caseating granulomas consisting of central caseation surrounded by epithelioid histiocytes, Langhan's giant cells rimmed by lymphocytes and plasma cells. Ziehl-Neelsen stain for acid-fast bacilli showed positivity for degenerated bacilli. Cartridge-based Nucleic Acid Amplification Test (CBNAAT) from the nodal tissue showed low uptake. The patient recovered well and was discharged home on antitubercular medications. The patient is doing well till six months of postoperative follow-up.

## DISCUSSION

Tuberculosis is a common disease worldwide with a higher prevalence in developing countries [1,2]. Any part of the body may be affected by TB, and the abdomen is one of the more common sites of involvement after the lungs and bones [3]. Gastrointestinal (GI) TB accounts for 1% to 3% of all TB cases [1,2]. The ileocaecal region is the most commonly affected region in Koch's abdomen; however, it can involve any part of the GIT [3,4]. Early diagnosis of abdominal TB is still challenging as the disease usually runs an indolent course with vague and non specific symptomatology [5]. More commonly, patients present with features of acute or subacute intestinal obstruction due to tuberculoma or stricture formation in the small gut or with features of perforation peritonitis [6].

Intestinal obstruction caused by fruit seeds is a rare phenomenon, as the seeds are usually oval in shape and once swallowed allows them to pass through the pylorus and be excreted naturally through the anus [7]. However, bezoar (seeds) may cause acute intestinal obstruction in 0.4 to 4% of cases [8]. In most cases, seed bezoars were found in the rectum (78%), followed by the terminal ileum (16%), sigmoid colon, stomach, jejunum, duodenum, and caecum [9].

Foreign body ingestion in children is common, with approximately 70,000 cases being reported annually in patients less than six years of age [10]. The presentations are varied [11]. Most ingested foreign bodies pass spontaneously; however, in 10% to 20% of cases, endoscopic retrieval may be required. Surgical removal of foreign bodies is required in approximately 1% of cases [12]. Ultrasonography (US) is usually the first investigation to look for suspected ingested foreign bodies in children as it does not involve radiation exposure. In equivocal cases, CT scans have been recommended, even though visualisation of the ingested foreign body will depend on its radiodensity [13].

Intestinal obstruction caused by a foreign body in a known case of TB abdomen patient on ATT is rare. In the instant case, the bayberry seeds were found obstructed in the caecum, which was thickened including part of the terminal ileum with multiple mesenteric lymphadenopathies due to TB. Foreign bodies getting obstructed in the caecum is extremely rare as the caecum is normally patulous.

However, due to narrowing either at or distal to the caecum as a late sequelae of TB or Crohn's disease, foreign bodies may get obstructed in the caecum resulting in acute intestinal obstruction. No similar type of case has been reported in the literature.

The diagnosis of ingested foreign body preoperatively, even by radiological imaging, is still challenging, with many ingested foreign objects being determined only at extraction by endoscopy or surgery [14]. In the present case too, preoperatively, the radiopaque shadows seen in the ileocaecal region were thought to be faecoliths; which subsequently were confirmed to be bayberry seeds at operation.

## CONCLUSION(S)

Children often tend to gulp food without properly chewing, resulting in the swallowing of seeds that may lead to intestinal obstruction. Especially when the intestinal lumen is compromised due to TB or Crohn's disease, the supposedly benign seeds may get obstructed easily, causing intestinal obstruction. Even though intestinal obstruction caused by seeds is uncommon, it should be a part of the differential diagnosis in children.

## REFERENCES

- [1] Sheer TA, Coyle WJ. Gastrointestinal tuberculosis. *Curr Gastroenterol Rep.* 2003;5(4):273-78.
- [2] Farer LS, Lowell AM, Meador MP. Extrapulmonary tuberculosis in the United States. *Am J Epidemiol.* 1979;109(2):205-17.
- [3] Horvath KD, Whelan RL. Intestinal tuberculosis: Return of an old disease. *Am J Gastroenterol.* 1998;93(5):692-96.
- [4] Rathi P, Gambhire P. Abdominal tuberculosis. *J Assoc Physicians India.* 2016;64(2):38-47.
- [5] Shaikh MS, Ramdholia K, Jaibani MA, Shaikh SA. Prevalence of intestinal tuberculosis in cases of acute abdomen. *Pak J Surg.* 2007;23(1):52-56.
- [6] Ahmed M, Mainghal MA. Pattern of mechanical intestinal obstruction in adults. *J Coll Physicians Surg Pak.* 1999;9(10): 441-43.
- [7] Gumus M, Kapan M, Onder A, Yagmur Y. An unusual cause of small bowel obstruction; Dried apricots. *J Pak Med Assoc.* 2011;61(11):1130-31.
- [8] Teng HC, Nawawi O, Ng KL, Yik YI. Phytobezoar: An unusual cause of intestinal obstruction. *Biomed Imaging Interv J.* 2005;1(1):e4.
- [9] Manatakis DK, Acheimastos V, Antonopoulou MI, Balalis D, Korkolis DP. Gastrointestinal seed bezoars: A systematic review of case reports and case series. *Cureus.* 2019;11(5):e4686. Doi: 10.7759/cureus.4686.
- [10] Gummin DD, Mowry JB, Spyker DA, Brooks DE, Beuhler MC, Rivers LJ. Annual report of the American Association of poison control centers' National Poison Data System (NPDS): 36<sup>th</sup> annual report [published correction appears in *Clin Toxicol (Phila)*. 2019 Dec;57(12):e1]. *Clin Toxicol (Phila)* 2018;57(12):1220-413.
- [11] Gurevich Y, Sahn B, Weinstein T. Foreign body ingestion in pediatric patients. *Curr Opin Pediatr.* 2018;30(5):677-82.
- [12] Thomson M, Tringali A, Dumonceau JM, Tavares M, Tabbers MM, Furlano R. Paediatric gastrointestinal endoscopy: European society for paediatric gastroenterology hepatology and nutrition and European society of gastrointestinal endoscopy guidelines. *J Pediatr Gastroenterol Nutr.* 2017;64(1):133-53.
- [13] Tseng HJ, Hanna TN, Shuaib W, Aized M, Khosa F, Linnau KF. Imaging foreign bodies: Ingested, aspirated, and inserted. *Ann Emerg Med.* 2015;66(6):570-82.
- [14] Khan MR, Khan IR, Pal KNM. Diagnostic issues in abdominal tuberculosis. *J Pak Med Assoc.* 2001;51(4):138-42.

### PARTICULARS OF CONTRIBUTORS:

1. Professor, Department of General Surgery, NEIGRIHMS, Shillong, Meghalaya, India.
2. Senior Resident, Department of General Surgery, NEIGRIHMS, Shillong, Meghalaya, India.
3. Professor, Department of General Surgery, NEIGRIHMS, Shillong, Meghalaya, India.
4. Additional Professor, Department of General Surgery, NEIGRIHMS, Shillong, Meghalaya, India.
5. Senior Resident, Department of General Surgery, NEIGRIHMS, Shillong, Meghalaya, India.

### NAME, ADDRESS, E-MAIL ID OF THE CORRESPONDING AUTHOR:

Dr. Ranendra Hajong,  
Professor, Department of General Surgery, NEIGRIHMS,  
Shillong-793018, Meghalaya, India.  
E-mail: ranenhajong@gmail.com

### PLAGIARISM CHECKING METHODS: [Jain H et al.]

- Plagiarism X-checker: Dec 04, 2023
- Manual Googling: Jan 23, 2024
- iThenticate Software: Feb 09, 2024 (10%)

### ETYMOLOGY: Author Origin

### EMENDATIONS: 6

### AUTHOR DECLARATION:

- Financial or Other Competing Interests: None
- Was informed consent obtained from the subjects involved in the study? Yes
- For any images presented appropriate consent has been obtained from the subjects. Yes

Date of Submission: **Nov 30, 2023**

Date of Peer Review: **Jan 19, 2024**

Date of Acceptance: **Feb 10, 2024**

Date of Publishing: **Apr 01, 2024**