

Omental Infarction: A Forgotten Entity

VIRENDRA ATHAVALE¹, RUSHABH PAREKH², SAILI KELSHIKAR³

ABSTRACT

Omental infarction is a cause of acute abdominal pain. It is a challenging diagnosis to make due to its infrequent occurrence, low awareness, and non specific presentation. It is generally recommended to manage it conservatively because of its self-limited nature. However, some physicians opt for surgical management due to the potential risk of abscess formation with conservative treatment. Omental infarction commonly occurs following torsion. The anatomical features of the omental sheet, such as its increased length, freely mobile lateral edge, and a weak blood supply, make it more susceptible to twisting along its long axis, leading to congestion. If the twist is severe enough or if there is prolonged obstruction to venous flow, arterial inflow may be compromised, resulting in infarction and potential complications like necrosis. Here, the authors present a case of a 64-year-old diabetic male who presented to the Emergency Department with acute right upper quadrant pain. He was diagnosed with omental infarction through Computed Tomography (CT) of the abdomen. The authors attempted conservative management, but his pain persisted despite analgesics. Subsequently, the authors opted for surgical intervention and performed an omentectomy. In cases of acute abdominal pain, conditions like omental infarction are often overlooked and should be considered in the differential diagnosis.

Keywords: Abdominal pain, Emergency, Ischaemia, Mass, Necrosis, Omentectomy, Torsion, Whirl sign

CASE REPORT

A 64-year-old diabetic male presented to the Emergency Department with acute right upper quadrant pain that had been ongoing for one day and was exacerbated by movement. There was no history of associated trauma, fever, vomiting, jaundice, changes in bowel or bladder habits, chest pain, or similar complaints in the past. Additionally, there was no significant past medical history or history of previous abdominal surgery.

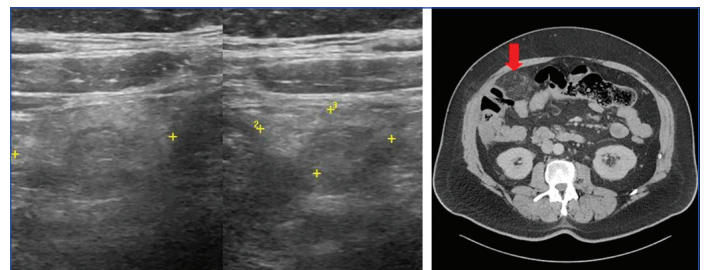
During the physical examination, he was conscious and oriented, with a pain score of 5 on the VAS rating scale. He had a body mass index of 30.7 kg/m². His vital signs included being afebrile, with a heart rate of 90/min, blood pressure of 130/80 mmHg, respiratory rate of 14, and maintaining a saturation of 96% on room air. His abdomen was soft, tender in the right hypochondrium, with no signs of peritonitis. There was no palpable mass, and a negative Murphy's sign was noted. Systemic examination revealed no obvious abnormalities.

Laboratory findings, including a complete blood count, liver function tests, amylase, lipase, albumin, electrolytes, cardiac enzymes, and urine analysis, were within normal limits. An electrocardiogram showed normal sinus rhythm.

An ultrasound of the abdomen [Table/Fig-1] suggested an ovoid, slightly lobulated hyperechoic, non compressible lesion of approximately 90×70×28 mm (volume of 93 cc) with no demonstrable vascularity noted in the right subhepatic region, immediately beneath the abdominal wall and abutting the hepatic flexure of the colon inferiorly and the liver superiorly, suggestive of omental infarction.

A CT scan of the abdomen and pelvis [Table/Fig-2] with intravenous contrast revealed a large, minimally enhancing hypodensity in the omentum in the right perihepatic and subhepatic region, measuring 9×9×3.2 cm, likely representing an omental infarct or inflammation. All other internal organs appeared normal, with no free fluid or air collection.

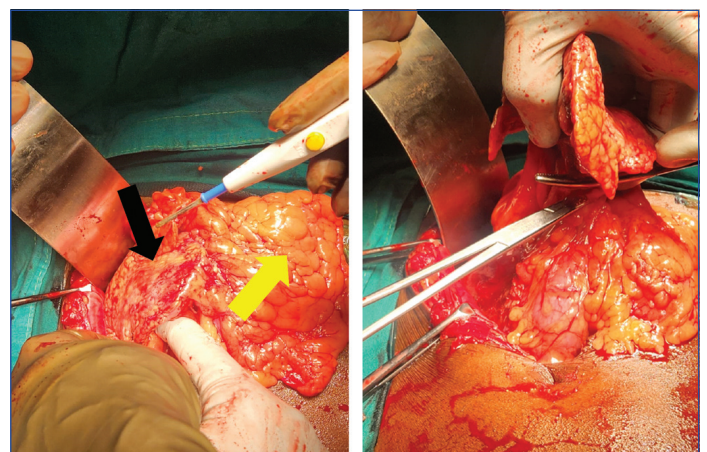
The patient was managed conservatively for 24 hours, but the pain did not subside despite intravenous antibiotics and tramadol. As a result, the patient was scheduled for an exploratory laparotomy.



[Table/Fig-1]: Ultrasound of the abdomen showing focal area of increased echogenicity of omental fat.

[Table/Fig-2]: Shows the axial view of Contrast-enhanced CT (CECT) abdomen and pelvis. The red arrow shows the area of omental inflammation. (Images from left to right)

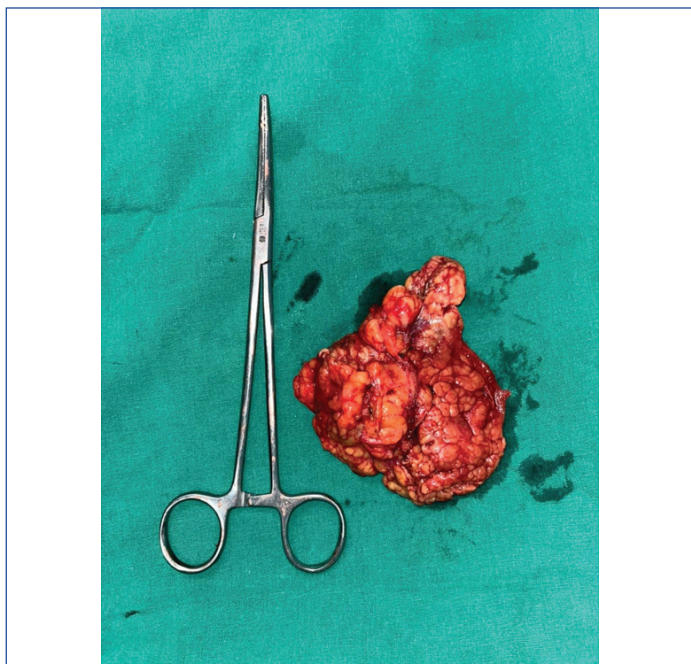
Intraoperative findings revealed congested and necrotic omental tissue attached to the abdominal wall, the inferior surface of the liver, and the hepatic flexure of the colon [Table/Fig-3]. Dissection followed by omentectomy was performed [Table/Fig-4]. The abdomen was closed in layers, and the specimen was sent for histopathology. There were no intraoperative complications.



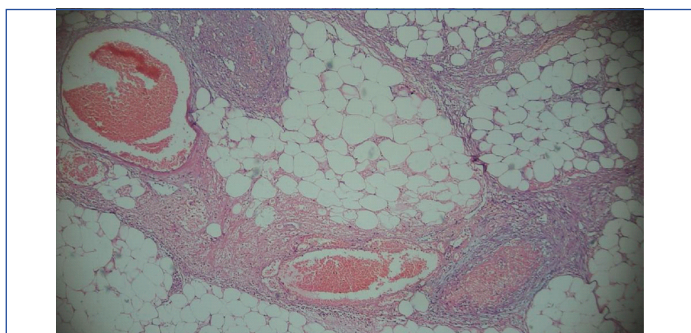
[Table/Fig-3]: Shows the intraoperative image of the demarcated dark red coloured omental infarction (black arrow) compared to the yellow coloured healthy omentum (yellow arrow).

[Table/Fig-4]: Shows the intraoperative image of the infarcted part of the omentum being dissected and excised. (Images from left to right)

The excised omental tissue measured 10.5×6.5×2 cm and appeared congested externally [Table/Fig-5]. The cut surface exhibited yellow and brown areas with evidence of haemorrhage. Microscopically, sheets of adipose tissue were separated by septa containing congested blood vessels. Necrotic areas and fibrinous exudates surrounded by inflammatory infiltrate were observed [Table/Fig-6].



[Table/Fig-5]: Shows the excised specimen of the omental tissue sent for histopathological examination.



[Table/Fig-6]: Shows the histopathological slide photo under microscopy (Haematoxylin and Eosin (H&E) Stain, 40x) demonstrating sheets of adipose tissue separated by septa containing congested blood vessels.

The postoperative recovery was uneventful, and the patient was discharged within three days. There was complete resolution of symptoms at follow-up, and over the last six months, the patient has been asymptomatic with no complaints.

DISCUSSION

Anatomically, the omentum is divided into two parts, the greater omentum and the lesser omentum [1]. The greater omentum consists of two layers of peritoneum that extend down from the greater curvature of the stomach [1]. The lesser omentum extends from the liver to the lesser curvature of the stomach [1]. The omentum contains a high concentration of tissue factor, which aids in the activation of coagulation and fibrosis at sites of trauma, inflammation, infection, and ischaemia, effectively working to limit the spread and promote tissue repair [2]. This is why the British Surgeon Rutherford Morison referred to it as the 'policeman of the abdomen' [2].

Omental infarction was first described by Eithel in 1899 [3]. A little over 250 cases of omental infarction have been identified in the literature [1]. Omental infarction has been reported in both adult and paediatric populations [4]. In most cases, there is no identifiable cause, and they are known as idiopathic primary omental infarcts [4].

Omental infarction can occur with a preceding torsion or may be due to a systemic disease such as vasculitis of omental vessels, hypercoagulability, or a thrombus causing venous outflow obstruction [5]. In the majority of cases, the aetiology of primary omental torsion is unknown and can be a result of anatomical abnormalities such as tongue-like projections of the omentum, redundant or accessory omentum, bifid omentum, irregular omental fat accumulation, a narrowed omental pedicle, or anomalous vascular supply [6]. Secondary omental torsions are associated with intra-abdominal pathology and are linked to adhesions from previous intra-abdominal surgery, increased intra-abdominal pressure, hernias, cysts, tumours, or foci of intra-abdominal inflammation [7].

It has been observed that omental infarcts more commonly occur on the right-side of the abdomen [8]. The anatomical pattern of the omental sheet, increased length, freely mobile lateral edge, and a weak blood supply contribute to making it more susceptible to twisting upon itself along its long axis and causing congestion [8]. If it twists tightly enough or the obstruction to venous flow is prolonged, arterial inflow could become compromised [6]. This could lead to an infarction and further complications such as necrosis with associated extravasation of serosanguinous ascites [5].

The differential diagnosis of omental infarction can include other intra-abdominal pathologies such as cholecystitis, ruptured ovarian cyst, appendicitis, diverticulitis, peptic ulcer disease, pancreatitis, mesenteric panniculitis, or epiploic appendagitis [9,10]. In the present case report, the diagnosis was confirmed on CT abdomen and pelvis with intravenous contrast.

There is a male to female ratio of 2:1, and the majority of cases occur in the fourth to fifth decade of life [4]. Contributing factors could include heavy exertion or sudden and forceful movements [4]. Obesity is also considered a precipitating factor due to the increased density and thickening of the omentum, which acts as a lead point [5]. Other factors include heavy food intake, hyperperistalsis, coughing, deep breathing, and local trauma [11].

Omental infarction typically presents with localised pain on the right-side of the abdomen, with no associated gastrointestinal symptoms such as nausea, vomiting, or changes in bowel habits [1]. On physical examination, there is abdominal tenderness with or without guarding [2]. Often, there is a tender palpable mass if the involved omentum is large, along with associated fever and mild leukocytosis [6].

Ultrasonography findings may include a hyperechoic, ovoid, non compressible, intra-abdominal mass attached to the abdominal wall, but it is not a sensitive investigation [4]. Therefore, radiographic evaluation is performed using a CT scan of the abdomen and pelvis, which is considered the gold standard for diagnosing omental infarction [6]. If the causative factor is omental torsion, characteristic CT findings may include a concentric distribution of fatty and fibrous linear strands converging toward the infarct, known as the 'whirl sign' [4]. This sign indicates rotation of the mesentery [9]. Fat stranding in this area will be disproportionate to any adjacent bowel wall thickening, indicating a pathological process centered within the omentum [9].

As the clinical presentation is non specific, preoperative diagnosis is often challenging [6]. The treatment depends on the severity of the patient's pain, certainty of diagnosis, and response to initial conservative measures [6].

Omental infarction can resolve spontaneously and is often managed non surgically [6]. However, one should be vigilant for the progression of infarcted omental tissue to necrosis with progressive fibrosis, which can lead to prolonged pain, fever, and an extended hospital stay [7]. It could also potentially result in abdominal abscess or adhesion formation [7]. Therefore, the appropriate initial treatment for the first 24 to 48 hours involves clinical observation and monitoring for persistent or worsening symptoms of abdominal pain, along with conservative management [12].

Surgical treatment of omental infarction involves diagnostic laparoscopy or exploratory laparotomy with excision of the infarcted omental tissue and should be reserved for those with failure of conservative management or complications such as omental abscess, bowel obstruction, adhesion formation, or in cases of an uncertain diagnosis [2].

Currently, there are no established recommendations indicating the optimal treatment approach for omental infarction. Additionally, debates arise regarding whether to pursue conservative or surgical intervention. The available literature primarily consists of case reports and series, emphasising the need for additional research to enhance understanding [11,12]. This case underscores the significance of recognising spontaneous omental infarction as a potential diagnosis, particularly in cases of acute abdominal pain on the right-side.

CONCLUSION(S)

For the presentation of acute abdominal pain, a cause like omental infarction is often missed and should be considered as a differential diagnosis. The diagnosis is challenging clinically and generally requires CT abdomen imaging to confirm the diagnosis. The management remains controversial and should be individualised, with conservative management being the first line. Exploration and excision of the infarcted omentum are needed in patients with severe pain, uncertain diagnosis, and failure to respond to initial conservative measures.

REFERENCES

- [1] Kizy S, Ikramuddin S. Abdominal Wall, Omentum, Mesentery, and Retroperitoneum. In: Brunicaudi F, Andersen DK, Billiar TR, Dunn DL, Kao LS, Hunter JG, Matthews JB, Pollock RE. eds. *Schwartz's Principles of Surgery*, 11e. McGraw-Hill Education; 2019. Available from: <https://accesssurgery.mhmedical.com/content.aspx?bookid=2576§ionid=216210029>.

- [2] Khersonsky J, Itenberg E, Mariadason J, Wallack M. Modern management of omental torsion and omental infarction: A surgeon's perspective. *J Surg Educ*. 2010;67(1):44-47. Doi: 10.1016/j.jsurg.2010.01.003. Available from: <https://pubmed.ncbi.nlm.nih.gov/20421090/>.
- [3] Russell TA, Eilber FC. Lesions of the omentum, mesentery, and retroperitoneum. In: Zinner MJ, Ashley SW, Hines O. eds. *Maingot's Abdominal Operations*, 13e. McGraw-Hill Education; 2019. Accessed March 06, 2024. Available from: <https://accesssurgery.mhmedical.com/content.aspx?bookid=2546§ionid=205733756>.
- [4] Udechukwu NS, D'Souza RS, Abdulkareem A, Shogbesan O. Computed tomography diagnosis of omental infarction presenting as an acute abdomen. *Radiol Case Rep*. 2018;13(3):583-85. Doi: 10.1016/j.radcr.2018.02.019. Available from: <https://www.sciencedirect.com/science/article/pii/S1930043317304909>.
- [5] Townsend CM, Beauchamp RD, Evers BM, Mattox KL. *Sabiston Textbook of Surgery*. 20th ed. Philadelphia, PA: Elsevier- Health Sciences Division, 2016. Pp.1095-96. Available from: <https://www.clinicalkey.com/#!/content/book/3-s2.0-B978032364062600044X>.
- [6] Aolayan K, Obaid G, Fadel K, Alotaibi AM. Omental infarction present with right upper quadrant pain, case report. *J Surg Case Rep*. 2021;2021(11):rjab521. Available from: <https://doi.org/10.1093/jscr/rjab521>.
- [7] Concannon ES, Hogan AM, Ryan RS, Khan W, Barry K. Primary omental infarction: A rare cause of acute abdominal pain. *Clinical and Experimental Medical Sciences*. 2013;1(5):233-40. Available from: <http://www.m-hikari.com/cems/cems2013/cems5-8-2013/concannonCEMS5-8-2013.pdf>.
- [8] Crofoot D. Spontaneous segmental infarction of the greater omentum. *Am J Surg*. 1980;139(2):262-64. Doi: 10.1016/0002-9610(80)90269-x. Available from: <https://pubmed.ncbi.nlm.nih.gov/7356112/#article-details>.
- [9] Pereira JM, Sirlin CB, Pinto PS, Jeffrey RB, Stella DL, Casola G. Disproportionate fat stranding: A helpful CT sign in patients with acute abdominal pain. *Radiographics*. 2004;24(3):703-15. Doi: 10.1148/rg.243035084. Available from: <https://pubmed.ncbi.nlm.nih.gov/15143223/#:~:text=Fat%20stranding%20adjacent%20to%20thickened,the%20differential%20diagnosis%20is%20wide>.
- [10] Bashir O, Sharma R, Kumar K. Omental infarction. *Radiology Reference Article, Radiopaedia.org*. 2024;1(1):01-05. Doi:10.53347/rld-17692.
- [11] Barai KP, Knight BC. Diagnosis and management of idiopathic omental infarction: A case report. *Int J Surg*. 2011;2:138-40. Doi: 10.1016/j.ijscr.2011.02.014. Available from: <https://pubmed.ncbi.nlm.nih.gov/22096707/#article-details>.
- [12] Subasinghe D, Jayasinghe R, Ranaweera G, Kodithuwakku U. Spontaneous omental infarction: A rare case of acute abdomen. *SAGE Open Medical Case Reports*. 2022;10:2050313X221135982. Doi: 10.1177/2050313X221135982.

PARTICULARS OF CONTRIBUTORS:

1. Professor, Department of General Surgery, Dr. D. Y. Patil Vidyapeeth, Pune, Maharashtra, India.
2. Resident, Department of General Surgery, Dr. D. Y. Patil Vidyapeeth, Pune, Maharashtra, India.
3. Resident, Department of General Surgery, Dr. D. Y. Patil Vidyapeeth, Pune, Maharashtra, India.

NAME, ADDRESS, E-MAIL ID OF THE CORRESPONDING AUTHOR:

Saili Kelshikar,
101, Dhanishtha, Tarangan, Thane-400606, Maharashtra, India.
E-mail: saili.kelshikar@gmail.com

AUTHOR DECLARATION:

- Financial or Other Competing Interests: None
- Was informed consent obtained from the subjects involved in the study? Yes
- For any images presented appropriate consent has been obtained from the subjects. Yes

PLAGIARISM CHECKING METHODS: [Jain H et al.]

- Plagiarism X-checker: Sep 13, 2023
- Manual Googling: Feb 29, 2024
- iThenticate Software: Mar 01, 2024 (10%)

ETYMOLOGY: Author Origin

EMENDATIONS: 6

Date of Submission: **Sep 12, 2023**
Date of Peer Review: **Nov 23, 2023**
Date of Acceptance: **Mar 06, 2024**
Date of Publishing: **May 01, 2024**