

Anomaly of Coeliaco-Mesenteric Axis: A Rare Arterial Variation

ARINDOM BANERJEE, ANIRBAN DAS GUPTA, I. ANIL KUMAR, M. PRANAY KUMAR, P. JHANSI LAXMI

ABSTRACT

While doing a routine dissection in an 85 years old cadaver, it was observed that instead of a single coeliac trunk, two trunks originated separately from the ventral aspect of the aorta, which were situated approximately 17 mm apart from each other. The proximal one which was known as the gastro splenic trunk, divided into the left gastric and the splenic arteries, whereas the distal trunk which was known as the hepato mesenteric trunk divided into the common hepatic artery and the superior

mesenteric artery. The common hepatic artery ran anterior to the portal vein. This anomalous pattern conformed to the Adachi type V, which is a very rare anomaly and it could be attributed to the developmental changes which occurred in the primitive ventral splanchnic arteries. This rare anomaly could cause a catastrophe during surgical procedures, especially laparoscopic ones, if the same was not kept in mind before contemplating pre-operative investigations. So, the reporting of such a rare case is significant.

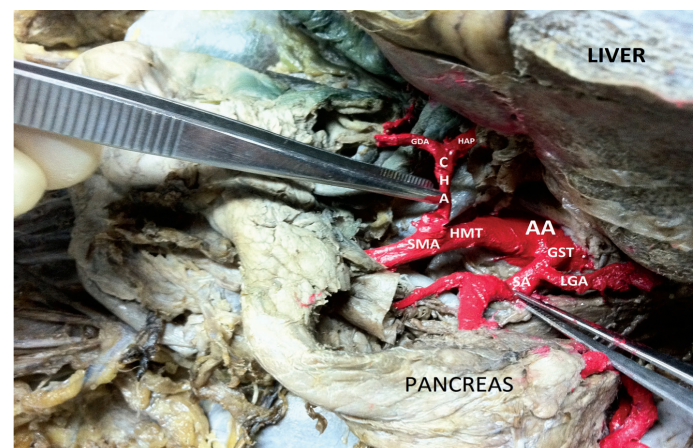
Key Words: Hepato mesenteric trunk, Coeliac artery, Gastro splenic trunk, Vascular anomaly

INTRODUCTION

The knowledge of the anomalous arterial branching patterns is essential from the view point of surgical anatomy, especially while contemplating hepatic and pancreatic surgeries. The coeliac trunk, the chief arterial supply for the foregut derivatives and one of the ventral branches of the abdominal aorta, usually gives origin to three branches, namely the splenic artery, the common hepatic artery and the left gastric artery. In antithesis, the superior mesenteric artery, yet another ventral branch of the abdominal aorta, supplies the midgut derivatives. Adachi [1], depending upon the patterns of ramification of the coeliac trunk, classified them into six types. According to Adachi's classification, when the hepatic artery and the superior mesenteric artery arise from a common stump which is named as the hepato-mesenteric artery and pass anterior to the portal vein, it is referred to the type V anomaly. In his study on 252 Japanese specimens, this anomaly was reported only in 0.4% of the cases. Hence, it is a rare anomaly and its reporting becomes very significant.

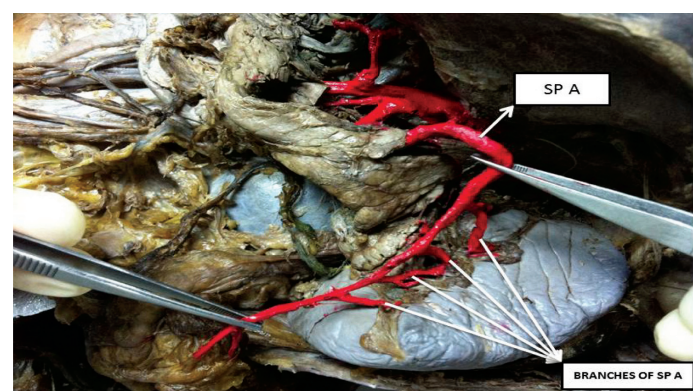
CASE REPORT

In a routine dissection of an 28-years old south Indian male, it was observed that [Table/Fig-1] two trunks arose separately from the ventral aspect of the abdominal aorta; the proximal trunk divided into the splenic artery and the left gastric artery and another trunk, approximately 17 mm distal to the previous trunk, divided into the hepatic artery and the superior mesenteric artery, namely the gastro-splenic trunk and the hepato-mesenteric trunk respectively. In our case, the gastro-splenic trunk's diameter was measured as approximately 7 mm at its origin. The splenic artery which was recognized by its tortuous and meandering course, served as a continuation of this trunk and it arose approximately 20 mm distal to the origin of the trunk. The splenic artery, as usual, gave off several branches [Table/Fig-2] to the pancreas and divided into five terminal branches before entering the hilum of the spleen.

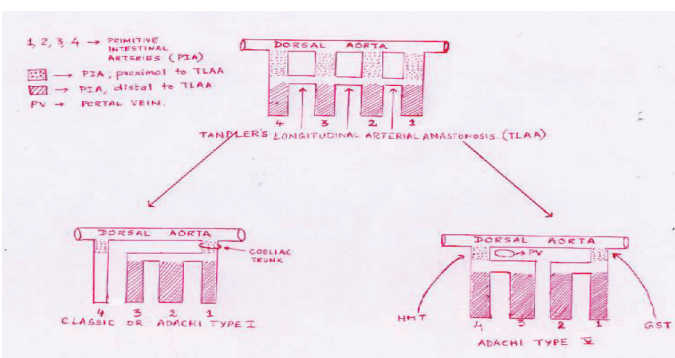


[Table/Fig-1]: View of this case showing gastrosplenic trunk & hepato mesenteric trunk arising from ventral aspect of abdominal aorta.

AA = Abdominal Aorta; GST = Gastro Splenic Trunk; LGA = Left Gastric Artery; SA = Splenic Artery; HMT = Hepato Mesenteric trunk; CHA = Common Hepatic Artery; SMA = Superior Mesenteric Artery; GDA = Gastroduodenal artery; HAP = Hepatic Artery Proper.



[Table/Fig-2]: Figure showing early division of splenic artery before its entry into hilum of the spleen



[Table/Fig-3]: Embryogenic explanation of adachi Type I & Type V classification

The left gastric artery ended by supplying the lesser curvature of the stomach. The diameter of the hepato-mesenteric trunk was approximately 9 mm and it divided into two branches at a length of approximately 20 mm distal to its origin. The common hepatic artery, after taking a supero-lateral direction, passed anterior to the portal vein and after ascending for roughly 30 mm, gave off the gastro duodenal artery and itself continued as the hepatic artery proper. The rest of the course and the branches of the hepatic artery proper were normal.

DISCUSSION

These coeliac trunk and the mesenteric artery anomalies were embryologically explained by Tandler [2], Morita [3], Sato [4] and Wustinger [5]. Morita and Sato did their study on human adults, whereas Tandler did it on human embryos and Wustinger did it on sheep. While Morita cited the disappearance of the roots of the primitive ventral splanchnic arteries and their anastomoses as the reasons for this type of anomaly, Sato cited mid gut rotation with a consequential disappearance and the persistence of various anastomoses between the arteries of the right, middle and left liver rudiments as an explanation towards these type of coeliac-mesenteric variations. Our case fitted well into Morita's hypothesis [Table/Fig-3]. Disappearance of the proximal part of the 2nd and 3rd roots and the longitudinal anastomosis between them led to the formation of the gastro-splenic trunk and its branches (formed by the entire 1st root, the distal part of the 2nd root and the anastomosis between them) and the hepato-mesenteric trunk and its branches (formed by the entire 4th root, the distal part of the 3rd root and the anastomosis between them). Subsequently, the distal part of the 1st root formed the left gastric artery, the distal part of the 2nd root formed the splenic artery, the distal part of the 3rd root formed the common hepatic artery and the distal part of the 4th root formed the superior mesenteric artery. The proximal part of the 1st root and the 4th root formed the gastro-splenic trunk and the hepato-mesenteric trunk respectively.

Many previous studies have been done, based on Adachi's classification. According to those reports, Adachi type V was found in 0.4% of 252 specimens by Adachi, in 1.9% of 107 specimens by Imakoshi [6], in 2.0% of 450 specimens by Shoumura [7] and in 0.7% of 275 specimens by Sato. A study on the coeliac artery and the superior mesenteric artery has also been done by Morita, Katsume [8], Saga [9], Kitamura [10], Kajiwara [11], Yamaki [12], Higasi [13], Tamura [14], Akira Imura [15] and Horiguchi [16] and Yoichi Nkamura [17].

With the advances in the surgical techniques, increased concern for the post-operative cosmetic appearance and the advent of still

newer horizons of treatment like laparoscopic operations, surgeons may not have the opportunity of seeing the entire surgical operative area, which necessitates well planned pre-operative investigations and an appropriate knowledge of the possible anomalies of that particular region. This will avoid or at least reduce the risk of inadvertently damaging the blood vessels, thereby preventing the conversion of a life saving operation to a life threatening one. Moreover, the knowledge on the hepatic arterial vascularization and its variations has a significant relevance in the daily practice because the classical arterial anatomy is seen only in 55-77% of the population [18, 19]. Keeping these facts in view, the reporting of such a rare anomaly stands very significant.

REFERENCES

- [1] Adachi B. A Coeliaca Arteriensystem der Japaner. Bd. II Verlag Der Kaiserlich-Japanischen. *Universitant zu Kyoto* 1928; 18-71.
- [2] Tandler J. Uber die Varietaten der Arteria coeliaca and deren Entwicklung. *Anat Heft* 1094; 25:473-500.
- [3] Morita M. Reports and conception of three anomalous cases of the coeliac and the superior mesenteric arteries. *Igaku Kenkyu* 1935; 9:1993-2006.
- [4] Sato Y, Takeuchi R, Kawashuma T, et al. On the branches of the coeliac trunk. *J Kyorin Med Soc* 1993; 24:75-92.
- [5] Wustinger J. Developmental anomaly of the hepatic artery in sheep. *Folia Morphol (Warsz)* 1978; 37:99-102.
- [6] Imakoshi K. Study of the coeliac artery. Studies from the Anatomical Department of the Kanazawa Medical College 1949; 37:1-14.
- [7] Shomura S, Emura S, et al. An anatomical study on the branches of the coeliac trunk (IV); comparison of our findings with Adachi's classification. *Acta Anat Nippon* 1988; 66:452-61.
- [8] Katsume Y, Kanamaru E, Sakai K, et al. The statistical report about thirteen anomalous cases on the branches of the coeliac trunk. *J Kur M A* 1978; 41:266-73.
- [9] Saga T, Hirao T, Kitashima S, et al. An anomalous case of the left gastric artery, the splenic artery and the hepato-mesenteric trunk independently arising from the abdominal aorta. *Kurme Medical Journal* 2005; 52:49-52.
- [10] Kitamura S, Nakamura T, Yoshioka T, et al. A case of the common hepatic artery arising from the superior mesenteric artery. *Acta Anat Nippon* 1980; 55:280.
- [11] Kajiwara A, Kimura A, et al. A case of the hepatic artery arising from the superior mesenteric artery. *J Showa Med Asso* 2005; 65(3): 254-58.
- [12] Yamaki K, Kastume Y, Ohtsuka K, Momota K, Miyazaki M. An anomalous case of truncus coeliaco-mesentericus. *Acta Anat Nippon* 1984; 59:648.
- [13] Higashi N, Hirai K. On the hepatic artery arising from the superior mesenteric artery. *Acta Anat Nippon* 1995; 70:338-46.
- [14] Tamura K, Kitazawa M, Itonaga T, Oioishi H, et al. Four anomalous cases of the splenic artery with an abnormal origin. *Acta Anat Nippon* 1986; 61:130-37.
- [15] Imura A, Oguchi T, Shibata M, Takahashi T. An anomalous case of the hepatic artery arising from the superior mesenteric artery. *Okajimas Folia Anat. Jpn.* 2007; 84(2):61-66.
- [16] Horiguchi M, Koizumi M, Isogai S. Two cases of absence of the common hepatic artery. *Acta Anat Nippon* 1988; 63:557-63.
- [17] Nkamura Y, Miyaki T, Hayashi S, Imura A, Itoh M. Three cases of the gastrosplenic and the hepatomesenteric trunks. *Okajimas Folia Anatomica Japonica* 2003; 80(4): 71-76.
- [18] Bertevello P, Chaib E. Hepatic artery system variations correlated to split liver surgery: anatomic study in cadavers. *Arq Gastroenterol* 2002; 39(2): 81-5.
- [19] Makisalo H, Chaib E, Krokos N, Calne RY. Hepatic arterial variations and liver related diseases of 100 consecutive donors. *Transpl Int* 1993; 6(6):325-9.

AUTHOR(S):

1. Dr. Arindom Banerjee
2. Dr. Anirban Das Gupta
3. Dr. I. Anil Kumar
4. Dr. M. Pranay Kumar
5. Dr. P. Jhansi Laxmi

PARTICULARS OF CONTRIBUTORS:

1. Corresponding Author,
2. Anatomy, Assistant professor,
3. Anatomy, Assistant professor,
4. Anatomy, Tutor,
5. Anatomy, Tutor.

NAME OF DEPARTMENT(S)/INSTITUTION(S) TO WHICH THE WORK IS ATTRIBUTED:

Konaseema Institute of Medical Sciences & Research Foundation (KIMS), Amalapuram, Andhra-pradesh, India.

NAME, ADDRESS, E-MAIL ID OF THE CORRESPONDING AUTHOR:

Dr. Arindom Banerjee (MD Anatomy)
Assistant professor, Department of Anatomy,
Konasemma Institute of Medical Sciences & Research
Foundation (KIMS),
Amalapuram, Andhra Pradesh - 533201, India.
Phone: 09966275513
E-mail: arindondoc@yahoo.co.in

FINANCIAL OR OTHER COMPETING INTERESTS:

None.

Date Of Submission: **Jan 07, 2012**

Date Of Peer Review: **Jan 19, 2012**

Date Of Acceptance: **Jan 20, 2012**

Date Of Publishing: **Apr 15, 2012**