

Bilateral Papillo-oedema in a Paediatric Patient with a Cerebro-Renal Disorder

DEEPA MUZUMDAR, NEELAM PUTHRAN, VARSHA KULKARNI

ABSTRACT

A 7-year-old boy, a known case of Polycystic Kidney Disease since birth, presented with an acute onset of headache and blurring of vision, and was discovered to have systemic hypertension of 140/110 mm Hg. Further examination revealed the presence of grade IV hypertensive retinopathy in both the eyes. MRI of the brain revealed diffuse cerebellar and cortical atrophy with a prominent ventricular system, which was

indicative of a variant of the Dandy Walker Syndrome. Although there was initial improvement in the vision following the control of the blood pressure, the patient developed bilateral optic atrophy shortly thereafter. This case report highlights the occurrence of papillo-oedema with visual impairment in a cerebro renal disorder and also the importance of ophthalmic screening in paediatric patients.

Key Words: Polycystic Kidney, Dandy-Walker Variant, Papillo-oedema, Visual impairment

INTRODUCTION

Hypertensive retinopathy is rarely seen in pre-pubertal children who suffer from systemic hypertension. However, in the event of malignant hypertension, children can develop vision threatening ocular complications. This is a case report of visual loss which occurred in a child with the rare combination of Polycystic Kidney Disease, a Dandy – Walker variant and severe systemic hypertension.

CASE REPORT

A 7-year-old boy with Polycystic Kidney Disease (PKD) which was diagnosed in utero, developed a sudden blurring of vision and mild headache. He was found to have severe systemic hypertension and was referred to our institution for the same.

The patient was asymptomatic since birth and had normal developmental milestones with a normal IQ. His clinical examination revealed a macrocephaly of 56 cms and a blood pressure of 140/110 mm Hg. His systemic examination showed no other significant findings.

His ocular examination revealed a normal head posture, with orthophoria. His ocular movements were normal in all the directions of gaze. His visual acuity was counting fingers at a distance of three metres in each eye, and his colour vision was normal. His pupillary reactions to direct and consensual light were brisk and equal. His anterior segment examination did not reveal any other abnormality.

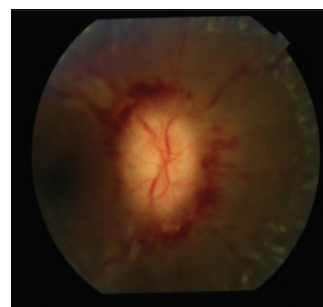
The posterior segment examination of both the eyes revealed Grade 3 papillo-oedema, and an altered A:V ratio with numerous superficial haemorrhages at the posterior pole. Few hard exudates and an early fan formation were noted in the left macular region. Cotton wool spots were conspicuous by their absence [Table/Fig-1 & 2]. A diagnosis of Grade IV hypertensive retinopathy was made. His Visual Evoked Potentials (VEP) showed a delayed latency in P100. Automated perimetry was not done as the child was unable to cooperate.

MRI of the brain showed diffuse cortical and cerebellar atrophy, with a prominent Sylvian fissure and enlargement of the ventricular system. There were prominent cystic spaces in the posterior fossa, with hypoplasia of the cerebellar vermis. There were no signs of cerebral oedema in the MRI [Table/Fig-3, 4 & 5]. The electroencephalogram findings were indicative of a generalized cerebral disorder.

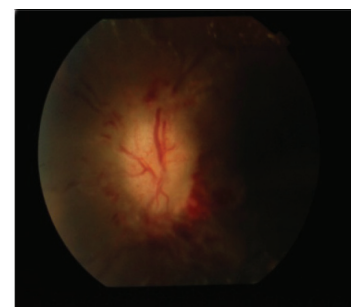
The patient's mother was also discovered to have polycystic kidneys. She was asymptomatic, with a normal blood pressure.

The patient was managed with titrated doses of intravenous sodium nitroprusside and oral amlodipin 5mg twice daily. There was a marked improvement in the vision to 6/18 in both eyes by the fourth day after the control of the blood pressure, although the fundus findings remained unchanged.

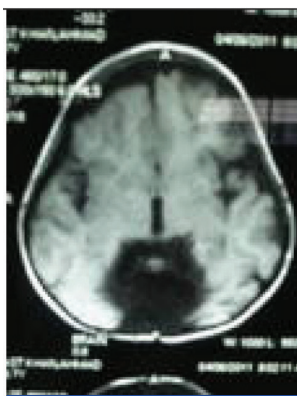The patient did not report for follow up until three months later. His systemic hypertension remained under control. However, his vision was found to have deteriorated to 6/60 in the right eye and to counting fingers at 3 metres in the left eye. His colour vision for red was also found to be impaired. Fundoscopy revealed that all the haemorrhages and exudates had cleared, but both the optic discs showed partial optic atrophy changes [Table/Fig-6 & 7].



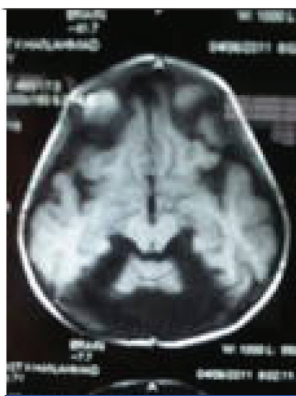
[Table/Fig-1]: Rt Eye Papilloedema



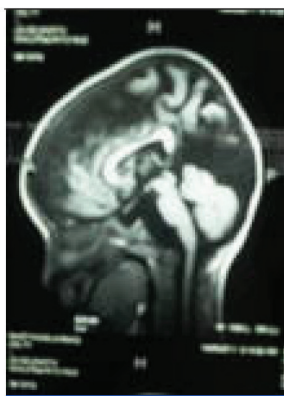[Table/Fig-2]: Lt Eye Papilloedema



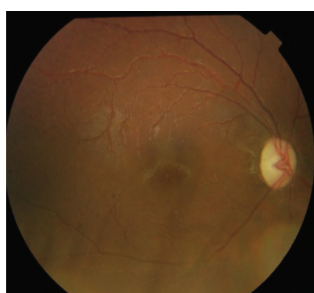[Table/Fig-3]: MRI brain showing diffuse cortical and cerebellar atrophy



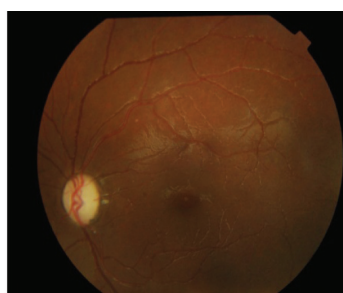
[Table/Fig-4]: MRI brain showing cerebellar atrophy and effacement in posterior fossa



[Table/Fig-5]: MRI brain showing cystic lesion in posterior fossa



[Table/Fig-6]: Optic atrophy, right eye



[Table/Fig-7]: Optic atrophy, left eye

DISCUSSION

Polycystic Kidney Disease (PKD) is a relatively common hereditary disorder [1, 2]. Although genetic testing could not be done in our case, the presence of PKD in the mother favoured an inherited genetic aetiology.

Hypertension is commonly seen in Polycystic Kidney Disease [1, 3]. Hypertension does not produce significant fundus changes in paediatric patients [4], but malignant hypertension may show hypertensive retinopathy and/or an ischaemic optic neuropathy [2, 3]. Although the occurrence of malignant hypertension with fundus changes may be seen in some cases of pheochromocytoma, paraganglioma and other nephropathies [5,6,7], the same has not been reported in polycystic renal disease. Children with malignant hypertension may present with symptoms such as headache, double vision, and blurred vision. Our patient had developed systemic hypertension by the young age of seven years and he presented with headache and blurred vision. He was detected to have grade IV hypertensive retinopathy with grade 3 papilloedema in both the eyes.

Papillo-oedema may also occur in patients with the Syndrome Dandy Walker (SDW), which is a rare genetic disorder with a sporadic inheritance [8]. The characteristic radiological picture shows hypoplasia of the cerebellar vermis, cystic dilatation of the ventricular spaces and a posterior fossa cyst [9]. The MRI of our patient confirmed the presence of an SDW variant. The clinical features of the syndrome include a moderate delay in the psychomotor development, macrocephaly, hypotonia and ataxia [10]. While our patient did have mild macrocephaly, his developmental milestones, intelligence and central nervous system were normal.

The predominant symptoms and signs in SDW are generally due to the hydrocephalus and they include seizures, vomiting, abducens

nerve palsy and papillo-oedema [10]. Other ocular abnormalities are rarely seen and we found only a single report in the literature on multiple ocular malformations in a case of Dandy Walker malformation [8]. Other than hypertensive retinopathy, papillo-oedema and vision loss, there were no other ocular findings in our case.

Vision impairment is generally not a feature of papillo-oedema, except when it is chronic and after early optic atrophy has set in. This patient did not show any signs of chronic papillo-oedema. Macular oedema could have accounted for the accompanying vision loss, but it was present only in one eye. The presence of

bilateral optic nerve ischaemia, as indicated by the studies on the visual evoked potentials (VEP), was likely to have been the result of the combination of both the hypertension induced ischaemic optic neuropathy as well as the Dandy Walker syndrome induced internal hydrocephalus. This could account for the bilateral visual loss. Control of the systemic hypertension has been reported to result in visual improvement; while recurrences of visual loss tend to occur with poor control [11]. Repeated attacks are liable to lead to serious blinding complications in children [11,12]. It has recently been suggested that the retinal examination need not be used as a screening tool for the evidence of the target organ damage in children with hypertension [4]. However, our case indicated that retinal examination must be included in the screening protocol to save the children from permanent visual loss.

In some cases of the Dandy Walker Syndrome, visual improvement had resulted, following the placement of a peritoneal shunt for the hydrocephalus [9]. Our patient showed a good initial response to the anti hypertension treatment alone. However, three months later, although there was regression of the retinopathy, the optic nerve was found to have progressed to optic atrophy.

CONCLUSION

We, therefore, summarise that the combination of the hydrocephalus from the Dandy Walker Syndrome and the grade IV hypertensive retinopathy due to malignant hypertension, which was secondary to the polycystic kidney disorder, together resulted in the bilateral papillo-oedema, while the visual loss was secondary to an ischaemic optic neuropathy.

Obvious hypertension and signs of ischaemic damage to the optic nerve should prompt the urgent management of hypertension to prevent permanent visual damage.

REFERENCES

- Patricia A, Gabow N. Autosomal dominant polycystic kidney disease. *Engl J Med* 1993; 329:332-42.
- Kliegman R, Behrman R, Jenson HB. Polycystic Kidney Disease. In: *Nelson's Textbook of Paediatrics* (vol 2) 18th edition, New Delhi, Saunder's Elsevier; 2008;2185-86.
- Chapman AB, Stepniakowski K, Rahbari-Oskoui F. Hypertension in autosomal dominant polycystic kidney disease. *Adv Chronic Kidney Dis* March 2010;17(2):153-63.
- Foster BJ, Ali H, Mamber S, Polomeno RC, Mackie AS. The prevalence and severity of hypertensive retinopathy in children. *Clin Pediatr (Phila)* Nov 2009;48(9):926-30.
- Venkatesh P, Garg S.P., Verma L, Tewari. A decreased vision-presenting feature in paraganglioma. *Indian Pediatrics* 2002; 39:681-84.

- [6] Chen TY, Liang CD, Shieh CS, Ko SF, Kao ML. Reversible hypertensive retinopathy in a child with bilateral pheochromocytoma after tumor resection. *J Formos Med Assoc* 2000; 99: 945-47.
- [7] Guyomard JL, Jacob H, Roche O, Pierre-Kahn V, Charlin JF. An atypical case of malignant hypertensive retinopathy in a young child. *J Fr Ophthalmol* Jan 2004;27(1):57-62.
- [8] Ewald O, Scremin F, Busch F, Von Hertwig R. Ocular alterations in a pediatric patient with Dandy-Walker malformations: case report. *Arq. Bras. Oftalmol* Jan/Feb. 2006;.69 (1): 97-99.
- [9] Gluson, Dohnys, Plavner, Ashwal. Dandy Walker Syndrome. In; *Paediatric Neurology-Principles and Practice*, 4th edition, Philadelphia, Mosby Elseiver;1984;391.
- [10] Fenichel GM, ed. Dandy Walker Syndrome. In; *Clinical Paediatric Neurology-Signs and Symptoms Approach*, 4nd edition, Philadelphia, WB Saunders; 1993; 366.
- [11] Logan P, Eustace P, Robinson R. Hypertensive retinopathy: a cause of the decreased visual acuity in children. *J Paediatr Ophthalmol Strabismus*. Sep-Oct 1992; 29(5):287-89.
- [12] Taylor D, Ramsay J, Day S, Dillon M. Infarction of the optic nerve head in children with accelerated hypertension. *British Journal of Ophthalmology* 1981; 65: 153-60.

AUTHOR(S):

1. Dr. Deepa Muzumdar
2. Dr. Neelam Puthran
3. Dr. Varsha Kulkarni

PARTICULARS OF CONTRIBUTORS:

1. (Corresponding Author), Associate Professor,
2. Professor & Head,
3. Professor.

NAME OF DEPARTMENT(S)/INSTITUTION(S) TO WHICH THE WORK IS ATTRIBUTED:

Department of Ophthalmology
Bharati Vidyapeeth Deemed University Medical College
Pune, Maharashtra, India.

NAME, ADDRESS, E-MAIL ID OF THE CORRESPONDING AUTHOR:

Dr. Deepa Muzumdar
F-5 Sankul, Erandawane, Pune - 411004, India.
Phone: 9890294951
E-mail: deepa.muzumdar@gmail.com

FINANCIAL OR OTHER COMPETING INTERESTS:

None.

Date of Submission: **Aug 22, 2011**
Date of peer review: **Oct 17, 2011**
Date of acceptance: **Dec 22, 2011**
Date of Publishing: **Apr 15, 2012**