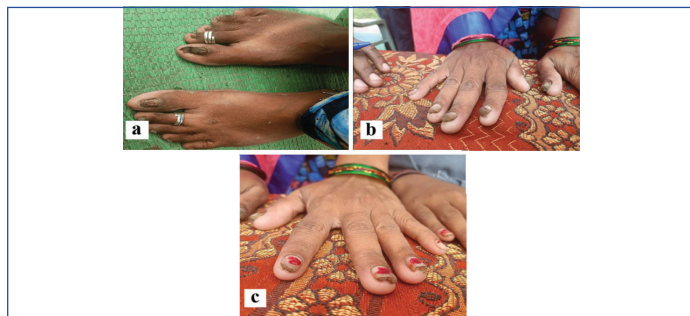


A Rare Case of Pachyonychia Congenita in Mother and Daughter

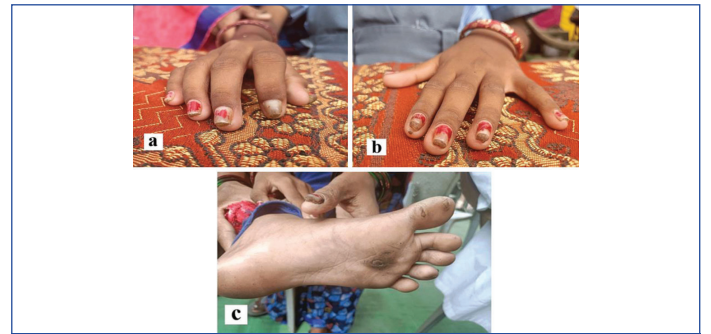
MAYURI DESHPANDE¹, AMOL DESHPANDE²
Keywords: Keratinising skin disorder, Leukoplakia, Palmoplantar keratoderma

Pachyonychia Congenita (PC) is a rare genetic disorder characterised by excessive keratinisation of the skin, nails, and mucous membranes, leading to thickened nail beds and skin on pressure points, notably on the soles of the feet. A 10-year-old girl came to the Outpatient Department (OPD) with her 38-year-old mother. Both of them had same complaints regarding their nails and callous formation over soles. They both had thickened nail plates with thickened pressure points on sole [Table/Fig-1a-c,2a-c]. In PC, oral manifestations are found but on the day of visit they didn't have any lesion in mouth. Both of them had difficulty and pricking sensation during walking. Both of them had anorexia due to the heinous presentation of the nails. They had taken lots of medicines for the conditions of nails but of no use. Other family members were not affected. Dyskeratosis congenita, pterygium inversum unguis, and onycholysis can be differential diagnosis. The final diagnosis is PC type I. In [Table/Fig-1a-c,2a,b], onychodystrophy can be seen clearly. In [Table/Fig-2c], plantar keratoderma can be seen, which are the cardinal features for the diagnosis of PC.



[Table/Fig-1]: Growth under nails in mother's feet, right hand and left hand.

The PC is a rare genetic condition present from birth, characterised by excessive keratinisation of the skin, nails, and mucous membranes. It follows an autosomal dominant inheritance pattern and is also referred to as palmoplantar keratoderma. Individuals with PC typically exhibit thickened nail beds, often forming tent-shaped structures. Additionally, there is thickening of the skin at pressure points on the soles of the feet, leading to discomfort and difficulty walking. Leukoplakia, or white patches, may also develop on the tongue [1]. It is challenging to determine PC prevalence with accuracy due to its rarity. A total of 774 people with genetically proven PC have been found in 419 households according to the International PC research registry. PC



[Table/Fig-2]: Growth under nails in daughter's right hand, left hand and foot.

encompasses five subtypes, each associated with mutations in specific keratin genes: KRT6A, KRT6B, KRT6C, KRT16, or KRT17 [2]. These mutations disrupt the normal function of keratin proteins, leading to the characteristic symptoms of the disorder. PC is a rare autosomal dominant genetic disease. Munro CS has given mutation and presentation of PC in his article titled PC: mutations and clinical presentations [3]. Injections of Botox are among the several PC treatments that concentrate on pain control. Case studies involving small groups of patients have been the only proof of research on treating the underlying problem, which involves things like lowering keratin allele expression. Self-management of symptoms becomes the norm for the majority of patients [4].

As per Goldberg et al., in their Best Treatment Practices for PC, mechanical and surgical methods are favoured over medication therapy, as none of the currently available therapeutic alternatives for PC are perfect, despite offering some relief. The need for more effective and focused therapy is highlighted by these results [5].

REFERENCES

- [1] Feinstein A, Friedman J, Schewach-Millet M. Pachyonychia congenita. *J Am Acad Dermatol.* 1988;19(4):705-11.
- [2] Smith FJ, Liao H, Cassidy AJ, Stewart A, Hamill KJ, Wood P, et al. The genetic basis of pachyonychia congenita. *J Invest Dermatol Symp Proc.* 2005;10(1):21-30.
- [3] Munro CS. Pachyonychia congenita: Mutations and clinical presentations. *Br J Dermatol.* 2001;144(5):929-30.
- [4] Wu AG, Lipner SR. Distinctions in the management, patient impact, and clinical profiles of pachyonychia congenita subtypes. *Skin Appendage Disord.* 2021;7(3):194-202.
- [5] Goldberg I, Fruchter D, Meilick A, Schwartz ME, Sprecher E. Best treatment practices for pachyonychia congenita. *J Eur Acad Dermatol Venereol.* 2014;28(3):279-85.

PARTICULARS OF CONTRIBUTORS:

1. Assistant Professor, Department of Kayachikitsa, Mahatma Gandhi Ayurved College and Research Centre, Datta Meghe Institute of Higher Education and Research, Wardha, Maharashtra, India.
2. Associate Professor, Department of Sharir Rachana, Mahatma Gandhi Ayurved College and Research Centre, Datta Meghe Institute of Higher Education and Research, Wardha, Maharashtra, India.

NAME, ADDRESS, E-MAIL ID OF THE CORRESPONDING AUTHOR:

Mayuri Deshpande,
Tukaram Ward, Near Circus Ground, Ramnagar, Wardha-442001, Maharashtra, India.
E-mail: mayuribawane12@gmail.com

AUTHOR DECLARATION:

- Financial or Other Competing Interests: None
- Was informed consent obtained from the subjects involved in the study? No
- For any images presented appropriate consent has been obtained from the subjects. Yes

PLAGIARISM CHECKING METHODS: [Jain H et al.]

- Plagiarism X-checker: Apr 08, 2024
- Manual Googling: Apr 27, 2024
- iThenticate Software: May 03, 2024 (9%)

ETYMOLOGY: Author Origin

EMENDATIONS: 6

Date of Submission: **Apr 06, 2024**

Date of Peer Review: **Apr 25, 2024**

Date of Acceptance: **May 06, 2024**

Date of Publishing: **Jun 01, 2024**