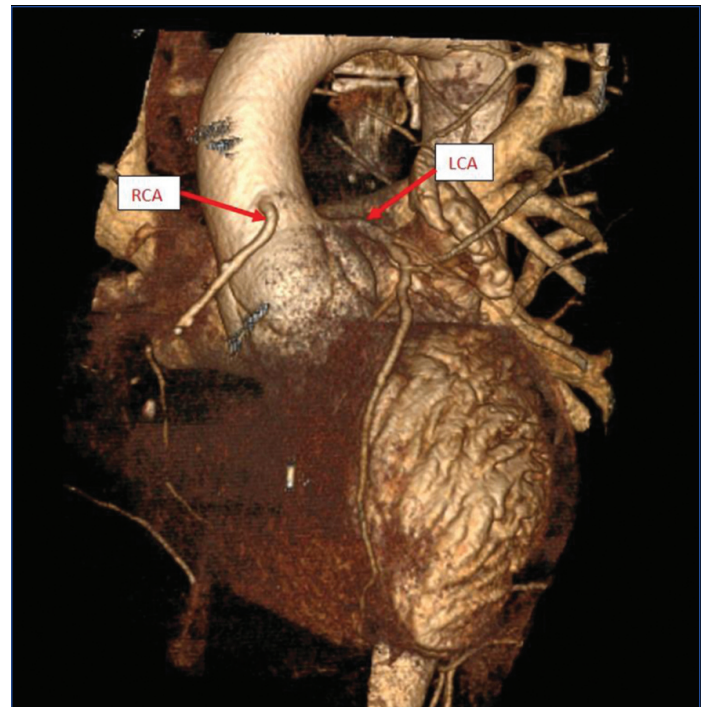


# Anomalous Origin of Right Coronary Artery from Ascending Aorta: MDCT Coronary Angiography Depiction Images

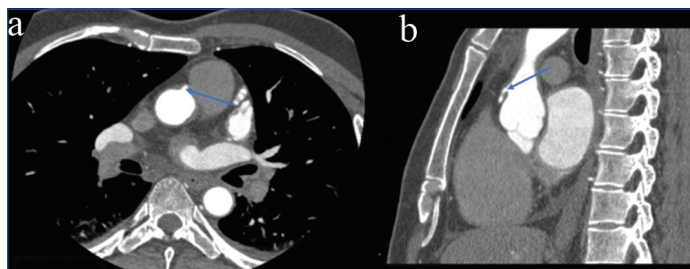
SIDDHARDHA KOMMURI<sup>1</sup>, KONDAMPALLY VARSHA REDDY<sup>2</sup>, N YESHWANTH RAJU<sup>3</sup>, SENTHIL KUMAR AIYAPPAN<sup>4</sup>

**Keywords:** Coronary artery disease, Dyspnoea, Myocardial ischaemia

A 46-year-old male presented with complaints of chest pain and dyspnoea on moderate exertion for the past month. The patient was a known case of type 2 diabetes mellitus and hypertension, and has been on treatment for the past five years. He was not a smoker or alcoholic. Suspecting coronary artery disease, a diagnostic work-up was performed. Blood investigations revealed dyslipidaemia. Electrocardiography (ECG) showed sinus rhythm with a limited right bundle branch block with ST-T changes. Echocardiogram showed biventricular dysfunction. Since the patient was reluctant to undergo catheter coronary angiography, a Computed Tomography (CT) Coronary angiogram was performed first. A 128-slice Multidetector Computed Tomography (MDCT) coronary angiography revealed an anomalous high origin of the Right Coronary Artery (RCA) arising from the anterior wall of the ascending aorta approximately 2 cm above the sinotubular junction at an acute angle of 45° [Table/Fig-1,2] [Video-1]. The anomalous RCA followed its normal course without any intramural course noted. Mixed plaques were observed in the RCA, with involvement distal to the acute marginal artery, causing a maximum of 90% stenosis or complete occlusion. The Left Coronary Artery (LCA) was found to be normal, arising from the left cusp of the coronary sinus and dividing into the left anterior descending artery and left circumflex artery. The left anterior descending artery showed significant stenosis in its proximal third. The left circumflex artery exhibited minimal coronary artery disease with no significant stenosis. Therefore, double-vessel coronary artery disease was diagnosed, and the patient was advised to undergo a revascularisation procedure. Currently, the patient is on medication and undergoing follow-up.



**[Table/Fig-2]:** A 3-dimensional volume rendering technique CT image showing anomalous origin of the Right Coronary Artery (RCA) from the wall of ascending aorta above sinotubular junction and normal Left Coronary Artery (LCA) origin (red arrows).



**[Table/Fig-1]:** a) Axial; and b) Sagittal MDCT coronary angiography images showing acute angle origin of the Right Coronary Artery (RCA) from the anterior wall of ascending aorta above sinotubular junction (blue arrows).

The anomalous origin of the RCA was first described by White and Edwards in 1948 [1]. The incidence of an anomalous RCA varies from 0.026 to 0.25% [1]. Patients with an anomalous origin of the RCA can be asymptomatic or may present with angina, myocardial ischaemia, or sudden cardiac death [1,2]. Possible causes can include narrow ostia, a malignant course leading to its compression between the aorta and pulmonary

artery, or spasm due to compression in its malignant course. In index case, the patient's symptoms were due to coronary artery disease and not an anomalous RCA. Anomalous RCA origin from the ascending aorta is an extremely rare anomaly comprising only 0.04 to 0.15% of all reported anomalies [3]. In a case reported by Ramirez Damera R et al., there was an anomalous origin of the RCA from the ascending aorta above the left sinus of Valsalva; however, in index case, it arose from the anterior wall of the ascending aorta above the sinotubular junction [3]. In a recent case reported by Mutluoglu M et al., the anomalous RCA had a high origin from the ascending thoracic aorta above the sinotubular junction, similar to index case [4]. Cannulation of the anomalous RCA can be difficult and requires extra effort during catheter coronary angiogram. If found incidentally and asymptomatic, only careful follow-up is recommended.

## REFERENCES

- [1] Ho JS, Strickman NE. Anomalous origin of the right coronary artery from the left coronary sinus: Case report and literature review. *Tex Heart Inst J.* 2002;29(1):37-39. PMID: 11995848; PMCID: PMC101267.
- [2] Rizzo S, De Gaspari M, Frescura C, Padalino M, Thiene G, Basso C. Sudden death and coronary artery anomalies. *Front Cardiovasc Med.* 2021;8:636589. Doi: 10.3389/fcvm.2021.636589. PMID: 33869302; PMCID: PMC8044928.

[3] Ramirez Damera R, Khan MI, Khine KT, Katukuri N. Anomalous origin of the right coronary artery from the ascending aorta above the left sinus of valsalva. Cureus. 2021;13(3):e13845. Doi: 10.7759/cureus.13845. PMID: 33854856; PMCID: PMC8038423.

[4] Mutluoglu M, Gryspeerdt S, De Smet K. Anomalous origin of the right coronary artery from the ascending aorta. Rev Port Cardiol. 2024;43(1):51-52. English, Portuguese. Doi: 10.1016/j.repc.2023.04.009. Epub 2023 Jun 21. PMID: 37353196.

**PARTICULARS OF CONTRIBUTORS:**

1. Junior Resident, Department of Radiodiagnosis, SRM Medical College Hospital and Research Centre, Kattankulathur, SRM Institute of Science and Technology, Chengalpattu, Tamil Nadu, India.
2. Junior Resident, Department of Radiodiagnosis, SRM Medical College Hospital and Research Centre, Kattankulathur, SRM Institute of Science and Technology, Chengalpattu, Tamil Nadu, India.
3. Junior Resident, Department of Radiodiagnosis, SRM Medical College Hospital and Research Centre, Kattankulathur, SRM Institute of Science and Technology, Chengalpattu, Tamil Nadu, India.
4. Professor and Head, Department of Radiodiagnosis, SRM Medical College Hospital and Research Centre, Kattankulathur, SRM Institute of Science and Technology, Chengalpattu, Tamil Nadu, India.

**NAME, ADDRESS, E-MAIL ID OF THE CORRESPONDING AUTHOR:**

Dr. Senthil Kumar Aiyappan,  
Professor and Head, Department of Radiodiagnosis, SRM Medical College Hospital  
and Research Centre, Chengalpattu-603203, Tamil Nadu, India.  
E-mail: asenthilkumarpgi@gmail.com

**PLAGIARISM CHECKING METHODS:** [Jain H et al.]

- Plagiarism X-checker: Feb 13, 2024
- Manual Googling: Apr 25, 2024
- iThenticate Software: May 02, 2024 (12%)

**ETYMOLOGY:** Author Origin**EMENDATIONS:** 6**AUTHOR DECLARATION:**

- Financial or Other Competing Interests: None
- Was informed consent obtained from the subjects involved in the study? Yes
- For any images presented appropriate consent has been obtained from the subjects. Yes

Date of Submission: **Feb 13, 2024**Date of Peer Review: **Apr 22, 2024**Date of Acceptance: **May 03, 2024**Date of Publishing: **Aug 01, 2024**