

# High Bifurcation of the Common Carotid Artery and Looping of the External Carotid Artery – a Case Report

D. VINAITHA, K. SUBA ANANDHI, R. SHARMILA SARAN, LAKSHMI RAMANATHAN, ARUNA SUBRAMANIAM

## ABSTRACT

During the routine dissection of the anterior triangle of the neck in a 65-year old female cadaver at Chettinad Hospital and Research centre, a bilateral high bifurcation of the common carotid artery and looping of the external carotid artery on the left side was observed. A high bifurcation of the common carotid arteries on both sides above the level of the angle of the

mandible was found. The 'S' shaped loop of the external carotid artery was observed on the left side. The branching pattern of the external carotid artery was normal on the right side, but on the left side, the superior thyroid artery was found to arise from the common carotid artery

**Key Words:** Bifurcation, common carotid, Looping, External carotid artery, Kinking

## INTRODUCTION

Common carotid arteries (CCA) are large arterial vessels of head and neck surgery, which are important landmarks which define the plane of dissection during radical neck surgery [1]. Conventional angiography is considered as the most accurate technique for the diagnosis of carotid bifurcation diseases such as stenosis[2]. Variations in the origin and branching of the external carotid artery are well known and they have been documented. As already has been discussed by Susan Standing [3], the common carotid artery of both the sides diverges laterally behind the sterno-clavicular joint to the level of the upper border of the thyroid cartilage of the larynx (C3-4 junction), where it divides into the external and the internal carotid arteries and the external carotid artery runs within the substance of the parotid gland and behind the neck of the mandible. It divides into two terminal branches, the superficial temporal and the maxillary arteries. These variations are of importance for surgical approaches in the head and neck region [4]. Coiling (or looping) of an artery is a rare morphological entity, which has been most frequently described in the internal carotid artery as a single cause of cerebrovascular insufficiency or in combination with carotid atherosclerosis [5 -8]. The term "Dolicho-arteriopathies" has been applied to the coiling, kinking, and the tortuosity of the carotid arteries [9]. The incidence of coiling and kinking of the internal carotid artery has been estimated to be from 10% to 16% in the general population. Its respective clinical significance still remains the ground of controversy [10].

## CASE REPORT

The variations in the level of bifurcation of the common carotid artery and in the branching pattern of the external carotid artery was seen during the routine dissection of the anterior triangle of the neck in a 65-year old female cadaver in the Department of Anatomy, Chettinad Hospital and Research Institute. The common carotid artery bilaterally bifurcated above the level of the angle of the mandible. The course and the branching pattern of the external

carotid artery were normal on the right side. The left superior thyroid artery arose from the common carotid artery, 1.8 cm below the carotid bifurcation and its other branches and the course of the external carotid artery were normal on the left side. The left external carotid artery, at its commencement, formed an 'S' shaped looping, which is a characteristic feature that was noticed [Table/Fig 1].

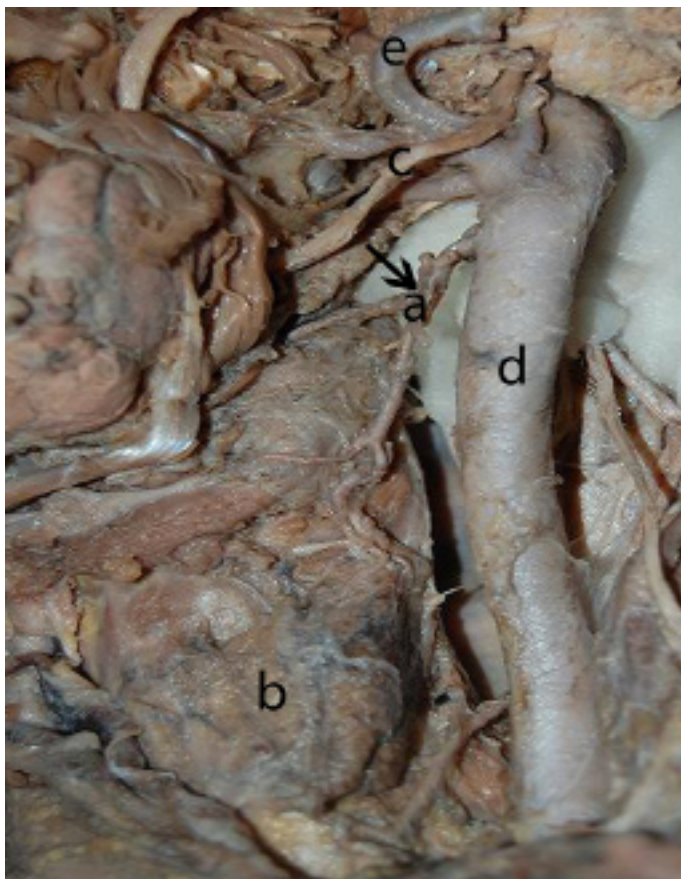
## DISCUSSION

The common carotid artery bifurcates commonly at the level of the upper border of the thyroid cartilage, as has been described in the standard text books of anatomy [11,12].The lower division of the common carotid artery has been recorded to be as frequent as 30% [11,12].

The common carotid artery has no significant branches, but it may give rise to the vertebral artery, the superior thyroid artery, laryngeal branches or ascending pharyngeal arteries [12].The origin of the superior thyroid artery from the common carotid artery has been previously reported by many authors [13,14].The origin of the superior thyroid artery from the common carotid artery was found only in 5% of the cases among the Swiss and in 45% cases among the Americans [11].Recent reports have also stated the same to be 30% and 52.3% [15,16]. The hypoglossal nerve was closer in relation to the common carotid artery bifurcation [15]. In this present case also, the superior thyroid artery originated from the common carotid artery on the left side while the hypoglossal nerve lay on the origin of the external carotid artery [Table/Fig 1]. On the right side, the superior thyroid artery originated from the external carotid artery. Other branches of the external carotid artery from both the sides were normal.

The mode of classification of the variations of the internal carotid artery can also be applied to classify the variations in the external carotid artery [17].

The frequency of the common carotid bifurcation at the C3 and C3-4 vertebrae was 38.8% and 22.5%. Terminations which were



**[Table/Fig-1]:** 'S' shaped Looping of External Carotid artery. a-Superior thyroid artery, b- Thyroid gland, c- Hypoglossal Nerve, d- CCA, e- Looping of External carotid artery.

Variations Observed	Incidence
<b>A. CCA Bifurcation</b> 1. Lower Division of CCA	30%[11'121]
<b>B. Variation in Origin of Superior thyroid artery</b> 1. Origin of Superior thyroid artery from CCA 2. Origin of Superior thyroid artery from CCA	30%[15] 52.3%[16]
<b>C. Vertebral Levels of CCA Bifurcation</b> 1. C3 2. C3-4 3. C3 4. C2 5. C3	38.8%[18] 22.5%[18] Right side - 50%, Left side -55%[18] 12.5%[18]

**[Table/Fig-2]:** Variations Observed bifurcation of the common carotid

higher than the C3/C3-4 levels were found in 25% of the vessels. The higher bifurcation was at the level of C2 in 12.5% of the cases [18] and the bifurcation at the level of C3 was 50% on the right side and 55% on the left side [19] respectively. A study on human foetuses showed the maximum CCA bifurcation at the level of C3 in 60% of cases on the left side and in 55% on the right side. A high division of CCA on both the sides 1cm above the greater cornu of the hyoid bone and 2 cm above the superior border of the lamina of the thyroid cartilage was reported [20,21]. There was a report that the common carotid bifurcation was noted bilaterally at the level of C2 [22]. The present case also showed the bilateral higher bifurcation of the common carotid, but it was above the angle of the mandible (C2), that is 3.6cm above the superior border of the thyroid cartilage.

The third aortic arches are the precursors of the carotid system.

It forms the CCA and the cranial segment of the ICA. The caudal segment of the ICA is formed by the dorsal aorta and the external carotid artery sprouts from the third aortic arch [23]. The embryological reason for the kinking of the external carotid artery may be the descent of the heart and the incomplete straightening of the vessels during the shifting of the origin from the aortic sac to the third aortic arch.

The 'S' shaped looping on the left side was observed at the level of origin of the external carotid artery [24]. Variations like elongations, tortuosity, coiling, kinking or looping may be congenital. The kinking may be associated with arteriosclerosis, stenosis, vasculitis, atrophic dilation, loss of elasticity and dissection in the context of fibro muscular dysplasia [25]. The carotid coils occur conversely in adults and most frequently in the elderly, in whom atherosclerosis is also frequently seen. The coiling of the external carotid artery may be acquired from the excessive elongation of the artery with age, and the elongated artery may have thinning of the media and fragmentation of the elastic lamina [7].

## CONCLUSION

Knowledge of the vascular anatomy is essential for the interpretation of diagnostic and interventional vascular procedures. When there is a need for a more accurate interpretation in radiological examinations during precutaneous carotid angiography, external anatomical landmarks turn out to be useful. Radiologists should take these variations into consideration. Looping may be associated with degenerative changes in the vessel wall and it may predispose to atherosclerotic stenosis. The hypoglossal nerve lies closer to the CCA bifurcation, which is more vulnerable.

## ACKNOWLEDGEMENT:

There is no grant support. We thank the Chettinad hospital and research institute for permitting us to carry out this study.

## REFERENCES

- Ord RA, Ward -Booth RP. Anomalies of the common carotid artery: A rare complication of radical neck dissection. *Brit. J. Oral Max .Surg.* 1986; 24(6): 405 - 9.
- Schwartz RB, Jones KM, Chernoff DM, Mukherji SK, Khorasani R, Tice H M, Kikini S.R, Stieg P.E, Polak VJ.F. Common carotid bifurcation: Artery evaluation with spiral CT. *Radiology.* 1992; 185(2): 513 - 9.
- Standing S. Vascular Supply and Lymphatic drainage . In: Susan standing, London UK, Gray's Anatomy, The Anatomical basis of clinical practice. 40 th; Elsevier; 2008.
- Poynter CWN, University of Nebraska. Congenital anomalies of the arteries and veins of the human body with bibliography. Lincoln: *The University Studies of the University of Nebraska.* 1992; 22: 1-106.
- Paulsen F, Tillmann B, Christofidesc, et al. Curving and looping of the internal carotid artery in relation to the pharynx: frequency, *embryology and clinical implications.* *J Anat.* 2000; 197(3):373-81
- Daskalakis MK. Coiling of the carotid arteries. *South Med J.* 1987; 80 (3):387-9.
- Milic D, Jankovic R. Coiling of the left common carotid artery as a cause of transient ischemic attacks. *Journal of Vascular Surgery.* 2007; 45(2): 411-3
- Ilijevski NS, Jagodic S, Sagic D, Rada KD. Coiling of the brachial artery: An uncommon cause of difficult thrombectomy. *Vascular.* 2005 Jul-Aug; 13(4): 248-51.
- Pellegrino L, Prencipe G, Vairo F. [Dolicho-arteriopathies (Kinking, Coiling, Tortuosity) of the Carotid arteries: Study by color Doppler Ultrasonography]. *Minerva Cardioangiol.* 1998 Mar; 46(3): 69-76.
- Poulias GE, Skoutas B, Doundoulakis N, Haddad H, Karkanas G, Lyberiadis D. Kinking and coiling of the internal carotid artery with and without associated stenosis. Surgical considerations and long-term follow-up. 1996 Mar; 38(1): 22-7.
- Henry HW. In: *Anatomy for Surgeons.* HoeberHarper, New York . 1958; 1: 458-62.
- Williams SPL, Warwick R, Dyson M, Bannister LM. *Angiology in: Gray's*

- Anatomy. 37th ed, Churchill Living stone. Edinburg. 1989; 678-85.
- [13] Smith SD, Benton RS. A rare origin of the superior thyroid artery. *Acta Anat (Basel)*. 1978; 101(1): 91-3
- [14] Avadhani R, Chelvakumaran TS. An abnormally high bifurcation of the common carotid artery. *Anatomical Adjuncts*. 1995; Vol.2: 29-33.
- [15] Lo A, Oehley M, Bartlett A, Adams D, Blyth P, Al-Alis. Anatomical variations of the common carotid artery bifurcation. *ANZ J Surg*. 2006 Nov; 76(11): 970-2.
- [16] Hayashi N, Hori E, Ohtani O, Kuwayama N, Endo S. Surgical anatomy of the cervical carotid artery for carotid endarterectomy. *Neurol Med Chir (Tokyo)*. 2005 Jan; 45(1): 25-9.
- [17] Weibel J, Fields WS. Tortuosity, coiling and kinking of the internal carotid artery. *Neurology*. 1965; 15:17-18, II 462-68.
- [18] Anangwe D, Saidi H, Ogeng'O J, Awori KO. Anatomical variations of the carotid arteries in adult Kenyans. *East African Medical Journal*. 2008 May; 85(5): 244-47.
- [19] Thwin SS, Soe MM, Myint M, Than M, Lwin S. Variations in the origin and the branches of external carotid artery in a human cadaver. *Singapore Med J*. 2010; 51(2): 40 – 42.
- [20] Kishve PS, Kishve SP, Joshi M, Syed MMA, Kalakoti P. An unusual branching pattern of the common and external carotid arteries in a human cadaver-A case report. *AMJ*. 2011; 4, 4:180-82.
- [21] Mamatha T, Rajalakshmirai, Prabhu LV, Hadimani G A, Jiji P J, Prameela MD. Anomalous branching pattern of the external carotid artery; A case report. *Romanian Journal of Morphology and Embryology*. 2010; 51(3): 593-95
- [22] Anu VR, Pai MM, Rajalakshmi R, Latha V P, Rajanigandha V, D'Costa. Clinically-relevant variations of the carotid arterial system. *Singapore Med J*. 2007; 48(6): 566.
- [23] Cakirer S, Karaarslan E, Kayabali M, Rozanes I. Separate origins of the left internal and external carotid arteries from the aortic arch: *MR angiographic findings*. *AJNR*. 2002; 23: 1600-2.
- [24] Cairney J. Tortuosity of the cervical segment of the internal carotid artery. *Journal of Anatomy*. 1924; 59(1): 87-96.
- [25] Schenk P, Temmel A, Trattning S, Kainberger F. Aktuelle Aspekte in der Diagnostik und Therapie des karotiskinking. *Hals-Nasen-Ohrenheilkunde. Kopf- und Hals-Chirurgie*. 1996; 44:178-185

**AUTHOR(S):**

1. Dr. D.Vinaitha.
2. Dr. K.Suba Anandhi.
3. Dr. R.Sharmila Saran.
4. Dr. Ramanathan Lakshmi.
5. Dr. Aruna Subramaniam.

**PARTICULARS OF CONTRIBUTORS:**

1. Corresponding Author.
2. Department of Anatomy.
3. Department of Anatomy.
4. Department of Anatomy.
5. Department of Anatomy.

**Institution to which the study is Attributed to:**

Chettinad Hospital and Research Institute,  
Chettinad University, Kelambakkam, Tamil Nadu -603103, India

**NAME, ADDRESS, TELEPHONE, E-MAIL ID OF THE CORRESPONDING AUTHOR:**

Dr. D.Vinaitha,  
Department of Anatomy,  
Chettinad, Hospital And Research Institute,  
Chettinad, University, Kelambakkam, Tamil Nadu-603103, India.  
E-mail: vinay\_anatomy@yahoo.co.in  
Phone : +919962069025

**DECLARATION ON COMPETING INTERESTS:**

No competing Interests.

Date of Submission: **Jun 10, 2011**

Date of peer review: **Aug 22, 2011**

Date of acceptance: **Aug 22, 2011**

Date of Publishing: **May 01, 2012**