

# A Case of Orbital Cellulitis with an Underlying Intraconal Tumour: An Unlikely Co-existence

ANURADHA SINGH<sup>1</sup>, SHAILESH MOGRA<sup>2</sup>, VISHAL CHAUDHARY<sup>3</sup>, DEEPTI SINGH<sup>4</sup>

## ABSTRACT

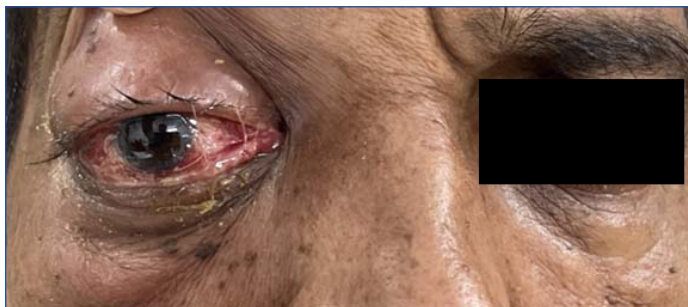Orbital cellulitis is an acute onset, rapidly progressive and potentially sight-threatening disease of the eye. It is more prevalent in developing regions and low socio-economic strata and may be associated with a host of other systemic diseases, such as paranasal sinus or dental infections, diabetes mellitus, urinary tract infections and sepsis. Often, orbital cellulitis is associated with an orbital or periosteal abscess, which can be diagnosed with orbital imaging and may sometimes require drainage to relieve the pressure. A 63-year-old male patient presented with orbital cellulitis of the right eye. The patient did not reveal any focus of infection upon investigation. Orbital imaging revealed a well-defined intraconal tumour with contrast enhancement, abutting but not involving the optic nerve, likely a cavernous haemangioma. The patient was admitted and managed with parenteral antibiotics, showing an excellent response to treatment. Given that the clinical signs did not support a benign tumour, repeat imaging was performed and again favoured a cavernous haemangioma. Presently, the patient is asymptomatic with slight proptosis and is under observation. This is an uncommon and interesting presentation of proptosis with a hyperacute cause superimposed on a more chronic lesion.

**Keywords:** Haemangioma, Imaging, Proptosis

## CASE REPORT

A 63-year-old male presented to the Accident and Emergency department with sudden onset of painful, profound diminution of vision in the right eye, associated with redness and forward bulging of the eyeball. The onset occurred two days prior to presentation and was rapidly progressive. The patient had no known co-morbidities; however, he reported a history of fever with chills 3-4 days before the onset of symptoms. There were no other complaints.

Upon initial evaluation, visual acuity was Counting Fingers (CF) at two feet in the right eye and 6/9 unaided in the left eye. The right eye demonstrated proptosis (24 mm on the Hertel exophthalmometer on the right-side, compared to 21 mm on the left-side), along with lid oedema, conjunctival congestion and chemosis [Table/Fig-1]. Ocular movements were significantly reduced in all directions of gaze and there was resistance to retropulsion. Anterior segment evaluation revealed a clear cornea, normal anterior chamber and an early cataract. The pupillary reaction was normal, as was the fundus examination. The left eye also revealed an early cataract and was otherwise normal.



**[Table/Fig-1]:** Patient photo at presentation, showing significant proptosis with lid oedema, conjunctival congestion and chemosis.

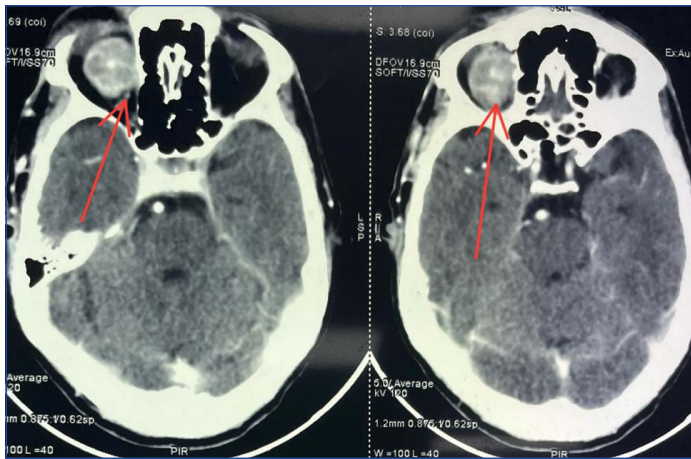
Based on the characteristic clinical features of the patient, the most probable diagnosis was orbital cellulitis of the right eye. Other differential diagnoses considered included Carotid-Cavernous Fistula (CCF), orbital varix, thyroid eye disease, idiopathic orbital inflammation and orbital tumours such as cavernous haemangioma. However, the sudden onset of vision loss with pain, proptosis and

signs of inflammation, along with a preceding history of fever in a diabetic patient, strongly suggested the diagnosis of orbital cellulitis, which was managed as an ophthalmic emergency.

The patient was admitted to the acute surgical ward under ophthalmology. Blood samples were sent for initial investigations, fever work-up and sepsis screen. The patient was promptly started on Injection Teicoplanin 400 mg BD for the first day, followed by 200 mg BD from the second day onward and Injection Meropenem 1 g BD. Other medications used concurrently included injectable analgesics (paracetamol), pantoprazole, oral Chymoral Forte, Vitamin C and topical antibiotics (moxifloxacin) and lubricants (carboxymethylcellulose). Investigations revealed a raised neutrophil percentage (81%) in an otherwise normal leukocyte count ( $11.0 \times 10^3/\mu\text{L}$ ), raised C-Reactive Protein (CRP, 72.5 mg/L) and Erythrocyte Sedimentation Rate (ESR, 82 mm fall in 1<sup>st</sup> hour). Blood sugar levels and Glycated Haemoglobin (HbA1C) were normal (78 mg/dL fasting, 99 mg/dL postprandial, HbA1C 6.1%). Urine examination was normal. An examination of the paranasal sinuses, including a Computed Tomography (CT) scan, was normal.

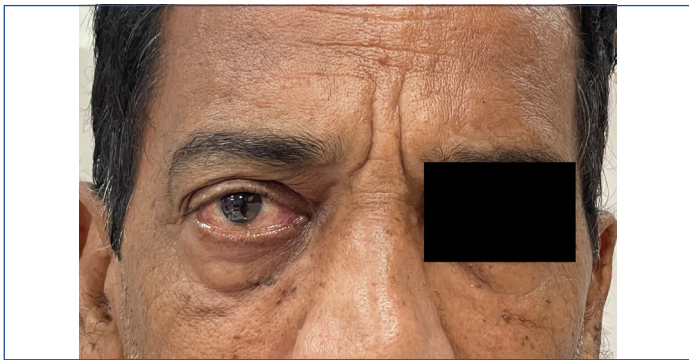
Blood cultures conducted for Staphylococcal spp., *Streptococcus* spp., *Haemophilus influenzae*, mucormycosis and anaerobic bacteria were reported negative. The thyroid profile was normal (TSH 2.2 mIU/L). The patient underwent orbital imaging the next day, as it was prudent to start treatment immediately and not delay treatment while waiting for imaging. An initial Contrast Enhanced CT (CECT) scan of the brain, orbits and paranasal sinuses revealed a well-defined, rounded, hyperdense, heterogeneously enhancing space-occupying lesion in the intraconal space of the right orbit, abutting the optic nerve and superior rectus muscle. There was no involvement of the optic canal, paranasal sinuses, or intracranial extension [Table/Fig-2].

The treatment was continued for 14 days and the patient started showing significant improvement from the second day onwards. The patient was reviewed twice daily to assess inflammation and optic nerve involvement. The patient's vision gradually improved to 6/9 in the right eye. Ocular movements improved significantly, along with a complete resolution of conjunctival chemosis and

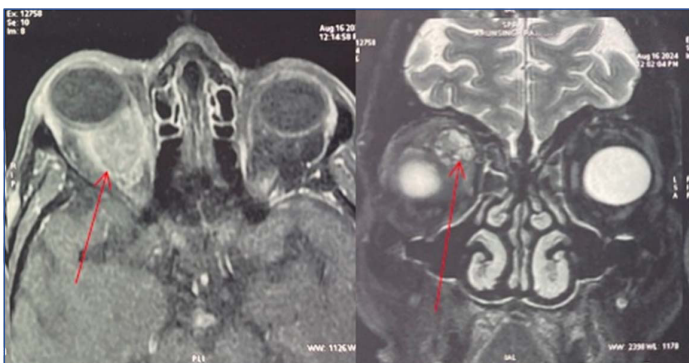


**[Table/Fig-2]:** Axial scans of initial CECT of the patient. Left image shows a well-defined intraconal tumour (arrow) in right orbit with no intracranial extension and clear paranasal sinuses. Right image showing a well-defined lesion (arrow) with no periosteal abscess. The size of the lesion was documented as 15x20x17 mm.

congestion [Table/Fig-3]. A subsequent Contrast Enhanced Magnetic Resonance Imaging (CEMRI) revealed a well-defined, smoothly margined, intraconal soft-tissue lesion adjacent to the superior rectus muscle and cranial to the right optic disc, with peripheral heterogeneous enhancement and a small enhancing central nodular area, favouring the diagnosis of cavernous haemangioma [Table/Fig-4].



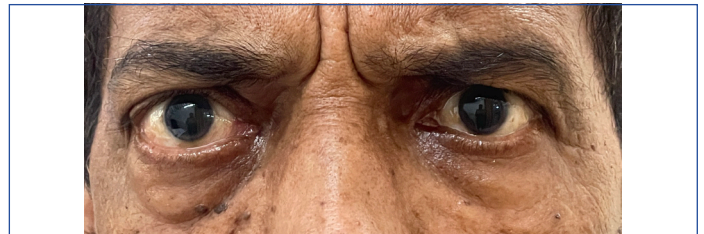**[Table/Fig-3]:** Photograph showing reduction in proptosis, congestion and chemosis.



**[Table/Fig-4]:** CEMRI showing a well-defined intraconal lesion in right orbit likely to be cavernous hemangioma. Left image showing an axial scan with lesion (arrow) without involvement of paranasal sinuses. Right image showing a coronal scan with well-defined lesion on the superomedial aspect (arrow). No involvement of the brain or paranasal sinuses is seen.

The patient was discharged after 14 days of hospitalisation on oral antibiotics and supportive treatment. At discharge, the patient's visual acuity was 6/9 unaided in both eyes, improving to 6/6 with -1.0 DC at 100° in the right eye and -0.75 DC at 80° in the left eye. There was mild proptosis (22 mm) of the right eye with inferior dystopia; ocular movements were full and free [Table/Fig-5]. Based on the presentation, clinical features, laboratory findings and radiological investigations, the final diagnosis for the patient was orbital cellulitis with a co-existing intraorbital tumour. Some differential diagnoses for such a lesion with the clinical presentation

described above include cavernous haemangioma, haematoma, low-flow vascular malformation, inflammatory pseudotumor, or abscess. The possibility of an abscess or pseudotumour was ruled out due to the well-defined, ring-enhancing lesion with heterogeneous enhancement. The absence of a prominent superior ophthalmic vein or diffuse enlargement of extraocular muscles reduced the likelihood of a direct or indirect CCF, although these features may only be visible in a direct shunt. A CT/MR angiogram is essential to differentiate between cavernous haemangioma and an indirect shunt; however, this was withheld considering the need for emergent control of cellulitis for this patient.



**[Table/Fig-5]:** Photograph at discharge showing a mild proptosis and complete resolution of orbital cellulitis.

The patient showed an excellent response to treatment, with a small degree of residual proptosis, free ocular movements and no involvement of the optic nerve. The decision not to undertake a biopsy for the orbital haemangioma was made due to the added risk of orbital haemorrhage. An active management approach for the orbital tumour was also not pursued because of the patient's good visual acuity and sparing of the optic nerve. Currently, the patient is on follow-up in the Outpatient Department (OPD). This case is being reported with the informed consent of the patient.

## DISCUSSION

Orbital cellulitis can affect individuals of any age group, though it is more common in paediatric patients [1]. It is generally associated with ongoing infections elsewhere in the body, such as dental infections or surgeries, paranasal sinus infections, especially involving the ethmoid sinus, septicaemia, urinary tract infections and upper respiratory tract infections, particularly in children. It can also be related to systemic co-morbidities such as diabetes mellitus and other causes of immune suppression [1].

The condition is primarily caused by gram-positive bacteria such as *Staphylococcus aureus*, *Streptococcus pyogenes* and *Haemophilus influenzae*, although gram negative bacteria, anaerobes and polymicrobial infections are also observed in clinical settings, especially with the increasing age of the patient [2].

Orbital cellulitis classically presents with a painful decrease in visual acuity, along with proptosis, lid oedema and erythema, conjunctival congestion and chemosis and restricted ocular movement. A relative afferent pupillary defect may be seen in cases of optic nerve involvement. There is a risk of permanent vision loss due to complications such as optic nerve involvement, central retinal artery occlusion and exposure keratopathy. Intracranial extension of the infection can cause cavernous sinus thrombosis, brain abscess, meningitis/encephalitis, leading to subsequent complications and even a risk to life. Septicaemia can be both a cause and an effect of orbital cellulitis [1,3].

Needless to say, the disease requires an aggressive approach to treatment. The patient requires admission and treatment with parenteral antibiotics, preferably a broad-spectrum combination covering both gram-positive and gram negative organisms [4]. A thorough evaluation to identify the source of infection must be carried out. Frequent reviews of the patient should be conducted to check for optic nerve involvement.

The role of radiology is to ascertain the extent of the infection, intracranial extension, the status of the paranasal sinuses and to

rule out a periosteal or intraorbital abscess. CT scans and MRI are the investigations of choice. An ultrasound-guided drainage of such an abscess, if present, may need to be performed to relieve pressure and reduce the infection load while identifying the organism involved. However, treatment should not be delayed while waiting for culture and antibiotic sensitivity reports [5]. The role of corticosteroids remains controversial [6].

Present case patient presented clinically as a classical case of orbital cellulitis of the right eye. However, radiological findings revealed a peculiar intraconal lesion suggestive of cavernous haemangioma. A repeat imaging study after the resolution of orbital cellulitis confirmed the same diagnosis. During the literature review, a few cases of acute presentations of orbital cavernous haemangioma due to intralesional haemorrhage and thrombosis were found [7,8]. Index patient was a classical case of orbital cellulitis with a co-existing cavernous haemangioma who responded well to parenteral antibiotics. No other similar cases were reported in the literature.

Cavernous haemangioma is the most common benign orbital tumour in adults [9]. The lesion often remains asymptomatic for a long time and a mild proptosis may go unnoticed by the patient. The most common clinical presentation is painless proptosis, followed by visual disturbances due to optic nerve involvement [10]. CT scans and MRI are the preferred radiological investigations [11]. The tumour can be observed in cases that are small and spare the optic nerve; however, surgical excision through an anatomically preferred route should be performed in cases of compressive optic neuropathy, severe extraocular movement restriction, or disfigurement [10]. The tumour can be approached through anterior or lateral orbitotomy or an endoscopic transnasal approach, depending on the site and size of the tumour. Other less preferred treatment modalities include stereotactic radiotherapy, sclerotherapy and intralesional pteryngamycin [10].

## CONCLUSION(S)

The diagnosis of orbital cellulitis is made clinically and is supported by laboratory and radiological investigations. The significant proptosis caused by orbital cellulitis can make it difficult to suspect any concurrent lesions. The purpose of radiology in such cases is

to rule out an abscess, either periosteal or orbital. The co-existence of a cavernous haemangioma in a patient with orbital cellulitis is a very uncommon finding. Such patients should be aggressively managed for orbital cellulitis and thereafter, management for cavernous haemangioma should be undertaken based on the clinical progression of the disease.

## REFERENCES

- [1] Yadalla D, Jayagayathri R, Padmanaban K, Ramasamy R, Rammohan R, Nisar SP, et al. Bacterial orbital cellulitis - A review. *Indian J Ophthalmol.* 2023;71(7):2687-93. Doi: 10.4103/IJO.IJO\_3283\_22. PMID: 37417106; PMCID: PMC10491050.
- [2] Ambati BK, Ambati J, Azar N, Stratton L, Schmidt EV. Periorbital and orbital cellulitis before and after the advent of *Haemophilus influenzae* type B vaccination. *Ophthalmology.* 2000;107(8):1450-53. Doi: 10.1016/s0161-6420(00)00178-0. PMID: 10919886.
- [3] Chaudhry IA, Al-Rashed W, Arat YO. The hot orbit: Orbital cellulitis. *Middle East Afr J Ophthalmol.* 2012;19(1):34-42. Doi: 10.4103/0974-9233.92114. PMID: 22346113; PMCID: PMC3277022.
- [4] Aryasit O, Aunruan S, Sanghan N. Predictors of surgical intervention and visual outcome in bacterial orbital cellulitis. *Medicine (Baltimore).* 2021;100(25):e26166. Doi: 10.1097/MD.00000000000026166. PMID: 34160383; PMCID: PMC8238295.
- [5] Jiramongkolchai P, Lander DP, Kallogjeri D, Olsen MA, Keller M, Schneider JS, et al. Trend of surgery for orbital cellulitis: An analysis of state inpatient databases. *Laryngoscope.* 2020;130(3):567-74. Doi: 10.1002/lary.28050. Epub 2019 May 3. PMID: 31050824; PMCID: PMC6825874.
- [6] Kornelsen E, Mahant S, Parkin P, Ren LY, Reginald YA, Shah SS, et al. Corticosteroids for periorbital and orbital cellulitis. *Cochrane Database Syst Rev.* 2021;4(4):CD013535. Doi: 10.1002/14651858.CD013535.pub2. PMID: 33908631; PMCID: PMC8092453.
- [7] Louisraj S, Ponnudurai T, Rodriguez D, Thomas PA, Nelson Jesudasan CA. Cavernous hemangioma of the orbit: An unusual acute presentation. *Int Med Case Rep J.* 2017;10:255-59. Doi: 10.2147/IMCRJ.S133284. PMID: 28769595; PMCID: PMC5533564.
- [8] Singh A, Panyala R, Irfan KSA, Samanta R, Kumar B. An unusual presentation of retrobulbar cavernous hemangioma in a young woman. *Cureus.* 2021;13(8):e17508. Doi: 10.7759/cureus.17508. PMID: 34603884; PMCID: PMC8476192.
- [9] Pacheco Callirgos G, Valentin Bravo FJ, Panadero Meseguer P, Asensio Sánchez VM. Unusual extraconal orbital location of a cavernous hemangioma. *GMS Ophthalmol Cases.* 2022;12:Doc17. Doi: 10.3205/oc000204. PMID: 35912125; PMCID: PMC9285109.
- [10] Low CM, Stokken JK. Typical orbital pathologies: Hemangioma. *J Neurol Surg B Skull Base.* 2021;82(1):20-26. Doi: 10.1055/s-0040-1722633. Epub 2021 Jan 19. PMID: 33777617; PMCID: PMC7987401.
- [11] Hentati A, Matar N, Dridi H, Bouali S, Jemel H. Bilateral orbital cavernous hemangioma. *Asian J Neurosurg.* 2018;13(4):1222-24. Doi: 10.4103/ajns.AJNS\_96\_17. PMID: 30459900; PMCID: PMC6208225.

### PARTICULARS OF CONTRIBUTORS:

1. Assistant Professor, Department of Ophthalmology, Military Hospital, Ahmedabad, Gujarat, India.
2. Assistant Professor, Department of Ophthalmology, Military Hospital, Ahmedabad, Gujarat, India.
3. Assistant Professor, Department of Radiology, Military Hospital, Ahmedabad, Gujarat, India.
4. Medical Officer, Department of Accident and Emergency, Military Hospital, Ahmedabad, Gujarat, India.

### NAME, ADDRESS, E-MAIL ID OF THE CORRESPONDING AUTHOR:

Dr. Anuradha Singh,  
Assistant Professor, Department of Ophthalmology, Military Hospital, Cantonment,  
Shahibaug, Ahmedabad-380004, Gujarat, India.  
E-mail: anuradha9000@gmail.com

### AUTHOR DECLARATION:

- Financial or Other Competing Interests: None
- Was informed consent obtained from the subjects involved in the study? Yes
- For any images presented appropriate consent has been obtained from the subjects. Yes

### PLAGIARISM CHECKING METHODS: [Jain H et al.]

- Plagiarism X-checker: Aug 26, 2024
- Manual Googling: Oct 10, 2024
- iThenticate Software: Oct 19, 2024 (6%)

### ETYMOLOGY: Author Origin

### EMENDATIONS: 6

Date of Submission: **Aug 25, 2024**

Date of Peer Review: **Sep 24, 2024**

Date of Acceptance: **Oct 24, 2024**

Date of Publishing: **Dec 01, 2024**