

Patient-centered Outcomes in Modern Endodontic Microsurgery: A Narrative Review

HAYTHAM JAHA



ABSTRACT

Endodontic Microsurgery (EMS), a minimally invasive approach to root canal treatment, has seen a notable increase in popularity due to its potential for enhanced outcomes. The present review seeks to evaluate the current state of Patient-Centered Outcomes (PCOs) in contemporary EMS, focusing on comparative analyses of surgical techniques, adjunctive therapies and the influence of technological advancements. The literature was examined to assess the effectiveness of various microsurgical techniques, including lasers, ultrasonic instrumentation and specialised irrigation solutions. Furthermore, the role of adjunctive therapies, such as regenerative techniques and antimicrobial agents, in improving treatment outcomes has been discussed. The impact of technological advancements, such as digital radiography and 3D imaging, on the precision and efficiency of microsurgical procedures is also explored. By providing a comprehensive overview of the existing evidence, the present review will assist clinicians in making informed decisions regarding the selection of microsurgical techniques and adjunctive therapies to optimise patient outcomes.

Keywords: Apical resection, Dental surgery, Minimally invasive dentistry, Microsurgical techniques, Root canal treatment

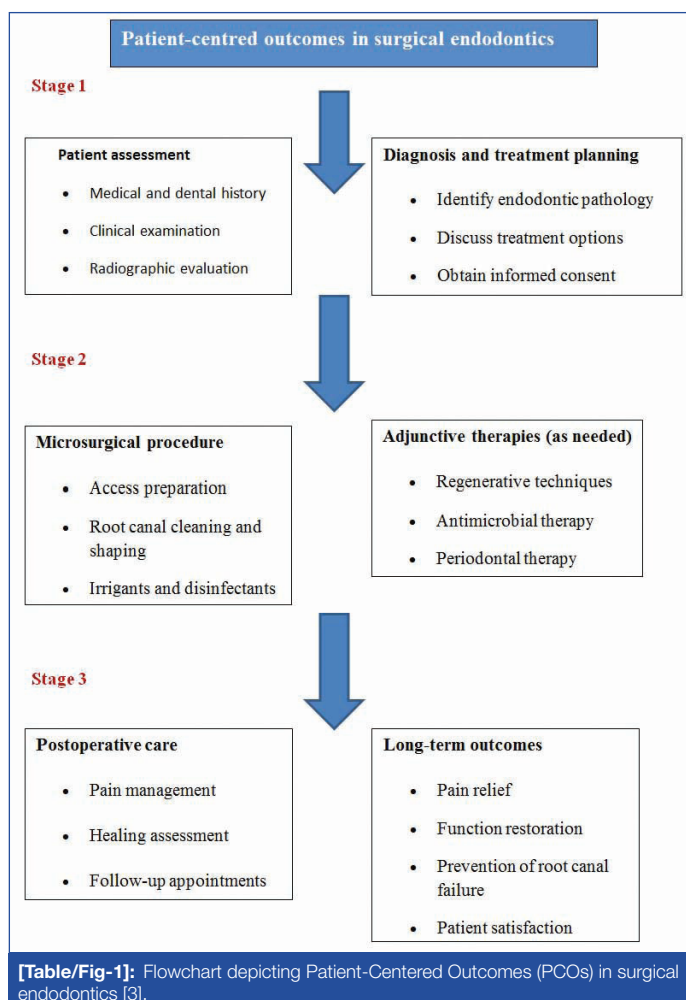
INTRODUCTION

The EMS, a specialised technique involving the use of a surgical microscope for root canal procedures, has emerged as a valuable tool in modern dentistry [1]. This approach offers enhanced visualisation and precision, allowing for more accurate and effective treatment of complex endodontic cases [2].

Over the years, EMS has undergone significant advancements, with the introduction of newer technologies, surgical techniques and a growing emphasis on PCOs. These developments have contributed to improved treatment success rates and enhanced patient satisfaction [Table/Fig-1] [3]. Advanced imaging technologies, such as Cone Beam Computed Tomography (CBCT), have revolutionised the field of dentistry, providing more accurate and detailed information about dental structures. In particular, CBCT has proven to be invaluable in endodontics and the treatment of tooth infections. One significant advantages of CBCT is its ability to create three-dimensional images of the teeth and surrounding tissues. Kolarkodi SH reviewed the 804 studies on CBCT, highlighting its significance in endodontics, particularly in assessing root morphology and revealing a high prevalence of single canals in maxillary incisors [4]. By understanding the root canal anatomy, dentists can improve the success rate of root canal treatments and reduce the risk of complications. Additionally, CBCT can be used to guide surgical procedures, such as root-end resection. By visualising the root canal anatomy in three dimensions, dentists can more accurately locate and remove infected tissue, minimising the risk of damaging healthy structures [5]. While apical surgery remains a valuable treatment option for persistent or recurrent dental infections, the success of this procedure depends on effective root-end filling [6]. CBCT can help ensure that the root-end cavity is adequately prepared and that the filling material is placed correctly, thereby improving the chances of long-term healing. By providing detailed information about root canal anatomy and guiding surgical procedures, CBCT has the potential to improve patient outcomes and reduce the need for more invasive treatments [7,8].

Patient-centered care in surgical endodontics prioritises the patient's needs, preferences and values in treatment decisions. Key

principles include active patient involvement, empathy, respect for autonomy, effective communication and pain management. Dental professionals should show empathy, respect patient autonomy and prioritise pain management throughout the procedure and postoperative period for patient comfort and satisfaction [9,10].



Traditional endodontic practices often relied on two-dimensional imaging and manual techniques, which posed limitations in accurately identifying complex canal anatomies and lesions [3]. In contrast, modern endodontics integrates advanced imaging modalities like CBCT and microsurgical techniques, enabling a higher degree of precision and reducing procedural errors [11]. These refinements in surgical techniques, such as ultrasonic instrumentation and microsurgical sutures, have led to improved healing and reduced postoperative complications. Adjunctive therapies, such as platelet-rich fibrin and Platelet-rich Plasma (PRP), have shown promise in tissue healing and inflammation reduction. Standardised Patient-reported Outcome (PRO) measures have also been developed for a more comprehensive evaluation of treatment success [12]. The comparison highlights the paradigm shift from invasive, less predictable treatments to minimally invasive procedures with enhanced outcomes, further aligning with the principles of patient-centered care. Hence, the present review aimed to provide a comprehensive overview of the evolution of EMS, highlighting key advancements in surgical techniques, adjunctive therapies and PCOs.

LITERATURE SEARCH

A thorough literature search was conducted using the following databases: PubMed, Scopus, Web of Science and Google Scholar. Relevant studies were identified using keywords such as “EMS,” “surgical techniques,” “adjunctive therapies,” “patient-centered outcomes,” “CBCT,” and “3D-printed surgical guides.”

Data points extracted from each study included study design, sample size, intervention, outcome measures, key findings and conclusions. The extracted data were analysed using a thematic approach to identify common themes and patterns. The studies were compared to identify similarities and differences in techniques, outcomes and conclusions. Emerging trends and future directions were discussed based on the findings of the included studies, specifically assessing the impact of Cone Beam Computed Tomography (CBCT) in Endodontic Microsurgery (EMS).

The EMS uses CBCT to treat complex cases of apical periodontitis. CBCT provides detailed three-dimensional images of the tooth and surrounding tissues, improving patient outcomes by reducing postoperative swelling and discomfort. It also shortens surgical time by providing accurate presurgical planning [13,14].

The study done by Gurusamy K et al., compared the impact of periapical surgery on quality of life and healing outcomes using CBCT imaging versus Periapical Radiographs (PR). The results showed that CBCT patients experienced less early postoperative swelling and limitations in general functions compared to PR patients [12]. Preoperative CBCT had no significant impact on other quality-of-life parameters or intraoperative complications in patients with moderate risk but provided surgically relevant anatomical information for presurgical planning and reduced operative time [15].

Dhamija R et al., evaluated EMS in large periapical lesions using PRP at 1-year and 5-year follow-ups. The results showed an improvement in the overall success rate from 66.7% at 1 year to 83.3% at 5 years. PRP group showed better 3D healing and a higher number of completely healed teeth. The RACB index, using CBCT, improved the estimation of healing [16].

Another study by Dhamija R et al., evaluated the effectiveness of PRP in the healing of periapical lesions using 2-dimensional radiographs and 3D CBCT imaging. The results showed a 93.7% success rate for both groups, with PRP showing a faster re-establishment of the palatal cortical plate. CBCT imaging provided better postsurgery assessment [17].

The study examined the impact of collagen membranes on healing through-and-through periapical lesions using 2D and 3D imaging techniques. A total of 30 patients with radiolucencies were divided

into groups with and without Guided Tissue Regeneration (GTR). Results showed a significant reduction in lesion size, but no benefit from collagen membrane. Both CBCT and PA allowed similar healing assessments [18].

CBCT also enhances treatment planning by providing detailed anatomical information about complex root canal anatomy, enabling more accurate measurement of bone levels and identification of potential obstacles. This combination of CBCT and EMS offers significant benefits for patients and clinicians [19].

DISCUSSION

Automated endodontic/periapical lesion detection for patient-centered outcomes in surgical endodontics: Applying automated detection systems for endodontic and periapical lesions holds significant promise for improving patient-centered outcomes (PCOs) in surgical endodontics [Table/Fig-2]. These systems utilise deep learning methods like Convolutional Neural Networks (CNNs) and Deep Learning Algorithms (DLAs) and have been explored with various imaging modalities like CBCT scans, Panoramic Radiographs (OPGs) and PRs. Studies have successfully detected and classified lesions, with applications ranging from non invasive differential diagnosis to accurate diagnosis and lesion classification for apical pathosis [20,21].

Authors	Method	Imaging modality	Lesion type	Application
Okada K et al., [23]	CAD	CBCT	Periapical lesions	Non invasive differential diagnosis
Birdal RG et al., [24]	Discrete Wavelet Transform (DWT)	OPGs	Apical lesions	Examining radiographs
Ekert T et al., [25]	Deep CNN	OPGs	Apical lesions	Lesion detection
Endres MG et al., [26]	Deep Learning Algorithm (DLA)	OPGs	Periapical lesions	Periapical disease detection
Orhan K et al., [27]	Deep CNNs	CBCTs	Apical pathosis	Accurate diagnoses
Setzer FC et al., [28]	DLA	CBCTs	Periapical lesions	Lesion detection
Chen H et al., [29]	Deep CNNs	PRs	Dental disease	Lesion detection
Li CW et al., [30]	CNNs	Standardised image database	Apical lesions	Lesion detection
Pauwels R et al., [31]	Convolutional CNNs	Simulated periapical lesions	Periapical lesions	Lesion detection
Calazans MAA et al., [32]	CNN-based Siamese Network	CBCTs	Apical lesion classification	Diagnostic support
Hamdan MH et al., [33]	Dentist AI DL Tool	PRs	Apical radiolucency's	diagnostic tool
Kimbauer B et al., [34]	Deep CNNs	CBCTs	Osteolytic apical lesions	Lesion detection
Li S et al., [35]	DLM	PRs	Dental caries, Apical periodontitis	Lesion detection
Moidu NP et al., [36]	CNNs	PRs	Apical lesions	Lesion classification
Vasdev D et al., [37]	Pipelined Deep NN model (AlexNet)	PRs	Dental disease	Disease classification
Issa J et al., [38]	Diagnocat AI System	PRs	Apical periodontitis	Lesion detection

[Table/Fig-2]: Automated endodontic/periapical lesion detection for Patient-Centered Outcome (PCOs) in surgical endodontics [23-38].

DWT: Discrete wavelet transform; DLA: Deep learning algorithm; DLS: Deep learning systems; PAI: Periapical index; DSR: Digital subtraction radiography; PR: Periapical radiographs

This technology offers several advantages for patient care. By enabling earlier and more precise detection of periapical lesions, these systems can facilitate timely surgical intervention, potentially reducing the need for more extensive procedures and improving

treatment success rates [20]. Additionally, by leveraging readily available radiographs like PRs, these systems can potentially improve accessibility to diagnosis in resource-limited settings. Overall, the integration of automated lesion detection in surgical endodontics has the potential to enhance diagnostic accuracy, improve treatment planning and ultimately lead to better patient outcomes [22]. The application of automated endodontic/periapical lesion detection for PCOs in surgical endodontics is illustrated in [Table/Fig-2] [23-38].

Patient-centered outcomes in Endodontic Microsurgery (EMS): Endodontics is increasingly focusing on PCOs and PROs to evaluate the effectiveness of treatments for conditions such as pulpitis and apical periodontitis [39].

Patient-centered Outcomes (PCOs): These are objective, clinician-assessed measures derived from non patient data, such as radiographic healing, the absence of infection and the restoration of normal tooth function. They provide critical insights into the technical success and clinical efficacy of endodontic procedures, often relying on diagnostic tools like CBCT or radiographs [39].

Patient-reported Outcomes (PROs): These are subjective outcomes directly reported by patients, encompassing aspects like pain levels, ease of chewing and overall satisfaction with the treatment.

PROs offer a unique perspective on the patient's experience, emphasising functional status, symptom relief and health-related quality of life [40].

By integrating both PCOs and PROs, endodontic research and practice can provide a more comprehensive evaluation of treatment effectiveness. Limited evidence suggests high tooth survival rates and minimal need for intervention; however, the relationship between oral health-related quality of life and endodontic treatment remains underexplored. The studies reviewed here highlight significant advancements in Endodontic Microsurgery (EMS). Initially focused

on improving surgical technique and outcomes, research has shifted towards patient-centered approaches, evaluating not only clinical success but also patient satisfaction, quality of life and pain management [Table/Fig-3] [41-53].

Technological advancements, such as the use of CBCT and 3D-printed surgical guides, have further enhanced the precision and accuracy of microsurgery. Overall, these studies highlight the growing emphasis on providing not just effective but also patient-friendly endodontic care.

Zhao D et al., designed 3D-printed surgical guide and tested its accuracy in endodontic microsurgeries. The guide was applied to seven patients who underwent upper anterior teeth endodontic microsurgeries, while the control group had no guide. CBCT and oral digital scanning data were used to reconstruct 3D models of periapical lesions. The guides showed better apical resection length and angle deviations compared to the control group. The 3D-printed guide improved the accuracy of EMS by fixing the position and angle of apectomy [51].

A retrospective cohort study evaluated the long-term healing outcomes of EMS patients over 10-17.5 years. Results showed an 80.5% 10-year survival rate with 63.4% success. Factors such as tooth type, mobility, preoperative lesion size, clinical crown-to-root ratio and crown restorations were significantly associated with success and survival over 10 years. The study suggests that preoperative status and tooth condition may be key prognostic determinants [53].

Recent techniques in endodontic pain management aim to improve patient outcomes. Endodontic pain management has seen recent advancements, incorporating techniques like Gamma-aminobutyric Acid (GABA)ergic signalling, acupuncture, in-silico modulation and Low-level Laser Therapy (LLLT) [54].

Study	Publication year	Intervention	Outcome measure	Key findings	Patient-centered benefit
Timock AM et al., [41]	2011	CBCT measurement	Accuracy and reliability	CBCT provided accurate and reliable representations of buccal alveolar bone dimensions	Improved surgical planning and treatment
Setzer FC et al., [1]	2012	Microsurgery with vs. without magnification	Success rates	Microsurgery with magnification had higher success rates	Improved surgical outcomes
Del Fabbro M et al., [42]	2012	Platelet concentrate vs. control	Pain, swelling, function	The platelet concentrate group had less pain, swelling and improved function	Faster return to normal activities
Kurt SN et al., [43]	2014	Periradicular surgery using vestibular approach	Outcomes of surgery	Conventional radiography vs. CBCT	Improved surgical planning
Angerame D et al., [44]	2015	Endodontic surgery with vs. without PRF	Pain, radiographic healing	PRF group experienced less pain and faster healing	Reduced discomfort and potentially faster recovery
Chen I et al., [45]	2015	Root-end microsurgery using MTA vs. RRM	Healing assessment	RRM showed superior healing	Potential for improved tissue healing
Soto-Peñaloza D et al., [46]	2020	Endodontic surgery with vs. without A-PRF+ membrane	Pain, quality of life	A-PRF+ membrane improved postoperative quality of life	Reduced discomfort and improved healing
Azim AA et al., [47]	2021	Endodontic Microsurgery (EMS) using PA vs. CBCT	Success and survival rates, prognostic factors	CBCT may provide more information for surgical planning	Improved surgical precision
Bharathi J et al., [48]	2021	Endodontic Microsurgery (EMS) using piezoelectric device vs. control	Postoperative pain, swelling, and analgesic use	Piezo group experienced less pain and swelling and needed fewer painkillers	Faster recovery and improved quality of life
Vieth MP et al., [49]	2022	Endodontic surgery with vs. without dexamethasone	Postoperative pain and swelling	Dexamethasone significantly reduced pain and swelling	Reduced discomfort after surgery
Zhang MM et al., [50]	2023	Endodontic Microsurgery (EMS)	Radiographic healing	High success rate (88.5% complete healing), lesion type and root filling quality affect outcome	Predictable outcomes
Zhao D et al., [51]	2023	3D-printed surgical guide for microsurgery	Apical resection accuracy	Improved accuracy of surgery (length and angle)	Potentially faster surgery and better outcomes
Al-Nazhan S [52]	2024	Endodontic Microsurgery (EMS) by residents	Clinical and radiographic exam	100% tooth survival, 91.66% complete/incomplete healing	High success rate
Yoo YJ et al., [53]	2024	Endodontic Microsurgery (EMS)	Clinical and radiographic exam (10+ years)	80.5% survival rate at 10 years, tooth condition impacts long-term success	Improved prognosis

[Table/Fig-3]: Automated endodontic/periapical lesion detection for Patient-Centered Outcome (PCOs) in surgical endodontics [1,41-53]. DWT: Discrete wavelet transform; DLA: Deep learning algorithm; DLS: Deep learning systems; PAI: Periapical index; DSR: Digital subtraction radiography; PR: Periapical radiographs

The GABAergic signalling, utilising the presence of functional GABA receptors in inflamed dental pulp, shows promise in managing endodontic pain [55]. Acupuncture, when combined with local anaesthesia, has been explored as a complementary therapy to reduce patient anxiety and minimise the need for oral analgesics [56].

In-silico modulation targets the inhibition of IL-8 in inflamed periapical tissues, employing small molecules like ZINC14613097 [57]. LLLT, which harnesses laser photonic energy during root canal procedures, has also gained attention as a potential pain management strategy, but its effectiveness remains debated [58]. More randomised controlled trials are needed to determine its effectiveness. [Table/Fig-4] compares endodontic techniques and adjunctive therapies for managing endodontic pain, aiming to improve patient outcomes and oral health.

Technique or therapy	Advantages	Disadvantages
Traditional endodontics	Less invasive, often suitable for simpler cases	Limited visibility and accessibility in complex cases
Endodontic Microsurgery (EMS)	Enhanced magnification and illumination, improved precision and outcomes, especially in complex cases	Requires specialised training and equipment
CBCT and 3D-printed surgical guides	Improved visualisation and surgical planning	Increased cost and radiation exposure (CBCT)
PRF and PRP	Promote healing, reduce inflammation	Potential for variability in preparation and application
Dexamethasone	Reduces postoperative pain and swelling	Potential for systemic side effects
Patient-centered outcomes	Emphasises patient satisfaction and quality of life	Requires standardised measures for accurate comparison

[Table/Fig-4]: Advantages and disadvantages of different endodontic techniques and adjunctive therapies.

Future directions: Future research should focus on developing standardised PRO measures, evaluating the cost-effectiveness of different techniques, identifying predictive biomarkers, exploring minimally invasive approaches, conducting long-term follow-up studies and fostering interdisciplinary collaboration. By addressing these areas, future research can contribute to further advancements in endodontic microsurgery (EMS) and ensure that patients receive the best possible care.

CONCLUSION(S)

The present review offers valuable insights into the evolution of Endodontic Microsurgery (EMS). While significant advancements have been made in surgical techniques, the focus has increasingly shifted towards Patient-centered Outcomes (PCOs). Technological advancements, such as the use of CBCT and 3D-printed surgical guides, have further enhanced the precision and accuracy of microsurgery. Adjunctive therapies, like PRP and dexamethasone, have shown promise in improving healing and reducing postoperative discomfort.

REFERENCES

- Setzer FC, Kohli MR, Shah SB, Karabucak B, Kim S. Outcome of endodontic surgery: A meta-analysis of the literature-Part 2: Comparison of endodontic microsurgical techniques with and without the use of higher magnification. *J Endod.* 2012;38(1):01-10.
- Reddy S, Gadhiraaju S, Quraishi A, Karnishetty S. Targeted endodontic microsurgery: A guided approach - a report of two cases. *Contemp Clin Dent.* 2022;13(3):280-83.
- Setzer FC, Kratchman SI. Present status and future directions: Surgical endodontics. *Int Endod J.* 2022;55(S4):1020-58.
- Kolarkodi SH. The importance of cone-beam computed tomography in endodontic therapy: A review. *Saudi Dent J.* 2023;35(7):780-84.
- Scarfe WC, Levin MD, Gane D, Farman AG. Use of cone beam computed tomography in endodontics. *Int J Dent.* 2009;2009:634567. Doi: 10.1155/2009/634567.
- Von Arx T, Marwik E, Bornstein MM. Effects of dimensions of root-end fillings and peripheral root dentine on the healing outcome of apical surgery. *Eur Endod J.* 2019;4(2):49-56.
- Kruse C, Spin-Neto R, Christiansen R, Wenzel A, Kirkevang LL. Periapical bone healing after apicectomy with and without retrograde root filling with mineral trioxide aggregate: A 6-year follow-up of a randomized controlled trial. *J Endod.* 2016;42(4):533-37.
- Kaasalainen T, Ekholm M, Siiskonen T, Kortesianiemi M. Dental cone beam CT: An updated review. *Phys Med.* 2021;88:193-217. Doi: 10.1016/j.ejmp.2021.07.007.
- Epstein RM, Street RL Jr. The values and value of patient-centered care. *Ann Fam Med.* 2011;9(2):100-03.
- Mao T, Neelakantan P. Three-dimensional imaging modalities in endodontics. *Imaging Sci Dent.* 2014;44(3):177-83.
- Langaliya A, Chaudhari E, Patel A, Shah J. Computer-aided design-CAM-guided endodontic microsurgical localization and retrieval of two separated instruments from the periapical area of a mandibular second molar. *Endodontology.* 2021;33(2):112-17.
- Gurusamy K, Duhan J, Tewari S, Sangwan P, Gupta A, Mittal S, et al. Patient-centric outcome assessment of endodontic microsurgery using periapical radiography versus cone beam computed tomography: A randomized clinical trial. *Int Endod J.* 2023;56(1):03-16.
- Villa-Machado PA, Restrepo-Patiño DM, Calvo-Trejos JP, Restrepo-Restrepo FA, Tobón-Arroyave SI, Provenzano JC, et al. Cone-beam computed tomographic and micro-computed tomographic evaluations of the root apices of teeth with posttreatment apical periodontitis. *J Endod.* 2020;46(11):1695-701. Doi: 10.1016/j.joen.2020.07.009.
- Patel S, Durack C, Abella F, Shemesh H, Roig-Cayón M, Lemberg K. Cone beam computed tomography in endodontics: A review. *Int Endod J.* 2014;48(1):03-15. Doi: 10.1111/iej.12270.
- Klatt JC, Sorowka T, Kluwe L, Smeets R, Gosau M, Hanken H. Does a preoperative cone beam CT reduce complication rates in the surgical removal of complex lower third molars? A retrospective study included 486 cases. *Head Face Med.* 2021;17(1):33. Doi: 10.1186/s13005-021-00271-5.
- Dhamija R, Tewari S, Gupta A. Two- and three-dimensional healing assessment after endodontic microsurgery in through-and-through periapical lesions: 5-year follow-up from a randomized controlled trial. *Int Endod J.* 2024;57(9):1180-99.
- Dhamija R, Tewari S, Sangwan P, Duhan J, Mittal S. Impact of platelet-rich plasma in the healing of through-and-through periapical lesions using 2-dimensional and 3-dimensional evaluation: A randomized controlled trial. *J Endod.* 2020;46(9):1167-84.
- Parmar PD, Dhamija R, Tewari S, Sangwan P, Gupta A, Duhan J, et al. 2D and 3D radiographic outcome assessment of the effect of guided tissue regeneration using resorbable collagen membrane in the healing of through-and-through periapical lesions - a randomized controlled trial. *Int Endod J.* 2019;52(7):935-48.
- Rios-Osorio N, Quijano-Guauque S, Briñez-Rodríguez S, Velasco-Flechas G, Muñoz-Solis A, Chávez C, et al. Cone-beam computed tomography in endodontics: From the specific technical considerations of acquisition parameters and interpretation to advanced clinical applications. *Restor Dent Endod.* 2023;49(1):e1.
- Asgary S. Artificial intelligence in endodontics: A scoping review. *Iran Endod J.* 2024;19(2):85-98.
- Musri N, Christie B, Ichwan SJA, Cahyanto A. Deep learning convolutional neural network algorithms for the early detection and diagnosis of dental caries on periapical radiographs: A systematic review. *Imaging Sci Dent.* 2021;51(3):237-42.
- Umer F, Habib S. Critical analysis of artificial intelligence in endodontics: A scoping review. *J Endod.* 2021;48(11):1696-705.
- Okada K, Rysavy S, Flores A, Lingurar MG. Noninvasive differential diagnosis of dental periapical lesions in cone-beam CT scans. *Med Phys.* 2015;42(4):1653-65.
- Birdal RG, Gumus E, Serbas A, Birdal IS. Automated lesion detection in panoramic dental radiographs. *Oral Radiol.* 2016;32(2):111-18.
- Ekert T, Krois J, Meinhold L, Elhennawy K, Emara R, Golla T, et al. Deep learning for the radiographic detection of apical lesions. *J Endod.* 2019;45(7):917-922e5.
- Endres MG, Hillen F, Salloumis M, Sedaghat AR, Niehues SM, Quatela O, et al. Development of a deep learning algorithm for periapical disease detection in dental radiographs. *Diagnostics (Basel).* 2020;10(6):430.
- Orhan K, Bayraktar IS, Ezhov M, Kravtsov A, Özyürek T. Evaluation of artificial intelligence for detecting periapical pathosis on cone-beam computed tomography scans. *Int Endod J.* 2020;53(5):680-89.
- Setzer FC, Shi KJ, Zhang Z, Yan H, Yoon H, Mupparapu M, et al. Artificial intelligence for the computer-aided detection of periapical lesions in cone-beam computed tomographic images. *J Endod.* 2020;46(7):987-93.
- Chen H, Li H, Zhao Y, Zhao J, Wang Y. Dental disease detection on periapical radiographs based on deep convolutional neural networks. *Int J Comput Assist Radiol Surg.* 2021;16(4):649-61.
- Li CW, Lin SY, Chou HS, Chen TY, Chen YA, Liu SY. Detection of dental apical lesions using cnns on periapical radiograph. *Sensors.* 2021;21(21):7049.
- Pauwels F, Brasil DM, Yamasaki MC, Jacobs R, Bosmans H, Freitas DQ, et al. Artificial intelligence for detection of periapical lesions on intraoral radiographs: Comparison between convolutional neural networks and human observers. *Oral Surg Oral Med Oral Pathol Oral Radiol.* 2021;131(5):610-16.
- Calazans MAA, Ferreira FABS, Alcoforado MLMG, Santos AD, Pontual ADA, Madeiro F, et al. Automatic Classification system for periapical lesions in cone-beam computed tomography. *Sensors (Basel).* 2022;22(17):6481.
- Hamdan MH, Tuzova L, Mol A, Tawil PZ, Tuzoff D, Tyndall DA, et al. The effect of a deep-learning tool on dentists' performances in detecting apical radiolucencies on periapical radiographs. *Dentomaxillofac Radiol.* 2022;51(7):20220122.
- Kirnbauer B, Hadzic A, Jakse N, Bischof H, Stern D. Automatic detection of periapical osteolytic lesions on cone-beam computed tomography using deep convolutional neural networks. *J Endod.* 2022;48(11):1434-40.

- [35] Li S, Liu J, Zhou Z, Zhou Z, Wu X, Li Y, et al. Artificial intelligence for caries and periapical periodontitis detection. *J Dent.* 2022;122:104107.
- [36] Moidu NP, Sharma S, Chawla A, Kumar V, Logani A. Deep learning for categorization of endodontic lesion based on radiographic periapical index scoring system. *Clin Oral Investig.* 2022;26(1):651-58.
- [37] Vasdev D, Gupta V, Shubham S, Chaudhary A, Jain N, Salimi M, et al. Periapical dental X-ray image classification using deep neural networks. *Ann Oper Res.* 2022;310:1-29.
- [38] Issa J, Jaber M, Rifai I, Mozdziaik P, Kempisty B, Dyszkiewicz-Konwinska M. Diagnostic test accuracy of artificial intelligence in detecting periapical periodontitis on two-dimensional radiographs: A retrospective study and literature review. *Medicina (Kaunas).* 2023;59(4):768.
- [39] Dogramaci EJ, Rossi Fedele G. Patient related outcomes and oral health related quality of life in endodontics. *Int Endod J.* 2022;56(S2):169-87.
- [40] Weldring T, Smith SM. Patient-Reported Outcomes (PROs) and Patient-Reported Outcome Measures (PROMs). *Health Serv Insights.* 2013;6:61-68.
- [41] Timock AM, Cook V, McDonald T, Leo MC, Crowe J, Benninger BL, et al. Accuracy and reliability of buccal bone height and thickness measurements from cone-beam computed tomography imaging. *Am J Orthod Dentofacial Orthop.* 2011;140(6):734-44.
- [42] Del Fabbro M, Ceresoli V, Lolato A, Taschieri S. Effect of platelet concentrate on quality of life after periradicular surgery: A randomized clinical study. *Journal of Endodontics.* 2012;38:733-39.
- [43] Kurt SN, Üstün Y, Erdogan Ö, Evlice B, Yoldas O, Öztunc H. Outcomes of periradicular surgery of maxillary first molars using a vestibular approach: A prospective, clinical study with one year of follow-up. *Journal of Oral and Maxillofacial Surgery.* 2014;72:1049-61.
- [44] Angerame D, De Biasi M, Kastrioti I, Franco V, Castaldo A, Maglione M. Application of platelet-rich fibrin in endodontic surgery: A pilot study. *G Ital Endod.* 2015;29:51-57. <https://doi.org/10.1016/j.gien.2015.08.003>.
- [45] Chen I, Karabucak B, Wang C, Wang HG, Koyama E, Kohli MR, et al. Healing after root-end microsurgery by using mineral trioxide aggregate and a new calcium silicate-based bioceramic material as root-end filling materials in dogs. *Journal of Endodontics.* 2015;41:389-99.
- [46] Soto-Peñaloza D, Peñarocha-Diago M, Cervera-Ballester J, Peñarocha-Diago M, Tarazona-Alvarez B, Peñarocha-Oltra D. Pain and quality of life after endodontic surgery with or without advanced platelet-rich fibrin membrane application: A randomized clinical trial. *Clinical Oral Investigations.* 2020;24:1727-38.
- [47] Azim AA, Albanyan H, Azim KA, Piasecki L. The Buffalo study: Outcome and associated predictors in endodontic microsurgery-a cohort study. *International Endodontic Journal.* 2021;54:301-18.
- [48] Bharathi J, Mittal S, Tewari S, Tewari S, Duhan J, Sangwan P, et al. Effect of the piezoelectric device on intraoperative hemorrhage control and quality of life after endodontic microsurgery: A randomized clinical study. *Journal of Endodontics.* 2021;47:1052-60.
- [49] Vieth MP, Deas DE, Archontia Palaiologou A, Diogenes A, Mader MJ, Mealey BL. Effect of intravenous dexamethasone on postoperative pain and swelling following periodontal flap surgery: A randomized controlled trial of patient-centred outcomes. *J Periodontol.* 2022;93(2):237-45. Doi: 10.1002/JPER.21-0153.
- [50] Zhang MM, Fang GF, Wang ZH, Liang YH. Clinical outcome and predictors of endodontic microsurgery using cone-beam computed tomography: A retrospective cohort study. *Journal of Endodontics.* 2023;49(11):1464-71. <https://doi.org/10.1016/j.joen.2023.08.011>.
- [51] Zhao D, Xie W, Li T, Wang A, Wu L, Kang W, et al. New-designed 3D printed surgical guide promotes the accuracy of endodontic microsurgery: A study of 14 upper anterior teeth. *Sci Rep.* 2023;13:15512. <https://doi.org/10.1038/s41598-023-42767-x>.
- [52] Al-Nazhan S, Alohali L, Alharith D, Al-maflehi N. Outcome of endodontic microsurgery performed by postgraduate students: A retrospective study. *Turkish Endodontic Journal.* 2024;9(1):47-55. <https://doi.org/10.14744/tej.2024.49469>.
- [53] Yoo YJ, Cho EB, Perinpanayagam H, Gu Y, Zhu Q, Noblett WC, Kum KY. Endodontic microsurgery outcomes over 10 years and associated prognostic factors: A retrospective cohort study. *J Endod.* 2024;50(7):934-43. <https://doi.org/10.1016/j.joen.2024.04.009>.
- [54] Falatah AM, Almalki RS, Al-Qahtani AS, Aljumaah BO, Almihdar WK, Almutairi AS. Comprehensive strategies in endodontic pain management: An integrative narrative review. *Cureus.* 2023;15(12):e50371. Doi: 10.7759/cureus.50371.
- [55] Sivakumar D, Ramli R. GABAergic signalling in modulation of dental pain. *Eur J Pharmacol.* 2022;924:174958. Doi: 10.1016/j.ejphar.2022.174958. Epub 2022 Apr 14. PMID: 35429491.
- [56] Rosted P. Introduction to acupuncture in dentistry. *Br Dent J.* 2000;189(3):136-40. Doi: 10.1038/sj.bdj.4800704. PMID: 11021030.
- [57] Boreak N, Bhandi S. In-Silico modulation of Interleukin-8 (IL8) for the therapeutic management of endodontic pulpitis. *Saudi J Biol Sci.* 2022;29(2):905-10. Doi: 10.1016/j.sjbs.2021.10.015. Epub 2021 Oct 25. PMID: 35197758; PMCID: PMC8848128.
- [58] Guerreiro MYR, Monteiro LPB, de Castro RF, Magno MB, Maia LC, da Silva Brandão JM. Effect of low-level laser therapy on postoperative endodontic pain: An updated systematic review. *Complement Ther Med.* 2021;57:102638. Doi: 10.1016/j.ctim.2020.102638. Epub 2020 Dec 8. PMID: 33307205.

PARTICULARS OF CONTRIBUTORS:

1. Assistant Professor and Consultant in Endodontic Division, Department of Restorative Dentistry, Faculty of Dental Medicine at Umm Al-Qura University, Makkah, Saudi Arabia.

NAME, ADDRESS, E-MAIL ID OF THE CORRESPONDING AUTHOR:

Dr. Haytham Jaha,
Assistant Professor and Consultant in Endodontic Division, Department of Restorative Dentistry, Faculty of Dental Medicine at Umm Al-Qura University, Makkah, Saudi Arabia.
E-mail: hsjaha@uqu.edu.sa

PLAGIARISM CHECKING METHODS: [Jain H et al.]

- Plagiarism X-checker: Nov 05, 2024
- Manual Googling: Dec 10, 2024
- iThenticate Software: Dec 12, 2024 (15%)

ETYMOLOGY: Author Origin**EMENDATIONS:** 6**AUTHOR DECLARATION:**

- Financial or Other Competing Interests: None
- Was informed consent obtained from the subjects involved in the study? NA
- For any images presented appropriate consent has been obtained from the subjects. NA

Date of Submission: **Nov 04, 2024**Date of Peer Review: **Nov 20, 2024**Date of Acceptance: **Dec 14, 2024**Date of Publishing: **Jan 01, 2025**