

# Histomorphological Study of Rodenticide Poisoning: An Autopsy-based Cross-sectional Study from a Tertiary Care Centre, Krishnagiri, Tamil Nadu, India

P NARMADHA PRIYA<sup>1</sup>, JAYALAKSHMY PECHIMUTHU<sup>2</sup>, V PALANIAPPAN<sup>3</sup>, TELEFLO BOOPATHY<sup>4</sup>, JEEVANANDHAM ANBAZHAGAN<sup>5</sup>, JEEVITHA MUNIRAJ<sup>6</sup>



## ABSTRACT

**Introduction:** In the rise of the modern era, which intensifies mental health issues, some individuals consider suicide using methods such as poison ingestion. Rodenticides, commonly used for pest control, including brodifacoum, bromadiolone and bromethalin, are often involved in these cases. In a retrospective study conducted by the National Poison Information Centre, it was found that death due to rodenticide poisoning accounted for about 17.06% when compared to other pesticides, indicating a rise in the global burden of rodenticide poisoning. Prompt medical intervention and hospitalisation are vital in cases of rodenticide poisoning. Hence, histomorphological examination of affected organs is essential to determine the damage to vital organs, thereby guiding clinicians in future perspectives to facilitate patient recovery.

**Aim:** To study the histomorphological findings of various organs affected by rodenticide poisoning and to assess which organ is most commonly involved.

**Materials and Methods:** This cross-sectional study investigated the effects of rodenticide poisoning through medicolegal autopsy specimens at Government Medical College and Hospital, Krishnagiri, Tamil Nadu, India from June 2023 to June 2024 over a duration of 12 months. The study utilised retrospective data from autopsies, focusing on cases where death resulted from rodenticide poisoning. Autopsy specimens, including the heart, lungs, kidneys, liver, spleen and brain, were preserved in formalin and subjected to gross and microscopic

examination by a pathologist. Histopathological sections were stained with Haematoxylin and Eosin (H&E). The study employed a convenience sampling technique with a sample size of 30, determined using Solvin's formula. Data from crime history, clinical history and autopsy findings were recorded and analysed using Statistical Package for the Social Sciences (SPSS) version 25.0, and compiled to draw conclusions regarding the impact of rodenticide poisoning on organ damage.

**Results:** During the one-year period of the study, 450 medicolegal autopsies were processed, of which 180 (40%) cases were due to poison consumption. Of these, 32 cases (17.78%) were from rodenticide intake. Male predominance was observed in this study, comprising 20 males (62.50%) and 12 females (37.50%), with a ratio of 5:3. Histopathology revealed congestion in most of the organs, with the liver showing steatosis and necrosis, kidneys exhibiting acute tubular necrosis, and lungs displaying haemorrhage and oedema. The heart showed features of atherosclerotic changes in seven cases, whereas the brain showed congestion in 11 cases and cerebral haemorrhage in one case out of the 32 cases, respectively.

**Conclusion:** This study found a higher prevalence of poisoning among males and increased susceptibility in teenagers and elderly individuals. The study emphasises the histomorphological findings of various organs in rodenticide poisoning and concludes that the liver, kidneys and lungs appear to be the most affected organs. It also highlights the importance of yoga in preventing suicides.

**Keywords:** Histomorphology, Organ damage, Poison

## INTRODUCTION

Many individuals experience significant stress due to lifestyle changes, which can contribute to suicidal ideation. This stress often stems from personal issues such as family conflicts, work pressures, or socio-economic challenges and can lead individuals to contemplate ending their lives [1]. Frequently, this tragic decision involves the ingestion of poisons readily available in the commercial market, with rodenticides being among the most commonly used substances in India [2]. Rodenticide poisoning occurs when humans or animals ingest toxic substances intended to eliminate rodents. These poisons can inflict severe damage and can be fatal if not addressed promptly. Rodenticide poisons are primarily classified into two categories: 1) Anticoagulants and 2) Non Anticoagulants. Anticoagulant rodenticides, such as brodifacoum and bromadiolone, function by inhibiting vitamin K-dependent clotting factors (Factors II, V, VII, IX). Non anticoagulant rodenticides, notably Bromethalin, pose even greater risks as

they disrupt the central nervous system, leading to symptoms such as tremors, seizures and potentially respiratory failure [3]. In cases of suspected poisoning, it is imperative to seek immediate medical intervention. Treatment typically involves administering antidotes and supportive care to manage symptoms effectively. Additionally, management may include fluid therapy, oxygen support, blood transfusions and plasmapheresis. Severe cases necessitate hospitalisation for continuous monitoring and symptom management [4].

Histomorphological examination of tissue under a microscope is crucial for identifying the extent of damage to vital organs caused by rodenticide poisoning. This analysis provides valuable insights for clinicians to offer effective symptomatic treatment and expedite patient recovery. Therefore, the objective of this study was to find the histomorphological changes in the heart, lungs, liver, kidneys, spleen and brain in cases of rodenticide poisoning victims.

## MATERIALS AND METHODS

This cross-sectional study was conducted in the Department of Pathology using medicolegal autopsy specimens obtained from the Department of Forensic Medicine at Government Medical College and Hospital, Krishnagiri, Tamil Nadu, India. The study was carried out retrospectively over a one-year period from June 2023 to June 2024, following approval by the Institute's Ethical Committee under number 55062024. The study encompassed all medicolegal autopsies conducted by the Forensic Department of Government Medical College and Hospital, Krishnagiri, during the specified period.

**Inclusion criteria:** Cases where the cause of death was identified as rat poison ingestion were included in the study.

**Exclusion criteria:** Cases involving other types of poisoning or those with fully autolysed tissues in which cell morphology could not be determined under the microscope after processing the tissue were excluded from this study.

**Sample size:** The sample size was determined using the convenience sampling technique, calculated via Solvin's formula:

$$X = N / (1 + Ne^2), X = 30 / (1 + 1(0.05)^2), X = 30$$

Given the adequacy of cases, the study proceeded with the collection of detailed crime history, clinical history and autopsy findings. Upon completion of the autopsy procedures, the relevant organs were dispatched to the Pathology Department for microscopic examination by forensic experts. The specimens analysed included the heart, lungs, kidneys, liver, spleen and brain, which perform vital functions in every individual and are the organs most likely to be damaged in poisoning cases. All the aforementioned organs were preserved in 10% formalin before and after the gross examination, and sections were taken from the specimens for further processing. Finally, histopathological sections were stained with routine H&E.

The following parameters were studied, which included the incidence of rodenticide poisoning, age, sex, fatality duration and histomorphological findings of vital organs, all of which were tabulated.

Both macroscopic and microscopic observations were meticulously documented in a case study format. The microscopic findings were examined by two pathologists to minimise interobserver variability. Conclusions were derived from a comprehensive analysis of both macroscopic and microscopic data, and the findings were systematically compiled and tabulated.

## STATISTICAL ANALYSIS

For statistical analysis, data was entered into Excel and analysed using SPSS version 25.0, and expressed in frequency and percentage. Cross-tabulations were performed to analyse the parameters related to organ-specific findings in rodenticide poisoning.

## RESULTS

During the one-year study period, from June 2023 to June 2024, our department processed specimens from 450 medicolegal autopsies, of which 180 cases (40%) were attributed to poisoning [Table/Fig-1]. Among the 450 autopsy cases, which include both poisoning and non poisoning cases, death due to rodenticide poisoning was found in 32 cases [Table/Fig-2]. Of the 180 cases of poisoning in this study, 32 cases (17.78%) [Table/Fig-3] were specifically due to rodenticide poisoning, while the remaining 148 cases (82.22%) [Table/Fig-4] were attributed to other poisons. The age of the subjects ranged from 11 to over 61 years, with the study cohort comprising 12 females (37.50%) and 20 males (62.50%), indicating a higher prevalence among males [Table/Fig-5]. Among them, the younger age group between 11-20 years had 10 cases (31.25%), followed by the older age group between 50-60 years with eight cases (25.0%) being victims of this poison [Table/Fig-6]. The fatality rate, as detailed in [Table/Fig-7], demonstrates an increased rate of mortality associated with delayed hospitalisation following poison ingestion.

Cases	n (%)
Total number of post-mortems done=450	
Number of poisoning cases	180 (40)

[Table/Fig-1]: Showing the incidence of poisoning cases among the total number of post-mortems.

Cases	n (%)
Total number of post-mortems done=450	
Number of rodenticide poisoning cases	32 (7.11)

[Table/Fig-2]: Showing the incidence of cases poisoned with rodenticide among the total number of post-mortems done.

Cases	n (%)
Total number of poisoning cases	180 (40)
Number of rodenticide poisoning cases	32 (17.78)

[Table/Fig-3]: Showing the number of cases with rodenticides among the number of poisoning cases.

Cases	n (%)
Total number of poisoning cases	180 (40)
Number of poisoning cases other than rodenticides	148 (82.22)

[Table/Fig-4]: Showing the number of poisoning cases other than rodenticides during the year.

Sex	n (%)
Male	20 (62.50)
Female	12 (37.50)

[Table/Fig-5]: Showing the sex incidence of these cases.

Age group (years)	n (%)
0-10	-
11-20	10 (31.25)
21-30	6 (18.75)
31-40	-
41-50	2 (6.25)
51-60	8 (25)
61 and above	6 (18.75)

[Table/Fig-6]: Showing the age incidence from the study group cases.

Fatal period	n (%)
Within half an hour	-
½-1 hr	-
1-2 hrs	-
2-4 hrs	-
4-8 hrs	2 (6.25)
12-24 hrs	5 (15.62)
1-2 days	9 (28.12)
3 days and above	16 (50)

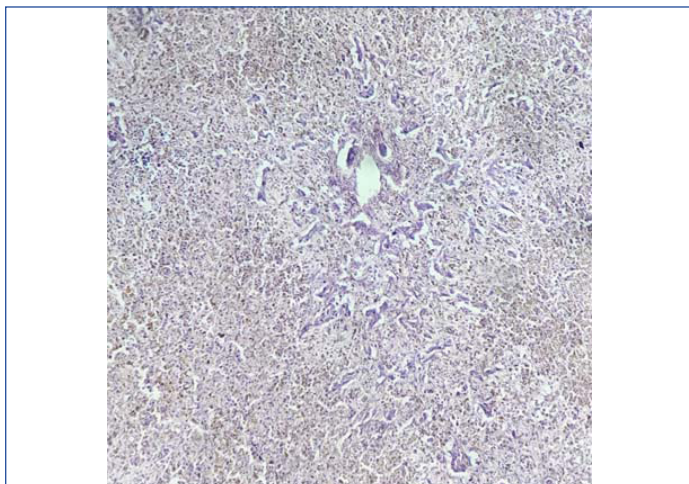
[Table/Fig-7]: Showing the fatal period in study cases.

The primary organs examined in all cases included the heart, lungs, liver, kidneys, spleen and brain. Histopathological examination of the specimens revealed congestion in most organs. Despite the common finding of congestion, significant morphological changes were observed in specific organs under the microscope, as depicted in [Table/Fig-8].

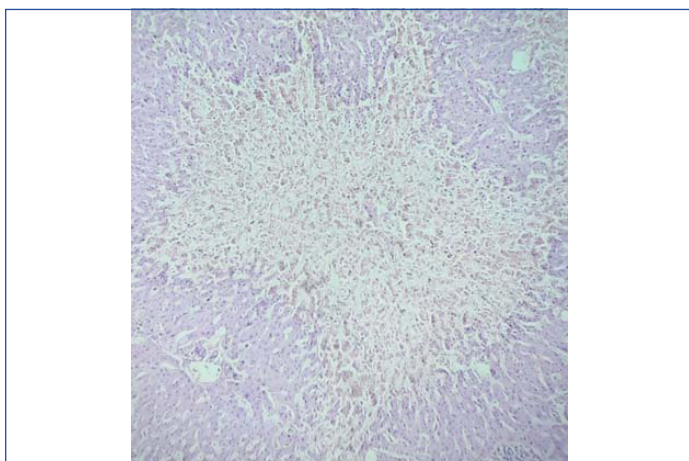
On gross examination, the liver exhibited congestion in most cases. Microscopic examination of the liver showed acute hepatic necrosis (fulminant necrosis) [Table/Fig-9], which occurs at the late stage of rodenticide poisoning and acts as an indicator of end-stage liver disease. However, submassive necrosis [Table/Fig-10] of hepatocytes occurs before fulminant necrosis, indicating partial necrosis of hepatocytes in periportal areas. In this study, most of the

Organ and findings	Out of 32 cases in each organ, n (%)
<b>Liver</b>	
Steatosis	12 (37.50)
Submassive hepatic necrosis	8 (25)
Acute hepatic necrosis (fulminant hepatitis)	6 (18.75)
Chronic Venous Congestion (CVC)	4 (12.50)
Cholestasis	2 (6.25)
<b>Kidney</b>	
Acute tubular necrosis	18 (56.25)
Chronic venous congestion	14 (43.75)
<b>Lungs</b>	
Diffuse alveolar haemorrhage	12 (37.50)
Pulmonary oedema	4 (12.50)
Emphysema	2 (6.25)
Chronic Venous Congestion (CVC)	14 (43.75)
<b>Spleen</b>	
Diffuse splenic haemorrhage	2 (6.25)
Chronic venous congestion	30 (93.75)
<b>Brain</b>	
Normal	20 (62.50)
Congestion	11 (34.37)
Cerebral haemorrhage	1 (3.12)
<b>Heart</b>	
Atherosclerosis	7 (21.88)
Normal	25 (78.12)

**[Table/Fig-8]:** Histomorphological findings of various organs in rodenticide poison.

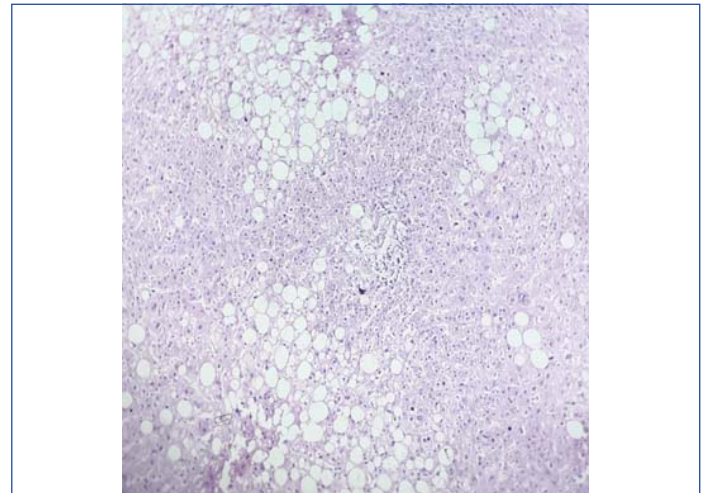


**[Table/Fig-9]:** Histopathological picture of liver shows massive necrosis of hepatocytes sparing the bile duct indicates acute hepatic necrosis (H&E; X40).



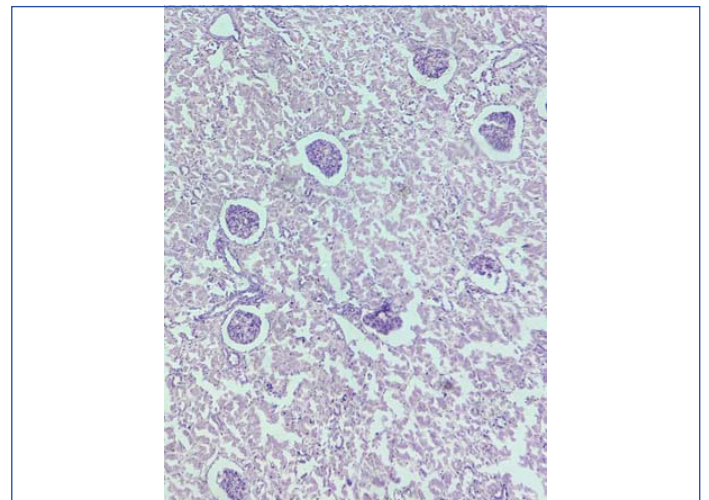
**[Table/Fig-10]:** Histopathological picture of liver shows focal necrosis of hepatocytes surrounded by normal liver parenchyma in submassive necrosis (H&E; X40).

liver specimens showed features of steatosis [Table/Fig-11], which is the accumulation of triglycerides due to hepatic dysfunction in the early stages of poisoning. Finally, in a few cases, cholestasis was observed, which also results from the accumulation of bile pigment due to hepatocytic injury.



**[Table/Fig-11]:** The histopathological picture of the liver shows hepatocytes with fatty changes in hepatic steatosis (H&E; X10).

The kidneys displayed a pale cortex and congested medulla, which denotes acute tubular necrosis grossly in most cases, while the rest of the cases showed congestion. The kidneys predominantly exhibited acute tubular necrosis under microscopic examination as a direct effect of poison on renal tubular epithelial cells [Table/Fig-12].



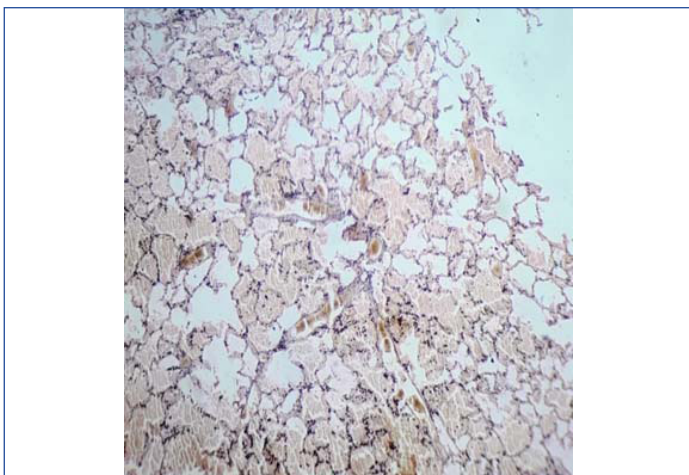
**[Table/Fig-12]:** The histopathological picture from the kidney shows renal tubules exhibiting marked necrosis of tubular epithelial cells in acute tubular necrosis (H&E; X40).

The lungs typically showed congestion grossly in most of the specimens, with some exhibiting heavy congestion and frothy secretion upon dissection. Under the microscope, notable findings in the lungs included diffuse alveolar haemorrhage [Table/Fig-13], emphysema [Table/Fig-14], pulmonary oedema [Table/Fig-15], and chronic venous congestion.

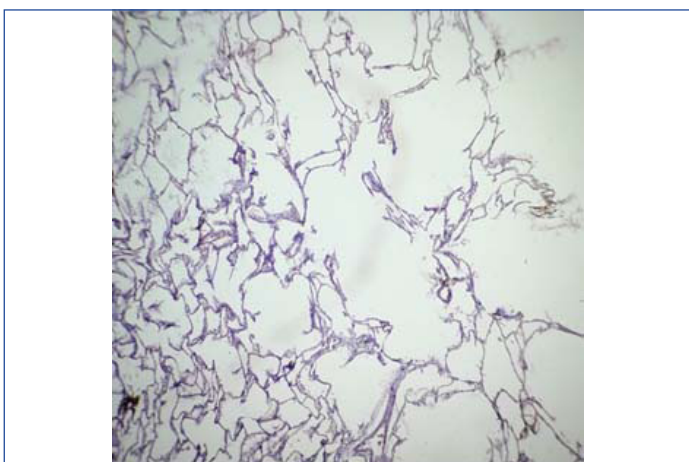
The spleen specimens displayed congestion both grossly and microscopically, with one showing splenic haemorrhage under the microscope.

On gross examination of the heart specimens, most exhibited pinpoint haemorrhages on their external and cut surfaces, associated with congestion. However, under microscopic examination of the sections from the heart, including the ventricles, aorta, and coronaries, most showed normal findings, with a few exhibiting age-related atherosclerotic changes that were not specific to this study.

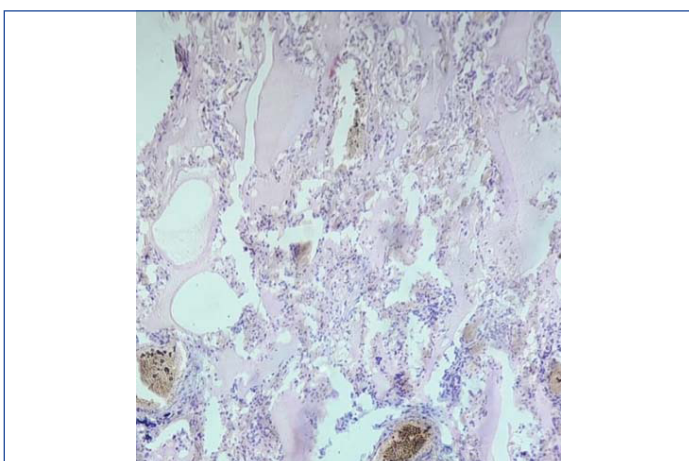
Brain specimens were largely normal both grossly and microscopically, except for one case that revealed cerebral haemorrhage.



**[Table/Fig-13]:** Histopathological picture from lung shows diffuse alveolar haemorrhage (H&E; X10).



**[Table/Fig-14]:** Histopathological picture from lung shows dilated alveoli with emphysematous changes (H&E; X10).



**[Table/Fig-15]:** Histopathological picture from lung shows alveoli filled with fluid in pulmonary oedema (H&E; X40).

## DISCUSSION

This study indicates a higher prevalence of poisoning among males compared to females and revealed that individuals in the teenage, middle-aged, and elderly categories are particularly susceptible. Furthermore, the study highlights that delayed treatment following poison ingestion correlates with an increased fatality rate.

In the present study, the liver emerged as the most frequently affected organ due to its critical role in detoxifying poisons. Substances such as brodifacoum or bromadiolone, found in rat killer poisons, inhibit vitamin K epoxide reductase, leading to coagulopathy and subsequent liver damage. This results in extensive necrosis of liver cells while sparing the bile ducts [5]. In this study, submassive hepatic necrosis was observed in 25.0% of cases, which was

consistent with the 28% reported by Sankappa PS et al., steatosis was found in 37.50% of cases, aligning with the 33% reported by the same study [6]. However, there is a discrepancy regarding acute hepatic necrosis, which was observed in 18.75% of cases in this study compared to 62% in the study by Das S et al., [7].

The kidneys were the second most affected organ. Toxins such as Alpha-Naphthylthiourea (ANTU) or bromethalin, present in rodenticide agents, directly damage the renal tubules, causing acute tubular necrosis. The extent of necrosis can be either diffuse or patchy, depending on the quantity of poison ingested by the individual. Regarding renal findings, acute tubular necrosis was observed in 56.25% of cases in this study, which was consistent with the finding of 44% reported by Das S et al., [7].

In the lungs, substances like zinc phosphide, present in rat killer poison, cause damage to the alveolar capillaries, leading to fluid loss, which results in pulmonary oedema and alveolar haemorrhage [8]. The observation of diffuse alveolar haemorrhage in 37.50% of cases in the present study was consistent with findings from Das S et al., who found 30% and Mothakapalli J et al., who reported a rate of 37.6% [7,9]. Additionally, the incidence of emphysema at 6.25% aligns with the 7.1% reported by Sankappa PS et al., Other organs, including the spleen and brain, displayed intraparenchymal haemorrhage, likely resulting from the indirect anticoagulant effects of the rodenticide [6].

## Limitation(s)

The limitation of this study was that cases where the cause of death was not known could not be included in the study group.

## CONCLUSION(S)

The liver and kidneys are the most commonly affected organs in rat poison cases, as they play key roles in detoxification and excretion, whereas other organ such as lung, spleen, brain and heart are least affected. Early treatment targeting the primary organs involved in rodenticide poison can significantly increase survival rates of affected individual. Additionally, incorporating yoga after treatment can prevent suicidal tendencies and improve mental health issues like depression and anxiety. Yoga techniques like mindfulness meditation and breathing exercises offer cognitive and emotional benefits to the patients.

## Acknowledgement

Rajalakshmi Naryanan Msc Yoga, UGC NET Yoga, YCB3 certified, Vedhakani Yoga Vidyalay for her extreme support for better outcome of this journal.

## REFERENCES

- [1] Abhilash KP, Jayakaran JJ. Rodenticide poisoning: Literature review and management. *Curr Med Issues*. 2019;17:129-33.
- [2] Wondmienieth A, Abera A, Assefa S. Clinical outcomes and socio-demographic profile of rodenticide poisoning patients at a tertiary hospital in Debre Tabor, Ethiopia. *Toxicol Clin J*. 2022;35(2):67-74.
- [3] D'Silva C, Krishna B. Rodenticide poisoning. *Indian J Crit Care Med*. 2019;23(Suppl 4):S272-77.
- [4] Ali H, Tadesse A, Debasu M. An analysis of clinical outcomes in rodenticide poisoning cases in Ethiopia. *J Clin Toxicol*. 2022;47(3):125-31.
- [5] Eason CT, Wickstrom M. Effects of brodifacoum. In: *Vertebrate pesticide toxicology manual (poisons)*. Department of Conservation Technical Series 23. 2023. p. 41. Available from: <https://www.doc.govt.nz/documents/science-and-technical/docts23b.pdf>.
- [6] Sankappa PS, Agrawal V, Rajesh DR. Morphological findings in rat killer poisoning cases: Medicolegal autopsy-based retrospective study. *Int J Sci Res*. 2018;7(12):21-23.
- [7] Das S, Reddy UVUV, Hamide A, Badhe B, Ravichandran M, Murthy AS. Histopathological profile in fatal yellow phosphorous poisoning. *J Forensic Sci*. 2019;64(3):786-90. Doi: 10.1111/1556-4029.13927.
- [8] Husain AN, Kumar V. The lung. In: Kumar V, Abbas AK, Aster JC, editors. *Robbins and Cotran Pathologic Basis of Disease*. 10<sup>th</sup> ed. Philadelphia: Elsevier; 2021. p. 669-749.
- [9] Mothakapalli TJ, Gajjala SR, Marupaka SK, Sharma P, Anuradha S. Histomorphological lung changes and cause of death correlation: An autopsy based study in a tertiary care centre. *J Clin Diagn Res*. 2019;13(6):EC10-EC15.

**PARTICULARS OF CONTRIBUTORS:**

1. Assistant Professor, Department of Pathology, Government Medical College, Krishnagiri, Tamil Nadu, India.
2. Assistant Professor, Department of Pathology, Government Medical College, Krishnagiri, Tamil Nadu, India.
3. Associate Professor, Department of Pathology, Government Medical College, Krishnagiri, Tamil Nadu, India.
4. Professor and Head, Department of Pathology, Government Medical College, Krishnagiri, Tamil Nadu, India.
5. Undergraduate Student, Government Medical College, Krishnagiri, Tamil Nadu, India.
6. Undergraduate Student, Government Medical College, Krishnagiri, Tamil Nadu, India.

**NAME, ADDRESS, E-MAIL ID OF THE CORRESPONDING AUTHOR:**

Dr. V Palaniappan,  
Associate Professor, Department of Pathology, Government Medical College,  
Krishnagiri, Tamil Nadu, India.  
E-mail: rajaln21@gmail.com

**PLAGIARISM CHECKING METHODS:** [\[Jain H et al.\]](#)

- Plagiarism X-checker: Aug 20, 2024
- Manual Googling: Oct 10, 2024
- iThenticate Software: Oct 19, 2024 (6%)

**ETYMOLOGY:** Author Origin**EMENDATIONS:** 7**AUTHOR DECLARATION:**

- Financial or Other Competing Interests: None
- Was Ethics Committee Approval obtained for this study? Yes
- Was informed consent obtained from the subjects involved in the study? Yes
- For any images presented appropriate consent has been obtained from the subjects. Yes

Date of Submission: **Aug 18, 2024**Date of Peer Review: **Sep 17, 2024**Date of Acceptance: **Oct 21, 2024**Date of Publishing: **Jan 01, 2025**