

A Retrospective Descriptive Study on Caesarean Isthmocele: A Delayed and Under-recognised Complication of Caesarean Section

MANEESHA SHRIVASTAVA¹, VARUNA PATHAK², SUSHRUTA SHRIVASTAVA³



ABSTRACT

Introduction: A caesarean scar defect (isthmocele) is an indentation that represents myometrial discontinuity in the anterior uterine wall, with the base communicating with the uterine cavity at the site of a previous caesarean section scar. It has been linked to a variety of gynaecological symptoms, including abnormal uterine bleeding and secondary infertility.

Aim: To describe the demographic characteristics, clinical presentation, management and outcomes in patients with Caesarean Scar Defect (CSD).

Materials and Methods: A retrospective cohort analysis was conducted in the Department of Obstetrics and Gynaecology, Gastrocare Hospital (tertiary care centre), Bhopal, Madhya Pradesh, India, from February 2020 to February 2023. Data were collected from the hospital records of 43 patients who presented with CSD. The recorded variables included demographic details, clinical

presentations, prior treatments, diagnostic interventions, types of surgical procedures performed and patient outcomes. Descriptive statistics, such as means, standard deviations and frequencies, were used to summarise patient characteristics and outcomes. All statistical analyses were performed using Statistical Package for the Social Sciences (SPSS) software version 29.0 software.

Results: The majority of the women were in the age group of 30-40 years. Out of 43 patients, eight presented with Abnormal Uterine Bleeding (AUB), three had secondary infertility, and 32 presented with Caesarean Scar Ectopic Pregnancy (CSEP) and its complications. All cases were managed either by hysteroscopy or laparoscopy, based on the Residual Myometrium Thickness (RMT).

Conclusion: Transvaginal Sonography (TVS) is an effective tool for diagnosing CSD and CSEP. Surgical management can be guided by the RMT as determined by TVS.

Keywords: Caesarean scar defect, Hysteroscopic management, Laparoscopic approach, Methotrexate, Scar ectopic pregnancy

INTRODUCTION

A CSD (isthmocele) is formed due to defective healing of the caesarean scar. It is a wedge-shaped myometrial indentation at the site of a caesarean section. The incidence of this rare condition is increasing, almost paralleling the rise in the rate of caesarean section deliveries [1]. As per the current data, the reported prevalence of scar defects ranges from 24-70% [2-4]. However, this may be just the tip of the iceberg, as the condition may remain asymptomatic in many women. Approximately only 30% will present with symptoms [3].

In the last two decades, there has been increasing awareness of long-term gynaecological problems after caesarean deliveries, such as chronic pelvic pain, dyspareunia, dysmenorrhoea, postmenstrual spotting, menorrhagia, and even infertility [2,3,5], collectively referred to as caesarean scar syndrome [6].

Moreover, long-term obstetric sequelae are also on the rise, manifesting as a spectrum of disorders that begin with CSEP and placenta accreta. Caesarean scar pregnancy and early placenta accreta have been shown to share common histology, which means that this condition can progress to life-threatening obstetric complications of varying degrees, including placenta accreta associated with significant maternal morbidity and even mortality [7].

The wide availability of imaging facilities has facilitated the early diagnosis of this condition and its related complications. Unfortunately, there are still no standardised guidelines for its management. More than 30 treatment regimens have been described for the treatment of CSEP [8]. The Society for Maternal-Foetal Medicine (SMFM), after comparing various treatment

modalities, has published recommendations regarding various diagnostic and treatment modalities for CSEP [9].

Management options range from various termination methods, including systemic or intrasac administration of methotrexate or KCL, to conservative methods like High-intensity Focused Ultrasound (HIFU), embolisation or double balloon catheter, hysteroscopic-guided removal of the CSEP after methotrexate, or laparoscopic excision of the sacs followed by scar repair. These options depend on clinical presentation, available facilities and surgical expertise [9].

So far, no single modality of treatment has been found to be outright superior to the others or applicable to all cases in the absence of gold-standard treatment guidelines for managing this ever-increasing, life-threatening obstetric and distressing gynaecological condition. Therefore, the present study was conducted with the aim of describing the demographic characteristics, clinical presentation, management, and outcomes in patients with CSD.

MATERIALS AND METHODS

This was a retrospective cohort study conducted in the Department of Gynaecology, Gastrocare Hospital (tertiary care centre), Bhopal, Madhya Pradesh, India, from February 2020 to February 2023. Records of these patients were reviewed after obtaining permission from the Institutional head, as well as, the head of the hospital records section. Since it was an observational study requiring the review of records, ethical clearance from the district ethical board was not necessary.

Inclusion criteria: Case records of all women with a TVS-confirmed diagnosis of CSEP or CSD were included in the study.

Exclusion criteria: Case records of patients diagnosed preoperatively as CSEP or CSD but not confirmed intraoperatively were excluded from the study.

Records of 43 patients who presented with scar defects were reviewed. Demographic details, clinical presentations, prior treatments taken for the same condition, the diagnostic interventions used, the surgical procedures performed, and outcomes were recorded and analysed. TVS-based grading of scar defects was also done based on the study conducted by van der Voet LF et al., [3].

STATISTICAL ANALYSIS

Descriptive statistics, including frequencies, means and standard deviations, were calculated for demographic and clinical characteristics, prior treatments, diagnostic findings, and patient outcomes. Statistical analysis was conducted using SPSS software version 29.0.

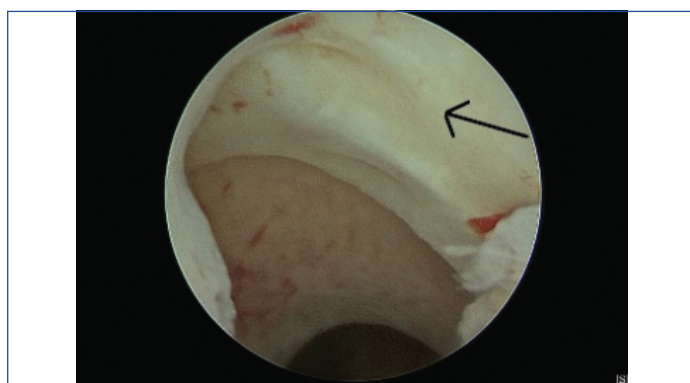
RESULTS

The majority of the women were in the age group of 30-40 years, and most had a history of one caesarean section. Out of the 11 women who presented with gynaecological disorders, six presented with postmenstrual spotting, two had menometrorrhagia, and three were undergoing evaluation for secondary subfertility [Table/Fig-1].

Parameters	n (%)
Age (years)	
20-30	12 (27.9)
31-40	31 (72.1)
Number of previous caesarean	
1	26 (60.5)
≥2	17 (39.5)
Presenting complaints	
Diagnosed caesarean scar pregnancy	06 (13.9)
Complicated scar pregnancy post evacuation	26 (60.5)
Menstrual disorder or AUB	08 (18.6)
Secondary subfertility	03 (6.9)

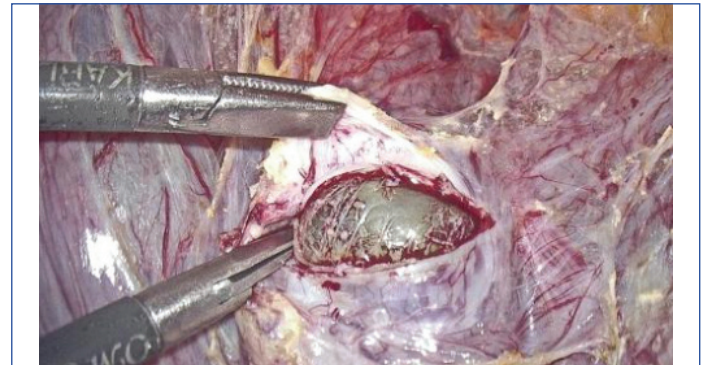[Table/Fig-1]: Demographic details with presenting complaints (N=43).

A total of eight patients with AUB underwent hysteroscopic resection of the distal edge of the scar defect [Table/Fig-2] using a resectoscope, followed by ball cauterisation of the base. At the three-month follow-up, they reported relief from their symptoms. Among the three patients with secondary subfertility who underwent diagnostic hysteroscopy, the uterus was found to be acutely retroverted in two patients. Using hysteroscopic transillumination with Nirgianakis' 'Rendezvous technique', the scar defect was identified by demonstrating a positive 'Halloween sign', and scar repair was performed laparoscopically in a double layer after excision of the fibrotic tissue [10]. Bilateral round ligament plication was performed for the correction of the retroverted uterus (Vervoot technique) [11]. One of these patients achieved successful conception five months after the procedure.



[Table/Fig-2]: Hysteroscopic visualisation of scar niche.

The CSEP is by far the most common sequelae of scar defects. Over this period, six patients were referred to the present study Institute as diagnosed cases of scar pregnancy [Table/Fig-3]. On TVS evaluation, they exhibited myometrial reduction of over 50% (RMT <3 mm). They were managed laparoscopically with excision of the scar pregnancy followed by double-layered closure. Round ligament plication was performed to correct retroversion in two of these cases [11]. One patient had heterotrophic bilateral tubal ectopic pregnancy along with CSEP, for which bilateral salpingectomy was performed alongside laparoscopic excision of CSEP.



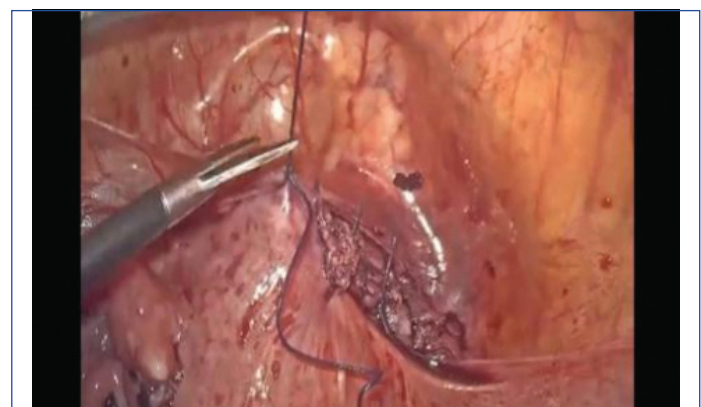
[Table/Fig-3]: Gestational sac in caesarean scar pregnancy.

Out of 43 patients assessed for CSDs using Ultrasound (USG) grading, 17 (39.5%) patients showed a myometrial reduction of more than 50% (RMT <3 mm), while 26 (60.5%) patients exhibited a myometrial reduction of less than 50% (RMT >3 mm) [Table/Fig-4].

Grading of scar defect (USG grading)	n (%)
Myometrial reduction of >50% (RMT <3 mm)	17 (39.5)
Myometrial reduction of <50% (RMT >3 mm)	26 (60.5)

[Table/Fig-4]: TVS-based grading of scar defect (N=43).

A total of 26 patients who had primarily undergone termination of pregnancy elsewhere were referred to the present study Institute with post-termination complications. Of these, 13 patients had taken medical abortion pills, five had received treatment with systemic methotrexate, and eight patients had undergone suction and evacuation. All of them experienced irregular bleeding post-termination of pregnancy. Upon evaluation by transvaginal scan, it was found that chorionic tissue was adherent at the scar site in all cases, with varying degrees of invagination of the chorionic tissue towards the bladder. The treatment plan was tailored based on the myometrial defect evaluated via transvaginal ultrasound and the preoperative radiological appearance of the tissue. Patients with myometrial reduction >50% (or RMT <3 mm) underwent laparoscopic resection of chorionic tissue and repair of the scar [Table/Fig-5]. Of these, two patients conceived and delivered at term by caesarean section. Patients with myometrial reduction <50% (or RMT >3 mm) were managed by hysteroscopic-guided excision of retained products.



[Table/Fig-5]: Repaired scar niche.

Among the 43 patients evaluated, 32 (74.4%) patients were of CSEP and its complications, while 11 (25.6%) patients presented with gynecological problems. Of those managed laparoscopically, 14 (32.6%) patients were from the obstetric group, and 3 (6.9%) patients were from the gynaecological group. Hysteroscopic management was performed in 18 (41.8%) patients from the obstetric group and 8 (18.6%) patients from the gynaecological group [Table/Fig-6].

Mode of management	Obstetrics patients {n=32 (74.4%)}, n (%)	Gynaecology patients {n=11 (25.6%)}, n (%)
Laparoscopic approach	14 (32.6)	03 (6.9)
Hysteroscopic approach	18 (41.8)	08 (18.6)

[Table/Fig-6]: Modes of management (N=43).

DISCUSSION

Increasing caesarean section rates have led to a rise in complications associated with the procedure, such as the formation of CSD. However, Grechukhina O et al., reported a median of two prior caesarean deliveries among patients with the defect in their study [12]. Reported prevalence varies from 24-70% with TVS and from 56-84% with gel/saline instillation sonohysterography (SHG) [2-4]. A literature review indicates that there may be an impairment of fertility in the presence of a defect, with the risk of reduced conception ranging from 4% to 19% [13,14].

Treatment for scar defects is currently indicated only in symptomatic women presenting with secondary infertility, previous scar ectopic pregnancies, recurrent miscarriage, AUB, and bothersome post-menstrual spotting or specific menstrual complaints. However, the case of heterotrophic pregnancy indicates that the presence of CSD alters the uterine and pelvic milieu in a manner that not only attracts the fertilised ovum for abnormal placentation but also likely renders the uterine cavity unwelcoming to the embryo, increasing the chances of tubal ectopic pregnancy. This further emphasises the need to diagnose and repair CSD even in the non pregnant state, thereby saving these women from various gynaecological morbidities, as well as, from the potentially deadly complication of caesarean scar pregnancy [15].

The surgical approach can be stratified based on the RMT. An RMT of at least 3 mm is required for hysteroscopic resection, with a range of 2.5-4 mm reported in the literature to reduce the risk of bladder injury [3,16]. Laparoscopy is the preferred surgical approach for the repair of CSD, particularly if the residual myometrium is less than 3 mm thick and future fertility is desired [17,18].

In addition to laparoscopy, hysteroscopy-guided transvaginal repair is another approach to repair CSD. Luo L et al., reported the results of 42 patients who were managed through a pure transvaginal approach, achieving a clinical success rate for AUB of up to 92.9% (39 of 42 patients) [19]. Hysteroscopy-guided natural orifice repair of CSD could be a feasible alternative to laparoscopy-only procedures, but the authors did not perform this procedure [20].

Despite the recommendations given by the SMFM, treatment for CSEP remains a dilemma, with considerations on whether to offer medical management, choose a surgical approach, or use a combination of both. The use of Methotrexate (MTX) and other medical methods provides a treatment option for stable patients who wish to preserve their reproductive ability. Deb S et al., suggested that medical treatment with methotrexate can be considered for CSEP with a gestational age of less than seven weeks, a Beta Human Chorionic Gonadotropin (β -HCG) level $<5,000$ IU/L, a mass diameter <25 mm, no cardiac activity of the embryo, and the presence of myometrium between the gestational sac and bladder wall [21].

The recommendations by the SMFM Consult Series No. 63 also state that systemic methotrexate alone should not be used to treat CSEP (Grade 1C), and intragestational methotrexate can be used with or

without other treatment modalities (Grade 2C) [9]. Unfortunately, in patients with CSEP who have been treated medically, the gestational mass can take weeks to months to resolve. After local conservative CSEP treatment involving 22 women, one study reported a mean time to resolution of 88 days (range: 26 to 77 days) [22]. Cheng Q et al., compared various surgical modalities for CSEP: Laparoscopy-assisted Operative Hysteroscopy (LAOH), Uterine Artery Embolisation (UAE) followed by LAOH, Dilatation and Curettage (D&C), and UAE followed by D&C, and found that LAOH \pm UAE showed a higher success rate for patients with CSEP [23]. The method of LAOH, originally inspired by Wang CJ et al., aimed to minimise bladder injury and provide a strategy for the minimally invasive management of haemorrhage and scar repair [24].

As a referral centre, the authors have mostly received cases of failed medical management by methotrexate. These were managed hysteroscopically and laparoscopically based on the residual myometrial thickness. It has been observed that in women undergoing medical management, β -HCG takes much longer to return to normal compared to surgical management. This implies that medical management is not a feasible option for women desiring further pregnancies. The SMFM Consult Series also suggests that operative resection (with transvaginal or laparoscopic approaches when possible) or ultrasound-guided uterine aspiration should be considered for the surgical management of CSEP, and that sharp curettage alone should be avoided (Grade 2C) [9].

The incidence of CSD is increasing, along with the resultant long-term sequelae. The surgical techniques of uterine incision closure appear to be the most important determinant in the causation of CSD. In situations where a caesarean scar harbours a defect, a TVS is reliable for diagnosis. However, the question that requires further validation by larger studies is whether all cases of diagnosed CSD, desiring fertility, should undergo surgical correction to restore the uterine milieu.

Limitation(s)

The present is limited by a small sample size, which restricts the generalisability of the study findings. Consequently, the results may not be applicable to larger populations. Larger studies or multicentric meta-analyses are recommended to validate our findings. Additionally, the lack of standardised guidelines and criteria for the management of CSD and CSEP poses a challenge for practitioners in selecting the optimal treatment approach for this increasingly common pathology.

CONCLUSION(S)

The TVS is an effective tool for diagnosing CSD and CSEP. Surgical management can be guided by the RMT as determined by TVS. For cases with RMT greater than 3 mm, hysteroscopic management of CSD appears feasible. However, for RMT less than 3 mm, a laparoscopic approach with revision and repair of the caesarean scar is advisable. Further research is required to determine whether surgical correction of asymptomatic CSD is beneficial for women desiring future pregnancies.

REFERENCES

- [1] Majangara R, Madziyire MG, Verenga C, Manase M. Caesarean section scar ectopic pregnancy - A management conundrum: A case report. *J Med Case Reports*. 2019;13:137. <https://doi.org/10.1186/s13256-019-2069-9>.
- [2] Bij de Vaate AJ, Brölmann HA, van der Voet LF, van der Slikke JW, Veersema S, Huirne JA. Ultrasound evaluation of the cesarean scar: Relation between a defect and postmenstrual spotting. *Ultrasound Obstet Gynecol*. 2011;37:93-99.
- [3] van der Voet LF, Bij de Vaate AM, Veersema S, Brölmann HA, Huirne JA. Long-term complications of caesarean section. The niche in the scar: A prospective cohort study on niche prevalence and its relation to abnormal uterine bleeding. *BJOG*. 2014;121(2):236-44. doi: 10.1111/1471-0528.12542.
- [4] Vikhareva Osser O, Jokubkiene L, Valentin L. Caesarean section scar defects: Agreement between transvaginal sonographic findings with and without saline contrast enhancement. *Ultrasound Obstet Gynecol*. 2010;35:75-83.
- [5] Wang CB, Chiu WW, Lee CY, Sun YL, Lin YH, Tseng CJ. Caesarean scar defect: Correlation between Caesarean section number, defect size, clinical symptoms and uterine position. *Ultrasound Obstet Gynecol*. 2009;34(1):85-89.

- [6] Morris H. Caesarean scar syndrome. *S Afr Med J*. 1996;86(12):1558. PMID: 8998231.
- [7] Timor-Tritsch IE, Monteagudo A, Cali G, Vintzileos A, Viscarello R, Al-Khan A, et al. Cesarean scar pregnancy is a precursor of morbidly adherent placenta. *Ultrasound Obstet Gynecol*. 2014;44(3):346-53. Doi: 10.1002/uog.13426. Epub 2014 Jul 31. PMID: 24890256.
- [8] Torre A, Verspyck E, Hamamah S, Thomassin I, Thornton J, Fauconnier A, et al. Isthmocele: Définition, diagnostic, facteurs de risque, prévention, symptômes, complications, et traitements [Caesarean scar defect: Definition, diagnosis, risk factors, prevention, symptoms, adverse effects, and treatments]. *Gynecol Obstet Fertil Senol*. 2021;49(11):858-68. French. Doi: 10.1016/j.gofs.2021.06.003. Epub 2021 Jun 16. PMID: 34144220
- [9] Miller R, Gyamfi-Bannerman C, Society for Maternal-Fetal Medicine (SMFM), Publications Committee. Society for maternal-fetal medicine consult series# 63: Cesarean scar ectopic pregnancy. *American Journal of Obstetrics and Gynecology*. 2022;227(3):B9-20.
- [10] Nirgianakis K, Oehler R, Mueller M. The Rendez-vous technique for treatment of caesarean scar defects: A novel combined endoscopic approach. *Surg Endosc*. 2016;30(2):770-71.
- [11] Vervoort A, Vissers J, Hehenkamp W, Brölmann H, Huirne J. The effect of laparoscopic resection of large defects in the uterine caesarean scar on symptoms, ultrasound findings and quality of life: A prospective cohort study. *BJOG*. 2018;125(3):317-25.
- [12] Grechukhina O, Deshmukh U, Fan L, Kohari K, Abdel-Razeq S, Bahtiyar MO, et al. Cesarean scar pregnancy, incidence, and recurrence: Five-year experience at a single tertiary care referral center. *Obstet Gynecol*. 2018;132(5):1285-95. Doi: 10.1097/AOG.0000000000002940. PMID: 30303911
- [13] Gurol-Urganci I, Cromwell DA, Mahmood TA, van der Meulen JH, Templeton A. A population-based cohort study of the effect of Caesarean section on subsequent fertility. *Hum Reprod*. 2014;29(6):1320-26.
- [14] Gurol-Urganci I, Bou-Antoun S, Lim CP, Cromwell DA, Mahmood TA, Templeton A, et al. Impact of caesarean section on subsequent fertility: A systematic review and meta-analysis. *Hum Reprod*. 2013;28(7):1943-52.
- [15] Rupa R, Kushwaha S, Venkatesh K. Uterine isthmocele- A frequently overlooked complication of Caesarean section. *Indian J Radiol Imaging*. 2021;31(3):601-04. Doi: 10.1055/s-0041-1736393, PMID:34790304, PMCID:PMC 8590568.
- [16] Raimondo G, Grifone G, Raimondo D, Seracchioli R, Scambia G, Masciullo V. Hysteroscopic treatment of symptomatic caesarean-induced isthmocele: A prospective study. *J Minim Invasive Gynecol*. 2015;22(2):297-301.
- [17] Nezhat C, Falik R, Li A. Surgical management of niche, isthmocele, uteroperitoneal fistula, or caesarean scar defect: A critical rebirth in the medical literature. *Fertil Steril*. 2017;107(1):69-71.
- [18] Donnez O, Donnez J, Orellana R, Dolmans MM. Gynecological and obstetrical outcomes after laparoscopic repair of a caesarean scar defect in a series of 38 women. *Fertil Steril*. 2017;107(1):289-96.e2.
- [19] Luo L, Niu G, Wang Q, Xie HZ, Yao SZ. Vaginal repair of cesarean section scar diverticula. *J Minim Invasive Gynecol*. 2012;19(4):454-58. Doi: 10.1016/j.jmig.2012.03.012. PMID: 22748951.
- [20] Kaya C, Aslan Ö, Tetik M. Hysteroscopy-guided natural orifice repair of Isthmocele. *Gynecol Minim Invasive Ther*. 2022;11(2):116-18. Doi: 10.4103/GMIT.GMIT_13_21. PMID: 35746904; PMCID: PMC9212184.
- [21] Deb S, Clewes J, Hewer C, Raine-Fenning N. The management of Cesarean scar ectopic pregnancy following treatment with methotrexate- A clinical challenge. *Ultrasound Obstet Gynecol*. 2007;30(6):889-92. doi: 10.1002/uog.5149.
- [22] Timor-Tritsch IE, Monteagudo A, Santos R, Tsymbal T, Pineda G, Arslan AA. The diagnosis, treatment, and follow-up of caesarean scar pregnancy. *Am J Obstet Gynecol*. 2012;207(1):44.e01-13. doi: 10.1016/j.ajog.2012.04.018.
- [23] Cheng Q, Tian Q, Chang KK, Yi XF. Comparison of the efficacy and safety of different surgical strategies for patients with type II caesarean scar pregnancy. *Reprod Dev Med*. 2020;4:89-96.
- [24] Wang CJ, Yuen LT, Chao AS, Lee CL, Yen CF, Soong YK. Caesarean scar pregnancy successfully treated by operative hysteroscopy and suction curettage. *BJOG*. 2005;112(6):839-40. Doi: 10.1111/j.1471-0528.2005.00532.x. PMID: 15924549.

PARTICULARS OF CONTRIBUTORS:

1. Consultant, Department of Gynaecology, Gastrocare Hospital, Bhopal, Madhya Pradesh, India.
2. Professor, Department of Obstetrics and Gynaecology, RKMCHRC, Bhopal, Madhya Pradesh, India.
3. Associate Professor, Department of Obstetrics and Gynaecology, RKMCHRC, Bhopal, Madhya Pradesh, India.

NAME, ADDRESS, E-MAIL ID OF THE CORRESPONDING AUTHOR:

Dr. Sushruta Shrivastava,
Associate Professor, Department of Obstetrics and Gynaecology,
RKMCHRC, Bhopal-462042, Madhya Pradesh, India.
E-mail: vikrantsush18@gmail.com

PLAGIARISM CHECKING METHODS: [Jain H et al.]

- Plagiarism X-checker: Jun 30, 2024
- Manual Googling: Dec 05, 2024
- iThenticate Software: Dec 07, 2024 (19%)

ETYMOLOGY: Author Origin

EMENDATIONS: 6

AUTHOR DECLARATION:

- Financial or Other Competing Interests: None
- Was Ethics Committee Approval obtained for this study? No
- Was informed consent obtained from the subjects involved in the study? Yes
- For any images presented appropriate consent has been obtained from the subjects. Yes

Date of Submission: Jun 28, 2024

Date of Peer Review: Jul 25, 2024

Date of Acceptance: Dec 09, 2024

Date of Publishing: Feb 01, 2025