

# Anatomical Variations in the Branches of the Coeliac Trunk

ANTONY SYLVAN D'SOUZA, VIJAYALAKSHMI, HEMALATHA, PUGAZHANDHI, H. MAMATHA

## ABSTRACT

The coeliac trunk is the first ventral branch of the abdominal aorta and it supplies the supracolic organs. Usually, it branches into the left gastric, the common hepatic and the splenic arteries. Although it usually comprises the same basic components, there is a great deal of variation within the coeliac artery branches. The aim of this study was to describe such variations in detail.

This study was conducted on 20 cadavers (3 females and 17 males) which were used during the routine dissection for first year MBBS students in the department of Anatomy, Kasturba Medical College, Manipal, India.

Variations in the branching pattern of the coeliac artery was observed in two cadavers and the rest of the cadavers showed the normal branching pattern.

The vascular patterns are important in the planning and performance of all the upper abdominal surgical procedures. Knowledge on the variations of the coeliac trunk is important for procedures such as liver transplants, for appropriate vascular ligation and anastomosis and also, for surgical and radiological procedures around the head of the pancreas. It is also useful in planning and executing radiological interventions such as celiacography and the chemoembolization of hepatic tumours.

**Key Words:** Coeliac trunk, Common hepatic artery

## INTRODUCTION

The coeliac trunk is the first ventral branch of the abdominal aorta and it arises just below the aortic hiatus, at the level of the T12-L1 vertebra. It is 1.5 to 2 cm long and it passes almost horizontally forwards and divides into the left gastric (LGA), the common hepatic (CHA) and the splenic arteries (SA) [1]. This trifurcation was first described by Haller in 1756. This "Tripos Halleri" was and is still being considered to be the normal appearance of the coeliac trunk (CT) [2].

Each dorsal aorta, even before the stage of its fusion, gives ventral splanchnic branches which supply the gut and its derivatives. Initially, the ventral branches are paired. With the fusion of the dorsal aorta, the ventral branches fuse and form a series of unpaired segmental vessels which run in the dorsal mesentery of the primitive gut and divide into ascending and descending branches. These vessels eventually form dorsal and ventral longitudinal anastomotic channels. With the formation of longitudinal anastomotic channels, numerous ventral splanchnic branches are withdrawn and only three trunks persist as the coeliac artery for the foregut, the superior mesenteric artery to the midgut and as the inferior mesenteric artery to the hindgut [3].

Anatomical variations which involve the visceral arteries are common and also, variations in the branches of the CT have been reported by many authors.

Knowledge on these variations is necessary in order to avoid surgical injury and improper interpretation during imaging.

## MATERIALS AND METHODS

This study was conducted on 20 cadavers (3 females and 17 males) which were used during the routine dissection for the medical undergraduates in the Department of Anatomy, Kasturba

Medical College, Manipal, India. Specimens with topographical derangements were excluded from this study. The dissection was done by retracting the stomach and the small intestines in order to expose the CT and its branches.

## RESULTS

In the present study, the trifurcation of the coeliac trunk into the usual three branches, the left gastric artery, the common hepatic artery and the splenic artery was observed in all the specimens except two.

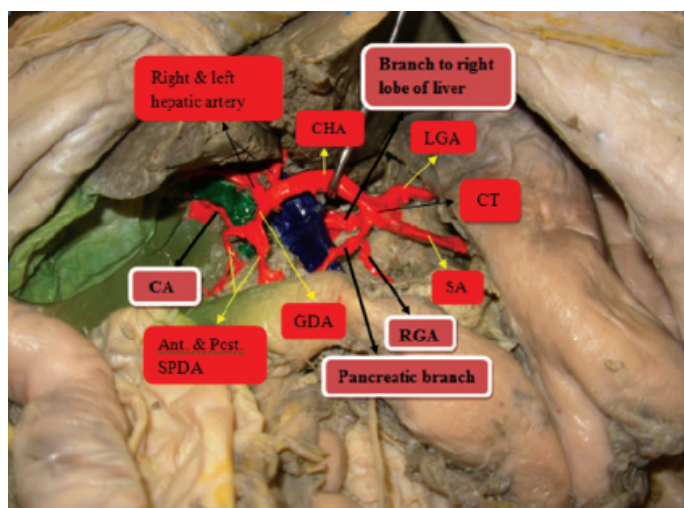
The clinically relevant variations of the coeliac trunk in those two specimens were as follows:

In one specimen [Table/Fig-1], it was observed that the CT, along with its normal branches, that is the LGA, the CHA and the SA, had an additional branch to the right lobe of the liver and also an additional pancreatic branch which supplied the body of the pancreas from which the right gastric artery arose. The CHA, on reaching the upper surface of the first part of the duodenum, gave the gastro-duodenal artery from which the superior pancreaticoduodenal artery arose. The cystic artery is usually a branch of the hepatic arterial system (right hepatic artery), but in this case, it arose from the superior pancreaticoduodenal artery.

In the other male specimen [Table/Fig-2], the CT had a normal branching pattern but there was an additional hepatic branch which was given by the left gastric artery, which entered the left lobe of the liver.

## DISCUSSION

Variations in the branches of the CT are the most commonly reported ones and many authors have reported different variation patterns. Some of them were related to its branches such as in



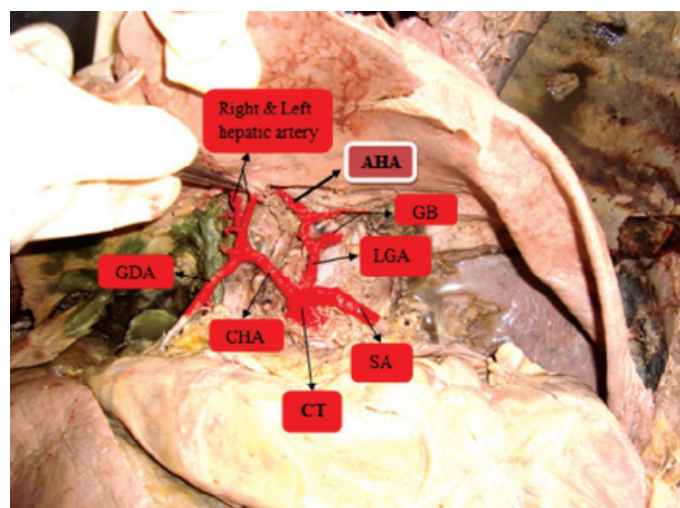
**[Table/Fig-1]:** CT= Coeliac trunk, LGA = Left gastric artery; SA = Splenic artery; CHA = Common hepatic artery; RGA = Right gastric artery; GDA = Gastroduodenal artery, SPDA = Superior pancreatico-duodenal artery, CA = Cystic artery.

our case and other variations were related to its diameter, length or location. Generally, additional branches of the CT other than its normal branches are referred to as collaterals [4]. The patterns of branching of the CT were observed to vary from classical trifurcation to abnormal trifurcation, bifurcation and quadrifurcation of the trunk [5].

Yalcin et al reported that the coeliac trunk gave the following branches, the CHA, the SA and the left middle supra-renal and the common trunk which were constituted by the LGA and the left inferior phrenic artery [6]. Jiji et al., observed that the dorsal pancreatic artery originated from common hepatic artery and directly anastomosed with the middle colic artery, thus forming a Buhler's arcade [7]. Jiji et al., reported one more case where the CT had four arteries- the CHA, the SA, the LGA and the dorsal pancreatic artery. One of the branches of the dorsal pancreatic artery joined with the right gastro-epiploic artery to form the Kirk's arcade [8]. Nayak et al observed that the CT was unusually lengthy and that it took origin from the left antero-lateral surface of the abdominal aorta and had five branches- the left phrenic artery, the LGA, the SA, the CHA and the gastro-duodenal artery [9]. Cicekcibasi et al observed a coelicomesentric trunk which gave the LGA, the CHA, the SA, the left gastro-epiploic, right and the left phrenic arteries [4]. Yildirim et al reported that the middle colic artery originated from the CT [10]. Pamidi et al observed a CT with two main branches- the hepato-splenic trunk and the LGA [11]. Ramasamy et al, observed that the gastro-duodenal artery originated from the CT [12]. According to Mburu et al, the CT was found to be trifurcated in 76 (61.7%), bifurcated in 22 (17.9%) and to give collaterals in 25 (20.3%) cadavers. The dorsal pancreatic artery was the most common collateral and it occurred in 14.8% of the cadavers [13]. Astik observed unusual origins of the left superior suprarenal, the left middle suprarenal, the gastro-duodenal and the right inferior phrenic arteries from the CT in addition to its usual branches [14].

## CONCLUSION

In the present study, two specimens had collateral branches from the CT to the lobes of the liver. So, the variations of the CT must be carefully understood for anastomosing the proper arteries in liver transplant surgeries. Anatomical segmental resection is now being widely practised. It is a safe procedure and it is superior



**[Table/Fig-2]:** CT= Coeliac artery, LGA= Left gastric artery, SA= Splenic artery, CHA= Common hepatic artery, AHA= Accessory hepatic artery, GB= Gastric branch, GDA= Gastroduodenal artery.

to wedge resection in the treatment of metastatic liver cancer. Variations of the branches of the CT are also important during the performance of surgeries of the stomach, duodenum, pancreas and the extrabiliary apparatus.

The vascular variations are usually asymptomatic. They may become important in patients who undergo celiacography for gastrointestinal bleeding and the celiac axis compression syndrome, prior to an operative procedure or transcatheter therapy and for the chemoembolization of pancreatic and liver tumours. Therefore, the careful identification and dissection of the CT branches are important to avoid iatrogenic injuries.

## REFERENCES

- [1] Standring S. Gray's Anatomy, Anatomical basis of Clinical practice, 40th edition. Elsevier Churchill Livingstone: New York, 2008;1073.
- [2] Hemanth K, Garg S, Yadav TD, Sahni D. The hepato-gastro-phrenic trunk and the hepato-spleno-mesentric trunk: A rare anatomic variation. *Tropical Gastroenterology* 2011; 32(1): 56-59
- [3] Datta AK. Essentials of Human Embryology, 5th edition, Current Books International: Kolkata, 2005; 192-93.
- [4] Cicekcibasi AE, Uysal I, Seker M, Tuncer I, Buyukmcu M, Salbacak A. A rare variation of the coeliac trunk. *Annals of Anatomy* 2005; 187: 387-91.
- [5] Chitra R. Clinically relevant variations of the coeliac trunk. *Singapore Med Journal*, 2010; 51(3): 216-19
- [6] Yalcin B, Kocabiylk N, Yazar F, Ozan H, Ozdogmus O. Variations of the branches of the celiac trunk. *Gulhane Tip Dergisi*, 2004; 46(2): 163-65
- [7] Jiji PJ, Nayak SR, D'Costa S, Prabhu L, Pai M, Merin T. A variant of the Buhler's arc which was formed by an unusually long dorsal pancreatic artery. *Bratisl Lek Listy*, 2008; 109(6): 283-84
- [8] Ebenezer D, Jiji PJ, Vadgadnkar R, Prabhu L, Tonse M, Venunadan A. Kirki's arcade: a case report. *International Journal of Anatomical Variation*, 2008; 2: 78-79
- [9] Nayak SR, Prabhu L, Krishnamurthy A, Kumar G, Ramanathan L, Acharya A, et al. Additional branches of the celiac trunk and its clinical significance. *Romanian Journal of Morphology and Embryology* 2008; 49(2): 247-49
- [10] Yildirim M, Celik H, Yildiz Z, Tatar I, Aldur M. The middle colic artery originating from the coeliac trunk. *Folia Morphology*, 2004; 63(3): 363-65
- [11] Pamidi N, Varma S, Vollala VR. Anomalous branching pattern of Celiac trunk. *International Journal of Anatomical Variation* 2008; 1: 8-9
- [12] Ramasamy C. Clinical relevance of a rare variation in the origin of the gastroduodenal artery. *International journal of anatomical variations*, 2009, 2: 69-70
- [13] Mburu, Alexander, Hassan, Bernard. Variations in the branching pattern of the coeliac trunk in a Kenyan population. 2010; 28(1): 199-204.
- [14] Astik R, Dave U. Uncommon branching pattern of the coeliac trunk: origin of seven branches/ 2011; 4: 83-85.

**AUTHOR(S):**

1. Dr. Antony Sylvan D'Souza
2. Dr. Vijayalakshmi
3. Dr. Hemalatha
4. Dr. Pugazhandhi
5. Dr. H. Mamatha

**PARTICULARS OF CONTRIBUTORS:**

1-5. Department of Anatomy, Kasturba Medical College,  
Manipal University, Manipal, India.

**NAME, ADDRESS, E-MAIL ID OF THE CORRESPONDING AUTHOR:**

Dr. H. Mamatha  
Department of Anatomy, Kasturba Medical College,  
Manipal University, Manipal, India.  
E-mail: mamatha2010@yahoo.com

**FINANCIAL OR OTHER COMPETING INTERESTS:**

None.

Date of Submission: **June 29, 2011**  
Date of Peer Review: **Sep 12, 2012**  
Date of Acceptance: **Mar 17, 2012**  
Date of Publishing: **May 01, 2012**