

Thigh Abscess is an Unusual Presentation of the Perforation of Retroperitoneal Appendicitis

LAL S., GUPTA. , GAHARWAR APS. , SHRIVASTAVA G.P.

ABSTRACT

Abscesses of the thigh are rare and, although they can be easily diagnosed, their cause is often obscure. We are presenting here, a case of thigh abscess which resulted from appendicular and colonic perforation. Subcutaneous emphysema of the thigh may be a late manifestation of this process, and it often heralds a poor prognosis because of the associated fulminant sepsis. The presentation and the clinical course of such a patient have been summarized. The underlying pathological abnormality is usually a retroperitoneal perforation of a colorectal neoplasm

or a diverticular disease, whereas its origin from the small bowel or the appendix is distinctly less common. The routes of extension of the infection into the thigh can be either direct, through the subcutaneous tissues or the lumbar triangle or through naturally occurring defects in the abdominal wall. The overall mortality as quoted in the literature is high (53 percent), but the recognition of an abdominal source and an appropriate treatment, combined with the local drainage of the thigh abscess, appears to improve the survival.

Key Words: Retrocaecal appendicitis, ascending colon perforation, subcutaneous emphysema, thigh abscess, faecal fistula.

INTRODUCTION

Appendicitis is a disease which is frequently encountered in the surgical practice. Complications such as perforation, abscess formation and peritonitis are not uncommon. Most of the times, the diagnosis and the treatment are straightforward. The groin and thigh symptoms are common musculoskeletal features; however, only rarely is a fatal abdominal disorder hidden without remarkable abdominal signs [1-3]. We are presenting here, a rare case of subcutaneous emphysema and right thigh abscess which was caused due to retroperitoneal perforation of the appendicular tip and the adjacent ascending colon.

CASE HISTORY

A 40-year-old man presented with history of pain in the right hip and swelling in the thigh with fever since 10 days. There was no significant history of pain in the abdomen. He was diagnosed to have a right gluteal abscess. Incision and drainage was done and the cavity was packed with gauze; then patient was referred to us. His physical examination revealed that he was an acute ill-looking man with a temperature of 39.6 degree C, a blood pressure of 90/50 mmHg and a pulse rate of 116/min. There was an indurated swelling, tenderness and crepitation in his right gluteal region, and in the posterolateral aspect of his thigh, which extended upto his right knee joint. His abdominal examination was normal. His laboratory data showed that his WBC count was 23400/mm³ and that his haemoglobin was 9.8 g/dL. His other blood chemical tests showed normal values. X-ray of the abdomen was normal. A radiograph of his hip showed gas in the soft tissues which were lateral to the hip and the thigh. On the removal of the pack from the thigh, about 1000ml of pus drained out. Multiple incisions were made to drain the thigh abscess and it was irrigated with an antiseptic solution. The muscles of the thigh were normal. [Table/Fig-1].

The discharge was found to contain faeces after 5 days of hospitalization, which led to a high suspicion of gastrointestinal perforation. Barium enema demonstrated a leakage of contrast material from the appendix region down into the thigh [Table/Fig-2].

On doing exploratory laparotomy, a retroperitoneal perforation of the retrocaecal appendicular tip and the adjacent ascending colon was found [Table/Fig -3], without any peritoneal contamination. Appendicectomy with closure of the ascending colonic perforation and side to side ileotransverse anastomosis was done. The thigh abscess cavity was irrigated with an antiseptic solution. The bacterial culture of the abscess revealed *Escherichia coli* and *Bacteroides fragilis*. The patient was treated with broad-spectrum antibiotics. The wound on his right thigh improved with daily antiseptic dressing and he was discharged uneventfully 4 weeks after the surgery.

DISCUSSION

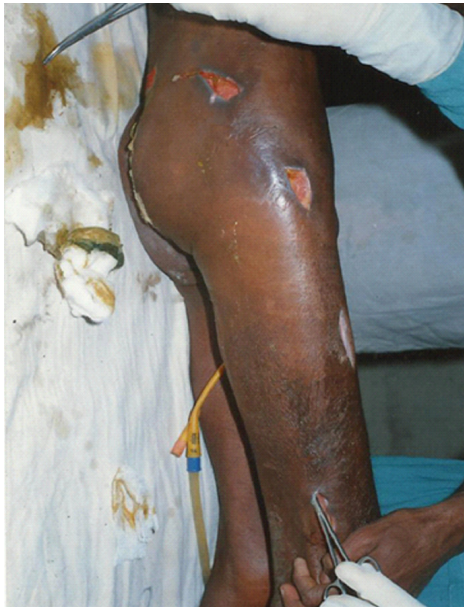Acute appendicitis is a disease which is commonly encountered in the everyday medical practice worldwide, with a lifetime risk of approximately 7% [3]. Proper diagnosis and treatment are essential to prevent morbidity and mortality [4, 5]. Occasionally, serious and sometimes life-threatening complications of perforated appendicitis do occur.

Retroperitoneal and psoas abscesses are the possible complications which follow gastrointestinal perforation. This collection can trickle down by gravity along the fascial planes [1, 2, 6]. Various routes have been identified through which the intraabdominal infection reaches the extra abdominal sites. The routes of entry are summarized in the table below (modified after Mair et al) [7] [Table/Fig-1].

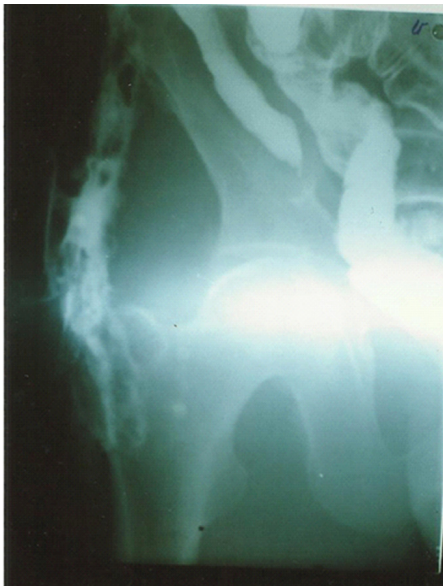A perforated appendix is the commonest cause of bowel-related right thigh emphysema, whereas on the left side, it is usually

Route	Tissue plane
Deep to inguinal ligament	Psoas sheath Femoral sheath Femoral canal
Fibro-osseous canals	Sacrosciatic notch Obturator foramen
From abdominal wall	Subcutaneous
Direct	Penetration of pelvic floor
Generalized Cellulitis	Septicemia/soft tissue Plane

[Table/Fig-1]: Routes of spread of intra abdominal infection to extra abdominal sites.



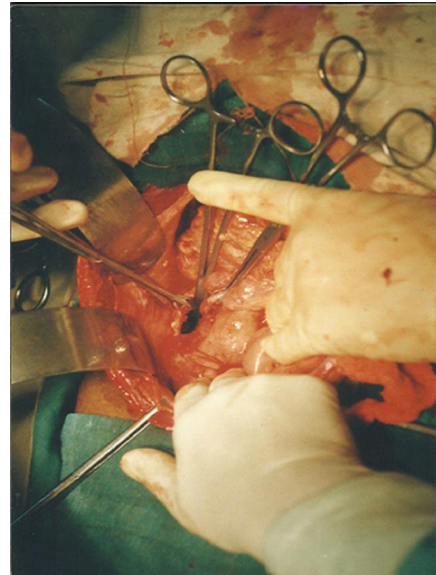
[Table/Fig-2]: Thigh and gluteal abscess was drained by multiple incisions



[Table/Fig-3]: Barium enema showing leakage of contrast material; descending into the right thigh.

caused by diverticular disease or perforated rectal cancer [1, 2, 6]. An overall finding is that gas which is confined to the leg, usually has its origin in the lower intestine.

The retroperitoneal perforation of the appendix and the extension of the infection through the sacrosciatic notch had been reported by EL-Masry NS and Theodorou NA [8]. There are several mechanisms through which the gas can come to be present in the



[Table/Fig-4]: Intraoperative photograph showing a perforation of ascending colon adjacent to the tip of appendix size 1 cm X 1 cm.

legs of patients with bowel perforation [2, 6.] Ishigami K et al [9] demonstrated a retroperitoneal abscess which extended into the abdominal subcutaneous tissue through the lumbar triangle pathway, a known anatomical defect of the lumbar musculature. The retroperitoneum, in most regions, contains loose areolar tissue. A pressure gradient between the bowel lumen and the neighbouring tissue can result in the dissection of air along the pathways between the retroperitoneal space and the leg. The gas in the subcutaneous space may have come from the bowel lumen and from non-clostridial, gas-producing organisms. In our case, the route of extension of the infection into the thigh was through the inferior lumbar triangle.

Retroperitoneal perforated appendicitis can cause atypical and confusing physical findings. Haiart et al [1] reported that unexplained groin and thigh symptoms should lead to the suspicion of intestinal disorders in cases with fever and leukocytosis. The diagnosis, like in our case, is often delayed or missed due to the paucity of localizing signs. It can present as an appendicular abscess, an abdominal wall abscess, a perinephric abscess and right thigh subcutaneous emphysema and abscess. Previous studies have emphasized the diagnostic problems which can lead to a misdiagnosis and delayed treatment and these can result in a high mortality rate [3, 4]. A correct diagnosis can often not be made until surgical exploration or autopsy has been done.

CT scan of the abdomen is considered to be the imaging study with the highest accuracy and efficiency [6]. It can greatly help in the diagnosis, for the drainage of the abscess and for the extension of the involvement. A plain radiograph of the hip and thigh may show gas and a soft tissue swelling. In this case, barium enema demonstrated a leakage of enhanced contrast material from the appendix region down into the thigh [10]. Abdominal ultrasonography is also widely used for the diagnosis of various abdominal pathologies and for the evaluation of their treatment. In some instances, nuclear medicine scans such as a Gallium scan and MRI have been used to make an early diagnosis. The treatment is prompt surgical exploration of the abdomen and drainage of the thigh abscess by making multiple incisions.

CONCLUSION

A search for the presence of intra-abdominal pathologies should be made by doing a thorough clinical and radiological evaluation

in all the patients with unexplained groin and thigh symptoms, with fever and leukocytosis. The clinical picture which has been described in this article is a similar one and it underscores the importance of being aware of alternative patterns that deviate from the usual one. In the presence of a diffuse intermuscular collection of pus and crepitus in the thigh, an intra-abdominal source should be excluded. Imaging modalities including Barium enema, CT and MRI are strongly recommended when the underlying pathology of the thigh subcutaneous emphysema is not clear. However, sometimes an exploratory laparotomy is necessary to reveal the cause. Despite the minimal abdominal signs, the clinical diagnosis must be pursued aggressively.

REFERENCES

- [1] Haiart DC, Stevenson P, Hartley RC. Leg pain: an uncommon presentation of perforated diverticular disease. *J R Coll Surg Edinb* 1989; 34:17-20.
- [2] Nicell P, Tabrisky J, Lindstrom R, Peter M. Thigh emphysema and hip pain which was secondary to a gastrointestinal perforation. *Surgery* 1975; 78:555-9.
- [3] Gurleyik G, Gurleyik E. Age-related clinical features in older patients with acute appendicitis. *Eur J Emerg Med* 2003; 10: 200-3.
- [4] Blomqvist PG., Andersson RE., Granath F, Lambe MP, Ekbohm AR. Mortality after appendectomy in Sweden, 1987-1996. *Ann Surg*, 2001; 233: 455-60.
- [5] Hsieh CH, Wang YC, Yang HR, Chung PK, Jeng LB, Chen RJ. Extensive retroperitoneal and right thigh abscess in a patient with ruptured retrocecal appendicitis: an extremely fulminant form of a common disease. *World J Gastroenterol* 2006; 12: 496-99.
- [6] Edwards JD, Eckhauser FE. Retroperitoneal perforation of the appendix which presented as sub-cutaneous emphysema of the thigh. *Dis Colon Rectum*. 1986; 29(7):456-8.
- [7] Mair WS, McAdam WA, Lee PW, Jepson K, Goligher JC. Carcinoma of the large bowel which presented as a sub-cutaneous abscess of the thigh: a report of 4 cases. *Br J Surg*. 1977 Mar; 64(3):205-9.
- [8] El-Masry NS, Theodorou NA. Retroperitoneal perforation of the appendix which presented as a right thigh abscess. *Int Surg* 2002 Apr-Jun; 87(2):61-4.
- [9] Ishigami K, Khanna G, Samuel I, Dahmouh L, Sato Y. Gasforming abdominal wall abscess : an unusual manifestation of a perforated retroperitoneal appendicitis which extended through the superior lumbar triangle. *Emerg Radiol*, 2004, 10: 207-29.
- [10] Ushiyama T, Nakajima R, Maeda T, Kawasaki T, Matsusue Y. Perforated appendicitis which caused thigh emphysema: A case report. *Journal of Orthopaedic Surgery* 2005; 13(1):93-95.

AUTHOR(S):

1. Dr. Lal S.
2. Dr. Gupta R.
3. Dr. Gaharwar APS
4. Dr. Shrivastava G.P.

PARTICULARS OF CONTRIBUTORS:

1. Assistant Professor.
2. Associate Professor.
3. Professor of surgery.
4. Professor & Head.

Department(s) and institution(s)

Department of Surgery, Shyam Shah
Medical College and Associated SGM Hospital
Rewa, Madhya Pradesh, India.

NAME, ADDRESS, TELEPHONE, E-MAIL ID OF THE CORRESPONDING AUTHOR:

Dr. S. Lal
E- 11 Doctor's colony Medical college campus Rewa,
Madhya Pradesh, India.
Phone - 09301113252
E-mail: slaldr@gmail.com

DECLARATION ON COMPETING INTERESTS:

No competing Interests.

Date of Submission: **Jun 10, 2011**
Date of Peer Review: **Aug 22, 2011**
Date of Acceptance: **Aug 22, 2011**
Date of Publishing: **May 01, 2012**