

# Managing an Uncommon Complication of Pectoralis Major Myocutaneous Flap Surgery: Chest Wall Sinus with Rib Osteomyelitis

JAYESH KHADSE<sup>1</sup>, DEVENDRA YADAV<sup>2</sup>, CHAITANYA MAHAJAN<sup>3</sup>

CC BY-NC-ND

## ABSTRACT

Chest wall sinus with underlying rib osteomyelitis is a rare complication following Pectoralis Major Myocutaneous (PMMC) flap reconstruction in head and neck cancer surgeries. Effective identification and surgical management are essential to prevent recurrence. A 58-year-old male presented with a history of squamous cell carcinoma of the left lower alveolus, initially managed with composite resection and PMMC flap reconstruction. One month postoperatively, the patient presented with a discharging sinus over the anterior chest wall. High-Resolution Computed Tomography (HRCT) revealed rib osteomyelitis. Surgical excision of the sinus tract was performed using methylene blue dye to delineate its extent, followed by rhomboid flap reconstruction. The patient had an uneventful recovery, with healthy flap healing and no recurrence by postoperative day 10. After PMMC flap reconstruction, the anterior chest wall sinus with rib osteomyelitis is an uncommon but significant postoperative complication. Prompt identification, total sinus excision, and rhomboid flap reconstruction guarantee efficient treatment and the best possible outcome.

**Keywords:** Head and neck cancer, Postoperative complication, Squamous cell carcinoma

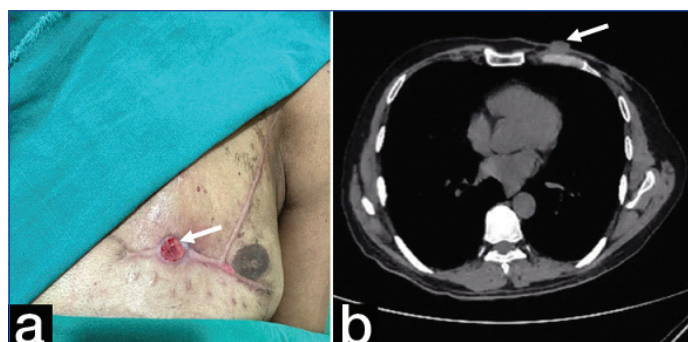
## CASE REPORT

A 58-year-old male presented with a complaint of an ulcer on the left inner cheek for the past two months. The ulcer was associated with localised pain and intolerance to spicy food. The patient had no significant medical history but was a chronic tobacco chewer for the past 15 years. Upon clinical examination, a 0.5×0.5 cm whitish lesion with surrounding erythema was noted along the left lower alveolar arch and gingival mucosa, extending up to the first molar.

Magnetic Resonance Imaging (MRI) of the face revealed an ill-defined, altered signal intensity solid mass lesion involving the left lower alveolar arch, with erosion of the root of the first molar. Under general anaesthesia, the patient underwent full-thickness resection with PMMC flap reconstruction. Histopathological examination confirmed the diagnosis of invasive squamous cell carcinoma of the left lower alveolus. The operative procedure was uneventful, and the patient was discharged with a stable healing wound.

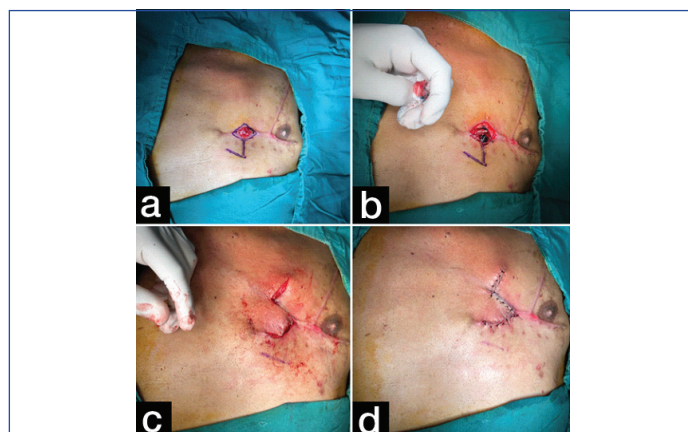
One month after the PMMC flap reconstruction, the patient returned with complaints of pus discharge from a sinus over the left anterior chest wall for the past 15 days [Table/Fig-1a]. He also reported a fever for two days and a cough for one week. Evaluation with HRCT of the thorax revealed an ill-defined soft tissue lesion in the subcutaneous and muscular planes of the left anterior chest wall. This lesion extended up to the underlying costochondral junction and was associated with erosion of the chondral cartilage and the anterior aspect of the third left rib, measuring approximately 23×45 mm. Additionally, another ill-defined soft tissue component measuring 26×14 mm was noted in the subcutaneous plane overlying the costochondral junction and anterior aspect of the fourth left rib, without significant bony erosion. An adjacent lesion measuring 27×11 mm was also noted, with evidence of surrounding fat stranding. Overall, the radiological impression suggested an infective aetiology, likely osteomyelitis of the anterior aspect of the third left rib.

Culture of the infected tissue revealed *Pseudomonas aeruginosa*, which was sensitive to Tobramycin, Meropenem, and Piperacillin/Tazobactam. Consequently, the patient was started on intravenous Tobramycin (80 mg twice daily) preoperatively.



**[Table/Fig-1]:** Sinus over the left anterior chest wall (a) and high-resolution computed tomography of the thorax illustrating ill-defined soft-tissue lesion in the subcutaneous and muscular planes of the anterior chest wall on the left-side (b).

Based on these findings, the patient was planned for surgical excision of the sinus tract with Limberg (rhomboid) flap reconstruction. Intraoperatively, methylene blue dye was injected into the sinus tract to delineate its full extent. Complete excision of the infected sinus tract was performed, followed by rhomboid flap rotation and tension-free coverage of the defect [Table/Fig-2]. The procedure was



**[Table/Fig-2]:** Intraoperative images: Marking the incision (a), injecting methylene blue (b), post-excision sinus tract (c), and post-closure rhomboid flap reconstruction (d).

uneventful, with no intraoperative complications. Histopathological examination of the excised tissue was consistent with an infected sinus tract.

Postoperatively, the patient had a smooth recovery and was discharged with healthy flap healing. There were no signs of recurrence or residual infection upon six-month follow-up.

## DISCUSSION

The PMMC is a widely utilised technique for reconstructive head and neck surgery and anterior chest wall repairs [1]. It has strong vascularity, is easy to harvest, and provides consistent tissue bulk to cover complex abnormalities [1,2]. The PMMC remains the primary choice for reconstruction in most cancer centres across India and other developing nations. However, PMMC flaps are associated with an overall complication rate ranging from 8.9% to 63.0% [3], which includes necrosis, suture line dehiscence, fistula formation, infection, breast deformity in women, costal osteomyelitis, and haematoma [4]. Rib osteomyelitis is extremely rare and accounts for less than 1% of haematogenous osteomyelitis. However, the incidence of anterior chest wall sinus formation in patients with rib osteomyelitis has not been reported.

Among several flaps, rhomboid flaps are popular due to their ability to reconstruct defects in most regions of the body while providing better tension distribution [5]. A chest wall sinus with infection is a common sign of chronic osteomyelitis. These complications are often observed in females and individuals aged over 70 years [6]. However, our patient was a 58-year-old male.

Risk factors for PMMC flap complications include being overweight, having albumin levels below 4 g/dL, using the flap for oral cavity reconstruction after major glossectomy, and having other systemic diseases [4]. Sinus formation can result from various factors, including infection, inadequate blood supply to the flap (ischaemia), or dehiscence of the suture line. The sinus tract develops when the flap's muscle, skin, and subcutaneous tissue do not heal properly, allowing fluid or infection to surface from deeper tissues [4]. This necessitates careful wound closure, monitoring for early indications of complications, optimising flap design, and ensuring adequate blood supply [7,8]. Common symptoms include fever, cough, and left-sided chest pain [9]. Our patient exhibited similar symptoms, with fever for two days and cough for one week.

After surgery, HRCT played a vital role in diagnosing the condition of the anterior chest wall sinus. It remains the preferred method for diagnosing thoracic injuries, offering detailed images of lung tissue, pleura, airways, and the chest wall. HRCT enables a thorough evaluation of injuries such as lung bruising, rib fractures, and bleeding in the chest. Its advantage over other imaging methods, like chest X-rays and lung ultrasounds, is its ability to identify smaller and more subtle injuries [10]. Additionally, when assessing a variety of chest wall lesions, MRI plays a crucial complementary role. It has several benefits, such as flow-sensitive pulse sequences, better differentiation between various tissue types, enhanced contrast between soft tissues, and multiplanar capability. However, compared to MRI, CT has a higher spatial resolution and provides a more accurate representation of cortical bone erosion [11]. In our case, HRCT revealed poorly defined soft tissue in the subcutaneous and muscular layers of the left anterior chest wall, extending to the costochondral junction, with erosion of the cartilage and the anterior aspect of the third rib. These observations suggest an infectious cause, likely osteomyelitis.

Managing chest wall defects presents unique challenges due to their anatomical location and proximity to vital structures. There is no single standardised approach for chest wall reconstruction; instead, the surgical technique should be customised based on the patient's overall health, the defect's size and location, and the availability of local tissue for reconstruction [12]. Common autologous options

include the latissimus dorsi myocutaneous flap, pectoralis major muscle or myocutaneous flap, rectus abdominis flap, free vastus lateralis flap, and greater omentum flap. These flaps provide well-vascularised soft tissue coverage and fill dead spaces, thereby reducing the risk of ongoing infection and sinus formation [12].

Our patient underwent surgical excision, and during the procedure, methylene blue dye was injected into the sinus tract. This traditional yet effective method helps outline the tract's depth and extent. Intraoperative tract staining aids in the complete removal of the sinus and surrounding fibrotic and infected tissue [13]. After excision, the resulting defect was reconstructed using a rhomboid (Limberg) flap. The rhomboid flap is well-suited for small to moderate defects and is designed to place closure lines along the lines of maximal extensibility, ensuring better tension distribution and improved healing, while maintaining adjacent anatomical contours. Elevation of the rhomboid flap is quick, requires no specialised instruments, and is ideal for resource-limited settings, making it an optimal choice in our scenario [14].

For the reconstruction of chest wall defects, the latissimus dorsi, pectoralis major, serratus anterior, and rectus abdominis muscle flaps are important choices. However, these muscle flaps are typically used for large defects. The latissimus and serratus flaps cover the upper thorax, rectus flaps cover the lower thorax, and the pectoralis major flaps cover anterior chest defects, even after thoracotomy [15]. In our case, the chest wall defect created after sinus tract excision was small, so the rhomboid flap was used, which healed well postoperatively. The patient showed no signs of infection or sinus recurrence at follow-up, confirming the effectiveness of timely surgical excision and reconstruction.

## CONCLUSION(S)

In cases of anterior chest wall sinus with underlying rib osteomyelitis, complete surgical excision followed by rhomboid flap reconstruction provides a reliable and effective management approach with no evidence of infection or recurrence. This case highlights the importance of early radiological evaluation, timely surgical intervention, and the effectiveness of simple reconstructive techniques in managing post-PMMC flap complications.

## REFERENCES

- Teo KG, Rozen WM, Acosta R. The pectoralis major myocutaneous flap. *J Reconstr Microsurg*. 2013;29:449-56.
- Bhanja A, D'Souza DS, Roy C, Poddar RN. Reliability of the pectoralis major myocutaneous flap in reconstructive oral cancer surgery in developing countries: Our experience. *Med J Armed Forces India*. 2016;72:S1-S7.
- Jena A, Patnayak R, Sharan R, Reddy SK, Manilal B, Rao LM. Outcomes of pectoralis major myocutaneous flap in female patients for oral cavity defect reconstruction. *J Oral Maxillofac Surg*. 2014;72:222-31.
- Shah JP, Haribhakti V, Loree TR, Sutaria P. Complications of the pectoralis major myocutaneous flap in head and neck reconstruction. *Am J Surg*. 1990;160:352-55.
- Kang AS, Kang KS. Rhomboid flap for large cutaneous trunk defect. *Plast Reconstr Surg Glob Open*. 2020;8:e2932.
- Wang L, Liu Z, He Z, Zhang C. Autologous myocutaneous flap implantation for chronic refractory chest wall sinus with infection: A case report. *J Cardiothorac Surg*. 2023;18:121.
- Leite AK, de Matos LL, Belli M, Kulcsar MA, Cernea CR, Garcia Brandão L, et al. Pectoralis major myocutaneous flap for head and neck reconstruction: Risk factors for fistula formation. *Acta Otorhinolaryngol Ital*. 2014;34(6):389-93.
- Tripathi M, Parshad S, Karwasra RK, Singh V. Pectoralis major myocutaneous flap in head and neck reconstruction: An experience in 100 consecutive cases. *Natl J Maxillofac Surg*. 2015;6(1):37-41. Doi: 10.4103/0975-5950.168225.
- Kamladhar R, Kumar D, Reddy R, Thanmayi A. A case report of unusual anterior chest wall schwannoma. *Int J Sci Res*. 2024;13:1022-23.
- Gongati KC, Pundkar A, Gadkari C. Comparing the diagnostic accuracy of bedside lung ultrasonography and high-resolution computed tomography of the thorax in acute chest trauma patients: A study protocol. *Cureus*. 2025;17:e78292.
- Kuhlman JE, Bouchardy L, Fishman EK, Zerhouni EA. CT and MR imaging evaluation of chest wall disorders. *Radiographics*. 1994;14(3):571-95.
- Zhang K, Wang L, He Z. Pedicled myocutaneous flap transplantation for a large chest wall defect with infection in a 72-year-old female. *Heliyon*. 2024;10:e24038.
- Habib DRS, Jamal NH, Patel K, Wooten CT, Belcher RH. Perioperative outcomes of branchial cleft sinus tract excision in pediatric patients without the use of intraoperative dye. *Ann Otol Rhinol Laryngol*. 2025;134:245-48.

[14] Kang AS, Kang KS. Expanding the scope of rhomboid flap: Large cutaneous defect reconstruction. Case report. Ann Med Surg (Lond). 2021;62:369-72.

[15] Azuma Y. Second surgery for complications of major pulmonary resection—the technique of thoracoplasty with muscle flap. Shanghai Chest. 2023;7:6.

PARTICULARS OF CONTRIBUTORS:

1. Associate Professor, Department of General Surgery, Dr. D. Y. Patil Medical College, Hospital and Research Centre, Dr. D. Y. Patil Vidyapeeth (Deemed to be University), Pimpri, Pune, Maharashtra, India.
2. Junior Resident, Department of General Surgery, Dr. D. Y. Patil Medical College, Hospital and Research Centre, Dr. D. Y. Patil Vidyapeeth (Deemed to be University), Pimpri, Pune, Maharashtra, India.
3. Junior Resident, Department of General Surgery, Dr. D. Y. Patil Medical College, Hospital and Research Centre, Dr. D. Y. Patil Vidyapeeth (Deemed to be University), Pimpri, Pune, Maharashtra, India.

NAME, ADDRESS, E-MAIL ID OF THE CORRESPONDING AUTHOR:  
Dr. Devendra Yadav,  
Junior Resident, Department of General Surgery, Dr. D. Y. Patil Hospital and Research Center, Pimpri-Chinchwad-411018, Maharashtra, India.  
E-mail: devendrayadav11@hotmail.com

PLAGIARISM CHECKING METHODS: [\[Jain H et al.\]](#)  
• Plagiarism X-checker: May 28, 2025  
• Manual Googling: Jun 28, 2025  
• iThenticate Software: Jul 01, 2025 (7%)

ETYMOLOGY: Author Origin  
  
EMENDATIONS: 6

AUTHOR DECLARATION:

• Financial or Other Competing Interests: None

• Was informed consent obtained from the subjects involved in the study? Yes

• For any images presented appropriate consent has been obtained from the subjects. Yes

Date of Submission: [May 26, 2025](#)  
Date of Peer Review: [Jun 16, 2025](#)  
Date of Acceptance: [Jul 03, 2025](#)  
Date of Publishing: [Aug 01, 2025](#)