

# A Computed Tomographic Study on the Anatomic Variations of the Sphenoid Sinus and Its Related Structures in a North Karnataka Population

RUDRESH HIREMATH, SHASHIDHAR SULIGAVI, MANSWINI POL, T.J. ANEGUNDI, K. RUDRAPPA

## ABSTRACT

**Objective:** To evaluate the prevalence of the variations of the sphenoid sinus and their effects on the adjacent neurovascular structures.

**Materials and Methods:** We undertook a prospective study on 400 North Karnataka patients; coronal and axial sections were taken and assessed for various parameters like pneumatization of the pterygoid process, the anterior clinoid process and the greater wing of the sphenoid and protrusion and dehiscence of the internal carotid artery, the optic nerve, the maxillary nerve and the Vidian nerve.

**Results:** Pneumatization of the pterygoid process, the anterior clinoid process and the greater wing of the sphenoid were seen

in 31%, 15%, and 12.75% patients respectively. Protrusion of the internal carotid artery, the optic nerve, the maxillary nerve and the vidian nerve were noticed in 7%, 10%, 12.25% and 31% patients respectively; dehiscence of these structures was encountered in 3%, 5%, 2.75% and 7.75% patients respectively.

**Conclusion:** The sphenoid sinus is a highly variable structure with varying degrees of pneumatization. Knowledge on the anatomic variations of the sphenoid sinus and its related structures is important to avoid the complications of surgery and the unusual symptoms which result from the sphenoid sinus infection.

**Key Words:** Sphenoid sinus variations, CT Paranasal sinuses

## INTRODUCTION

Of all the paranasal sinuses, the sphenoid sinus is deeply seated in the skull and is the most inaccessible to surgeons [1]. It emerges in the fourth month as an evagination from the posterior nasal capsule into the sphenoid bone. The major growth of the sinus occurs from the 3rd to the 5th year of life and by the age of 7 years, the sinus extends posteriorly to the level of the anterior sella [2]. This sinus will obtain the adult configuration by the age of 10 to 12 years. The lack of any sinus pneumatization of the sphenoid bone by the age of 10 years should suggest a possibility of occult sphenoid bone pathology like, chronic anaemia [3].

The average adult sphenoid sinus measures 20mm in height, 23mm in length and 17mm in width. The degree of pneumatization of the sphenoid sinus varies and depending on this, the sinus is classified as non-pneumatized, presellar and sellar [4]. As a result of extensive pneumatization of the sphenoid sinus, vital structures like the internal carotid artery, the optic nerve, the vidian nerve and the maxillary nerve can be protruded into the sinus with or without bony walls [4].

The coronal computed tomography study has become the most requested and the precise imaging technique for demonstrating the par nasal sinuses [5]. The advantage of the coronal sections over the axial ones is that they show the progressively deeper structures as they are encountered by the surgeon during functional endoscopic sinus surgeries [6].

Not only is the knowledge on the anatomic variations of the sphenoid sinus and its related structures important because the

surgical complications may be avoided, but also such knowledge can help in explaining the unusual symptoms that arise from the sphenoid sinus disease [7].

## OBJECTIVES OF STUDY

The aim of this study were to demonstrate the prevalence of the anatomic variations of the sphenoid sinus and its related structures in helping with sphenoid surgeries and in reducing the complications due to it.

## MATERIALS AND METHODS

This was a prospective study on 400 North Karnataka patients which was done between January 2009 and January 2010. The patients were referred from the Otorhinolaryngology and the Ophthalmology departments for the evaluation of head ache and sinusitis. The patients with prior surgery, sinonasal tumours, severe cervical arthropathy and head and neck injuries are excluded from the study. The patients who were younger than 12 years are excluded from the study, as according to Gray, the sphenoid will attain an adult configuration by the age of 10 to 12 years.

In this study, 173 were female patients and 227 were male patients. The age of the patients in this study ranged between 16 and 84 years. The patients underwent both coronal and axial sections. For the coronal images, the patients were positioned prone, with their heads hyper extended and the scanner gantry angles perpendicular to the hard palate. Contiguous 03mm sections were obtained through the par nasal sinuses. In each case, the existence of following variants was looked for: pneumatization of

the pterygoid process, the anterior clinoid process and the greater wing of the sphenoid, protrusion of the internal carotid artery, the optic nerve and the maxillary and the vidian nerves and dehiscence of the walls of the internal carotid artery, the optic nerve and the maxillary and the vidian nerves.

Dehiscence is defined as the absence of the visible bone density which separates the sinus from the course of the concerned structures. The protrusions of the internal carotid artery and the optic nerve were determined by the finding of any degree of protrusion of the structures into the sinus cavity. The presence of air density around the vidian nerve and the maxillary nerve in at least one coronal section was accepted as protrusions of the vidian nerve and the maxillary nerve. Pneumatization of the pterygoid process was recognized if it extended beyond the horizontal plane and crossed the vidian canal. Greater wing sphenoid pneumatization was considered when it extended beyond the vertical plane and crossed the maxillary canal.

## RESULTS

400 patients fulfilled the study criteria. 2 patients had sphenoid agenesis [Table/Fig-5]. The results are shown in the [Table/Fig-1].

## DISCUSSION

### Pneumatization of the Pterygoid Process

In our study, 31% of the patients showed the pneumatized pterygoid process [Table/Fig-2]. Bolger et al., [8] identified pneumatization of the pterygoid process in 43.6% of the patients, whereas Hewaidi GH et al., [7] identified it in 29% of the patients.

Pneumatization of the pterygoid process, when it was present, was an important pathway for access to the central skull base, as for the extended transnasal endoscopic approaches which may reach the pterygoid process through the medial part of the posterior maxillary wall [7].

	Bilateral	Right	Left	Total
<b>PNEUMATIZATION</b>				
Anterior clinoid process	20	19	21	60 (15 %)
Greater wing of sphenoid	25	11	15	51(12.75 %)
Pterygoid process	63	30	31	124 (31 %)
<b>PROTRUSION</b>				
Internal carotid artery	15	08	05	28 (7%)
Optic nerve	16	10	14	40 (10 %)
Maxillary nerve	24	10	15	49(12.25 %)
Vidian nerve	67	28	29	124 (31 %)
<b>DEHISCENCE</b>				
Internal carotid artery	04	04	04	12 (3 %)
Optic nerve	08	06	06	20 (5 %)
Maxillary nerve	02	04	05	11 (2.75 %)
Vidian nerve	12	09	10	31 (7.75 %)

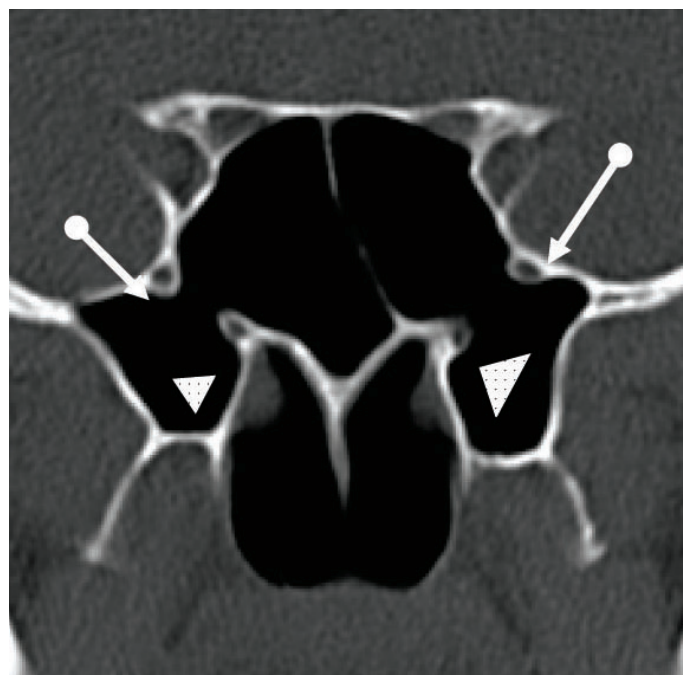
**[Table/Fig-1]:** Results of pneumatization of the anterior clinoid process, the greater wing sphenoid and the pterygoid process with protrusion and dehiscence of adjacent neurovascular structures.

These techniques may further provide routes for the endoscopic repair of cerebrospinal fluid leaks and endoscopic biopsies of the skull base lesions. Pneumatization of the pterygoid process thins the bony floor of the scaphoid fosse to as little as 0.2mm, thus producing an intimate relationship between the sinus and the auditory tube [7].

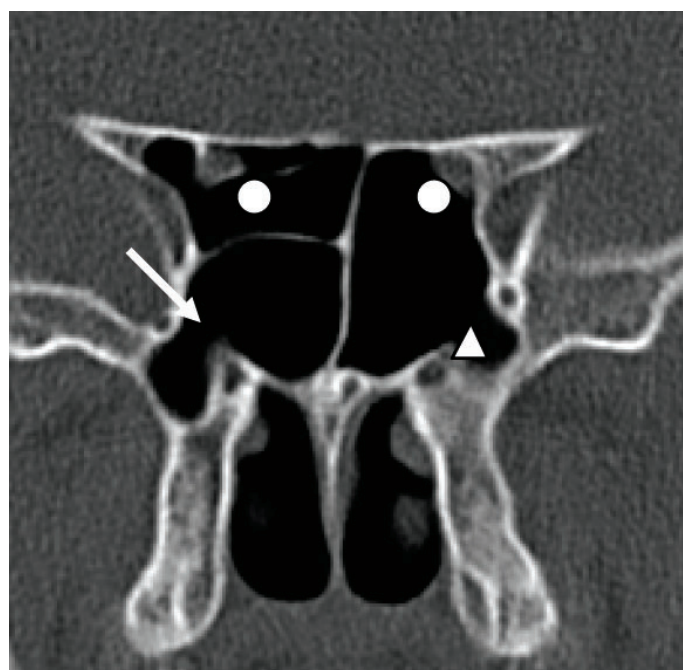
### Pneumatization of the Anterior Clinoid Process

Bolger et al., [8] found pneumatization of the anterior clinoid process in 13% of 202 patients, whereas De Lano et al., [9] found it in 13 of 300 patients (04%). Similarly, Birsen et al., [10] encountered pneumatization of the anterior clinoid process in 24.1% of 260 patients and Hewaidi GH et al. [7] identified it in 15.3% patients. In our study, pneumatization of the anterior clinoid process was encountered in 15.0% [Table/Fig-3] patients, which was similar to the findings of the studies which were conducted by Hewaidi GH et al., [7] and Bolger et al., [8].

Anterior clinoidectomy has become an essential approach for entering the cavernous sinus, to expose the paraclinoid and the



**[Table/Fig-2]:** CT coronal section of sphenoid sinus showing pneumatization of bilateral pterygoid processes with protrusion of vidian (white arrow heads) and maxillary nerves (white arrows).

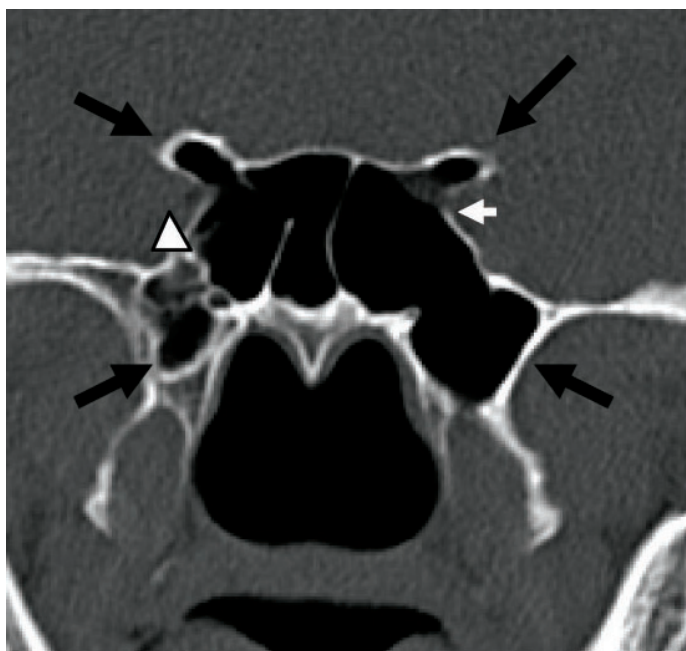


**[Table/Fig-3]:** CT coronal section of sphenoid sinus showing pneumatization of bilateral pterygoid processes with protrusion of left vidian nerve (white arrow heads) and protrusion with dehiscence of right vidian nerve (white arrow). Pneumatization of both anterior clinoid processes is noted with protrusion and dehiscence of internal carotid arteries (white dots) and protrusion of both optic nerves.

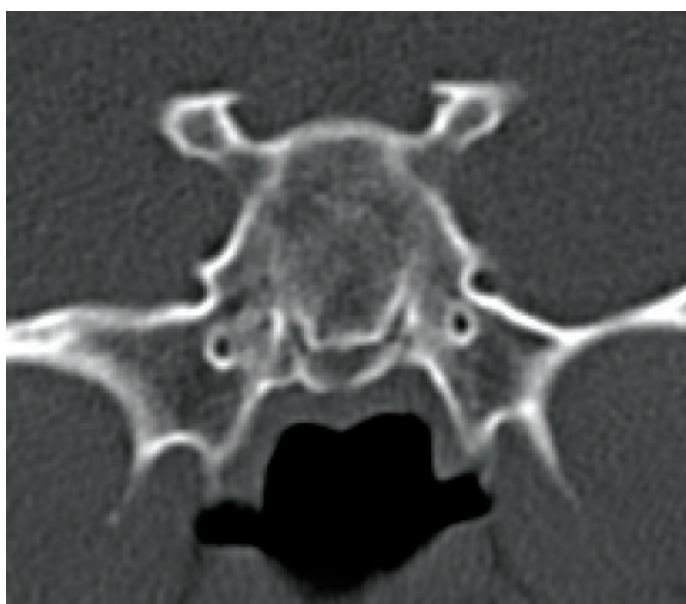
upper basilar artery lesions, and to resect clinoidal meningiomas and giant pituitary adenomas [11]. The frequency of rhinorrhoea after anterior clinoidectomies has been reported to be from 2.7 to 7.0 %, which increases when there is a pneumatized anterior clinoid process [11].

### The Greater Wing of the Sphenoid

Pneumatization of the greater wing of the sphenoid is considered when the extension goes beyond the vertical line and crosses the foramen rotundum. A study which was conducted by Jhon Earwaker [12] showed pneumatization of the greater wing of the sphenoid in 10.7% of the patients, whereas Hewaidi GH et al., [7] identified it in 20.0% patients. Our study showed pneumatization of the greater wing of the sphenoid in 12.75 % of the patients [Table/ Fig-6].



**[Table/Fig-4]:** CT coronal section of sphenoid sinus showing pneumatization of bilateral pterygoid processes & anterior clinoid processes (black arrows) with protrusion of vidian nerves, optic nerves and right maxillary nerve. There is evidence of dehiscence of left optic nerve (white arrow) and right maxillary nerve (white arrow head).



**[Table/Fig-5]:** CT coronal section of sphenoid sinus showing complete non-pneumatized sphenoid sinus.

The pneumatization of the floor of the middle cranial fossa, in the presence of arachnoid granulations, forms 'pit holes'. The enlargement of these pits has been casually implicated in the development of non traumatic cerebrospinal leaks [7].

### The Internal Carotid Artery

Hewaidi GH et al., [7] found protrusion of the internal carotid artery into the sphenoid in 41% of the patients and dehiscence of the artery in 30% patients. As compared to this, in our study, protrusion of the internal carotid artery into the sphenoid was noted in 7% patients and dehiscence of the artery was found in 3% patients [Table/Fig-3]. Sareen et al., [13] studied the sagittal sections of 20 dried skulls and found dehiscence of the internal carotid artery in 05% skulls.

If the surgeon is unaware of the dehiscence or the protrusion of the artery, a fatal haemorrhage may happen [7]. A sphenoid sinus infection may also make a dehiscent or a protruded internal carotid artery vulnerable to damage [7].

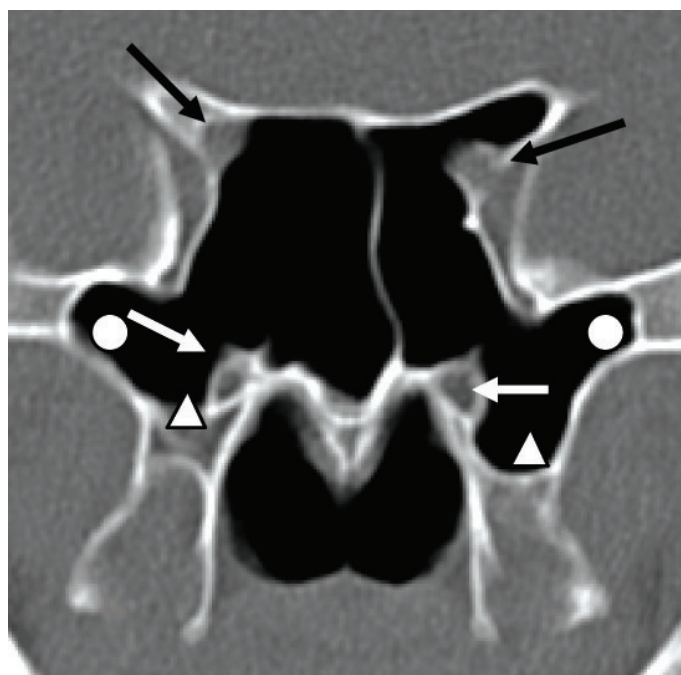
### The Optic Nerve

In this study, protrusion of optic nerve was seen in 10% patients and dehiscence of the optic nerve was seen in 05% patients [Table/Fig-4 & 6]. Hewaidi GH et al., [7] encountered the protrusion of the optic nerve in 35.6% patients and dehiscence of the nerve in 30.6% patients. Various studies which were conducted showed a wide range of protrusion rates (from 8% to 70%) [7].

In case of a protrusion or a dehiscence, an optic nerve injury could occur, either due to a surgical trauma or as a complication of sinusitis, leading to a high risk of blindness [7]. Compression of the optic nerve from the mucocoeles or any other mass can cause ischaemia and a venous congestion of the nerve [7].

### The maxillary nerve

A study which was conducted by Hewaidi GH et al., [7] showed that maxillary nerve protrusion was noted in 24.3% patients and that



**[Table/Fig-6]:** CT coronal section of sphenoid sinus showing pneumatization of bilateral pterygoid processes (white arrow heads), greater wings of sphenoid (white dots) & anterior clinoid processes with protrusion of both vidian nerves (White arrows) & protrusion and dehiscence of optic nerves (Black arrows).

dehiscence of the nerve was noted in 13% patients. Birsan et al. [10] encountered the maxillary nerve protrusion in 30.3% patients and dehiscence in 3.5% patients. In this study, the maxillary nerve protrusion was noted in 12.25% patients and dehiscence of the nerve was noted in 2.75% patients [Table/Fig-2 & 4]. A protruded or dehiscent maxillary nerve is liable to an iatrogenic injury and neuritis of a dehiscent nerve may result from sphenoid sinusitis, which presents as trigeminal neuralgia [7].

### The Vidian Canal

In our study, vidian canal protrusion was seen in 31% patients and dehiscence was seen in 7.75% patients [Table/Fig-2 & 3]. Lang and Keller [14] reported 18% patients with a protruded vidian canal. Hewaidi GH et al., [7] reported that vidian canal protrusion was noted in 27% patients. The knowledge on this helps in improving the results and in decreasing the complications of the endoscopic transsphenoidal and vidian neurectomy surgeries.

### CONCLUSION

The anatomical variations of the sphenoid sinus are common in the North Karnataka population and these are comparable to the findings of other similar studies. The prevalence of the protrusion and the dehiscence of the vidian canal are very high. The internal carotid artery and the optic nerve may not be well protected and they could thus be damaged during endoscopic sphenoid surgeries. The dehiscence of the maxillary nerve was less common. Coronal computed tomography screening should be used in the presurgical evaluation of the patients who are under consideration for endoscopic sphenoid sinus surgeries, to minimize the peroperative neural and the vascular injuries.

### REFERENCES

- [1] Cappabianca P, Cavallo LM, Coloa A, et al. An endoscopic endonasal transsphenoidal approach: an outcome analysis of 100 consecutive procedures. *Minim Invas Neurosurg* 2002; 45:193-200.
- [2] Gray H. Gray's anatomy (40th edn). Edinburgh: *Churchill Livingstone*, September 2008.
- [3] van Alyea O. Nasal sinuses: anatomical and clinical considerations. 2nd ed. Baltimore: *Williams and Wilkins*, 1951.
- [4] Som PM, Shugar JMA, Brandwein MS. Sinonasal Cavities: *Anatomy and Physiology*. 4th edition. Peter M. Som: Mosby, 2003.
- [5] Arsalan H, Aydinlioglu A, Bozkurt M, et al. Anatomic variations of the paranasal sinuses: a CT examination for endoscopic sinus surgeries. *Auris Nasus Larynx* 1997; 26:39-48.
- [6] Zinreich J. The functional anatomy and the computed tomography imaging of the paranasal sinuses. *Am J Med Sci* 1998; 316:2-1.
- [7] Hewaidi GH, Omami GM. The anatomic variation of the sphenoid sinus and its related structures in the Libyan population: a CT scans Study. *Libyan J Med AOP*: 080307:128-33.
- [8] Bolger WE, Butzin CA, Parsons DS. The paranasal sinus bony anatomic variations and the mucosal abnormalities: a CT analysis for endoscopic sinus surgeries. *Laryngoscope* 1991; 101:56-64.
- [9] Delano MC, Fun FY, Zinrich SJ. Relationship of the optic nerve to the posterior paranasal sinuses: a CT anatomic study. *Am J Neuroradiol* 1996; 17:669-75.
- [10] Birsan U, Gulsah B, Yasemin K, et al. The risky anatomic variations of the sphenoid sinus for surgery. *Surg Radil Anat* 2006; 28:195-201.
- [11] Mikami T, Minamida Y, Koyanagi I, Baba T, Houkin K. The anatomical variations in the pneumatization of the anterior clinoid process. *J. Neurosurg*. January 2007; 106: 170-4..
- [12] Earwaker J. The anatomic variants in sinonasal CT. *Radiographics* 1993; 13:381-415.
- [13] Sareen D, Agarwal AK, Kaul JM, et al. A study on the sphenoid sinus anatomy in relation to endoscopic surgeries. *Int. J. Morphol* 2005; 23(3):261-66.
- [14] Lang J, Keller H. The posterior opening of the pterygopalatine fossa and the position of the pterygopalatine ganglion. *Gegenbaurs Morphol Jahrb* 1978; 124:207-14.

#### AUTHOR(S):

1. Dr. Rudresh Hiremath
2. Dr. Shashidhar Suligavi
3. Dr. Manswini Pol
4. Dr. T.J. Aneundi
5. Dr. K. Rudrappa

#### PARTICULARS OF CONTRIBUTORS:

1. Associate Professor, Department of Radio-diagnosis, KVG Medical College & Hospital, Sullia, Dakshina Kannada-574 327, India.
2. Department of Otorhinolaryngology, SN Medical College, Bagalkot-587102, India.
3. Department of Radiodiagnosis, SN Medical College, Bagalkot-587102, India.
4. Department of Radiodiagnosis, SN Medical College, Bagalkot-587102, India.
5. Department of Radiodiagnosis, SN Medical College, Bagalkot-587102, India.

#### NAME, ADDRESS, E-MAIL ID OF THE CORRESPONDING AUTHOR:

Dr. Rudresh Hiremath  
Associate Professor, Department of Radio-diagnosis,  
KVG Medical College & Hospital, Sullia,  
Dakshina Kannada-574 327 Karnataka, India.  
Phone: +91-9945560627  
E-mail: drrudresh76@yahoo.co.in

#### FINANCIAL OR OTHER COMPETING INTERESTS:

None.

Date of Submission: **Feb 23, 2012**

Date of Peer Review: **Apr 25, 2012**

Date of Acceptance: **Aug 04, 2012**

Date of Publishing: **Sep 30, 2012**