

Lymphangioma of the Stomach- A case Report

SAINATH K. ANDOLA, REEMA HARWAL, S M PATIL, SHUBI

ABSTRACT

Lymphangiomas are benign lymphatic tumours that may occur virtually at any anatomic locations. They are particularly uncommon in the abdomen. We are presenting here a case of a 30 years female who presented with a mass per abdomen of 3 months duration, with fever, chills and vomiting. USG and CT reported

this case to be an infected pseudocyst of the pancreas with a differential diagnosis of a hydatid cyst and enteric duplication of the cyst. Excision of the sub-mucosal mass from the posterior wall of the stomach was done and it was histopathologically diagnosed as lymphangioma of the stomach. The case is being presented because of its rarity, with a brief review of the literature.

Key Words: Lymphangioma, Intra-abdominal lymphangioma

INTRODUCTION

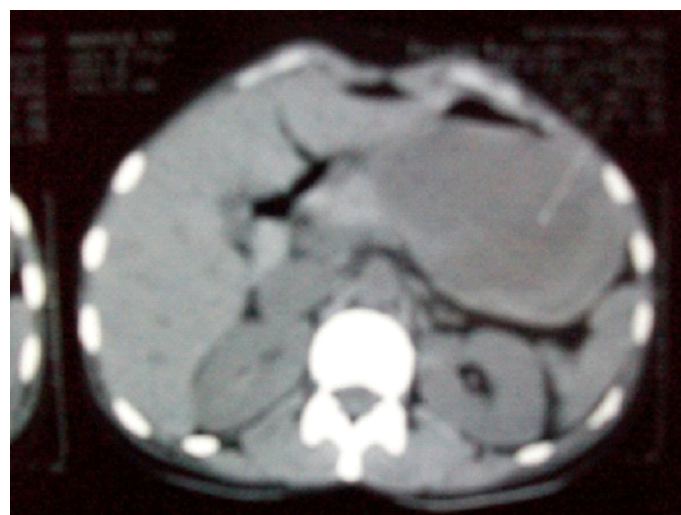Lymphangiomas are benign lesions of vascular origin that show a lymphatic differentiation. They occur at many anatomic locations and they may have a paediatric or an adult clinical presentation. Most (95%) of them occur in the neck and the axillary regions; the remaining 5% are located in the mesentery, retroperitoneum, abdominal viscera, lung and the mediastinum. Among them, lymphangioma of the stomach is very rare [1]. Gastric lymphangiomas have been reported in less than 100 cases worldwide since 1953 [2]. Most of the lymphangiomas of the abdominal cavity originate from the mesentery in which most of the lymphatic channels are included. Therefore, the lymphangiomas of the abdominal cavity were previously called mesenteric cystic lymphangiomas (MCLs) [3]. To date, various locations of MCLs have been reported; where the stomach is an extremely rarely involved organ [1]. The greater and the lesser omentums which are attached to the stomach, are the typical sites of MCLs in the intra-abdominal cavity. Endoscopic ultrasonography has become an indispensable tool for differentiating these gastric tumours. The treatment of these lymphangiomas depends on their sizes, locations and the presence of complications. Excision of the tumour is the treatment of choice, which gives provides excellent prognosis. This case has been presented because of its rarity.

CASE REPORT

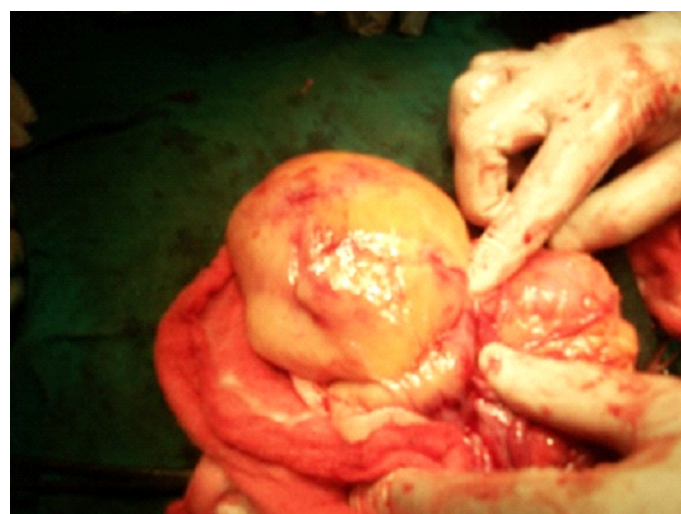
A 30- years old female presented with a mass per abdomen of 3 months duration, which was associated with fever, chills and vomiting. The per abdominal examination revealed a palpable mass in the right epigastrium and in the right lumbar region. The mass measured around 12x10cm and it was painless.

Investigation: The routine CBC, urine examination and LFT were within normal limits. USG of the abdomen revealed a hyperechoic mass which arose from the right hypochondriac region and extended upto the epigastrium, which was suggestive of a benign cystic lesion. CT of the abdomen reported it as an infected pseudocyst of the pancreas with a differential diagnosis of a hydatid cyst/an enteric duplication cyst.

The patient underwent an exploratory laparotomy and the mass, which was sub-mucosal in origin, was excised from the posterior

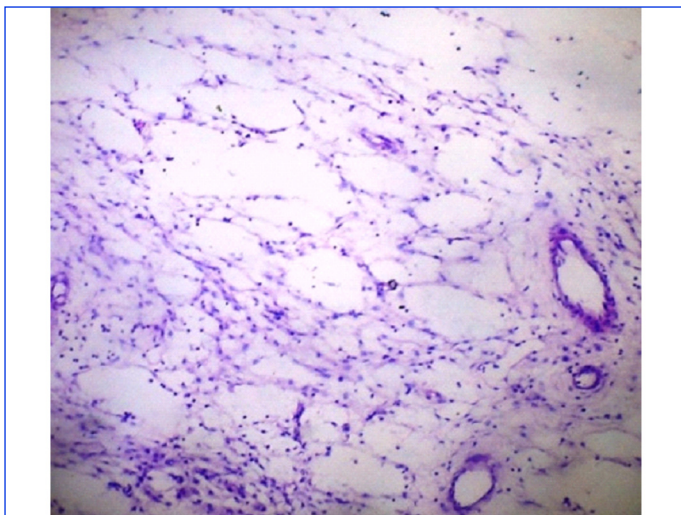


[Table/Fig-1]: CT scan image: Hypodense mass seen in the vicinity of stomach

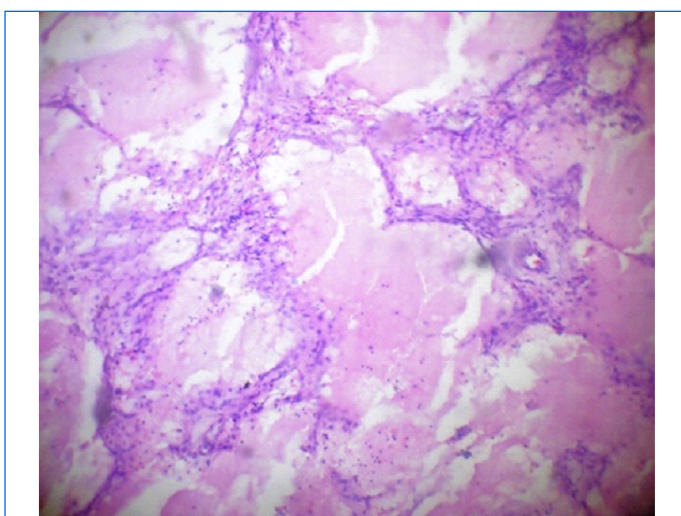


[Table/Fig-2]: Intra-operative: Mass in the lesser curvature of stomach submucosal in location

wall of stomach,. Grossly, an oval mass which measured 10x6x5-cms, with a smooth glistening outer surface, which was yellowish white in colour and mimicked a lipoma, was seen.



[Table/Fig-3]: H & E section showing dilated lymphatic spaces lined by flattened endothelial cells (LPx10)



[Table/Fig-4]: H & E section showing large cystic spaces containing eosinophilic material with scattered lymphoid cells and lymphoid aggregates in between spaces (HP x40)

Cut/Section: gray white to yellowish. Microscopically, dilated lymphatic spaces which were lined by flat endothelial cells, large cystic spaces which contained a pale eosinophilic material with scattered lymphoid cells and lymphoid aggregates in between the spaces were seen. A histological diagnosis of lymphangioma of the stomach made. The post operative course was uneventful.

DISCUSSION

Abdominal cystic lymphangiomas are exceedingly rare benign tumours with an incidence of 1 in 20,000-250,000 cases [4]. Fewer than 100 cases had been reported in the English literature till 2001 [2]. The age at presentation occurs in a bimodal distribution, with greater than 80% patients presenting before the age of 5 and the remainder presenting around the age of 40 years.

The aetiology of cystic lymphangiomas has not been fully understood, but the anomalous development of the lymphatics or inflammation and obstruction of the developed lymphatic channels have both been proposed as the possible mechanisms.

Clinically, most of the cases of cystic lymphangiomas are asymptomatic and they are detected incidentally. Occasionally, they are large enough to cause obstruction or intussusception, depending on the size and location of the mass.

Histologically, these lesions consist of irregularly dilated lymphatic channels which are lined by benign-appearing endothelial cells. Furthermore, these lesions often have a cystic appearance because of a progressive accumulation of fluid. The cyst contents are variable and they may include serous, haemorrhagic, chylous, or mixed fluid. Rarely, calcification may be present.

Although the cystic lymphangiomas of the abdominal cavity were previously considered as mesenteric cysts, the histological difference between the lymphangiomas and the mesenteric cysts was recently established. In contrast to the mesenteric cysts which originate from the mesothelial tissue, lymphangiomas are composed of alternating lymphoid tissue, lymphatic spaces and foam cells. As most of the lymphangiomas of the abdominal cavity originate from the mesentery and form multi-lobular cysts, they are referred to as MCLs.

A cystic lymphangioma is a rare benign submucosal tumour of the stomach which is thought to originate from the sequestered lymphatic tissue, that fails to communicate with the normal lymphatic system. It should be distinguished from other cystic lesions such as mesenteric cysts, enteric duplication cysts and pseudocysts of the pancreas.

The early imaging, detection, and the diagnosis of the abdominal cystic lymphangiomas is important for the definitive treatment of these rare and treatable tumours. Imaging plays an important role in the preoperative evaluation, as lymphangiomas tend to be insinuating and as they may make a complete surgical resection difficult. The most specific method of evaluation which is used for cystic lymphangioma of the stomach is endoscopic ultrasonography [2].

Lymphangiomas can become locally invasive and they often require surgical excision, with recurrence rates of 12% and 53%, when they are completely or partially resected respectively.

A 10% incidence of recurrence has been reported with the incomplete resection of abdominal lymphangiomas [5]. Fayad H studied 13 cases of abdominal lymphangiomas in the paediatric age group and observed nil mortality and no malignant transformations in the follow up cases. Once the cysts were excised, the prognosis was excellent [6].

Knowledge on the imaging and the pathologic spectrum of the abdominal lymphangiomas is necessary when paediatric and adult patients with intra-abdominal cystic masses are evaluated.

REFERENCES

- [1] Kang TW, Lee SJ, Song HJ. Multidetector-Row CT. The findings on gastric cystic lymphangiomas: A case report. *J Korean Radiol Soc* 2008;59:261-4.
- [2] Kim HS et al., Gastric lymphangiomas. *J Korean Med Sci* 2001;16:229-32.
- [3] Kim YB et al., A giant mesenteric cystic lymphangioma originating from the lesser omentum in the abdominal cavity. *J Gastric Cancer* 2011;11(4):243-47.
- [4] Leland et al., Cystic lymphangioma of the lesser curvature of the stomach – A case report. *Radiology Case*. 2011 May; 5(5):31-37.
- [5] Steyaert H, Guitard J, Moscovici J, et al., Abdominal cystic lymphangiomas in children: benign lesions that can have a proliferative course. *J Pediatr Surg* 1996;31:677-80.
- [6] Fayad H. Abdominal cystic lymphangiomas in children. *Annals of Paediatric Surgery* 2009;5:132-36.

AUTHOR(S):

1. Dr. Sainath K. Andola
2. Dr. Reema Harwal
3. Dr. S M Patil
4. Dr. Shubi

PARTICULARS OF CONTRIBUTORS:

1. Professor and HOD, Department of Pathology,
2. Resident, Department of Pathology,
3. Professor, Department of Surgery,
4. Resident Department of Surgery, MR. Medical College, Gulbarga, Karnataka, India.

NAME, ADDRESS, E-MAIL ID OF THE CORRESPONDING AUTHOR:

Dr. Sainath K. Andola
Professor and HOD, Department of Pathology,
MR. Medical College, Sedam Road,
Gulbarga-585105- Karnataka, India.
Phone: 09448881818
E-mail: drskandola@gmail.com

FINANCIAL OR OTHER COMPETING INTERESTS:

None.

Date of Submission: **May 29, 2012**

Date of Peer Review: **Jul 09, 2012**

Date of Acceptance: **Aug 23, 2012**

Date of Publishing: **Sep 30, 2012**