

JOURNAL OF CLINICAL AND DIAGNOSTIC RESEARCH

How to cite this article:

ALIASGHARZADEH A. AN UNUSUAL APPROACH FOR TREATING A THYROID NODULE. Journal of Clinical and Diagnostic Research [serial online] 2008 June [cited: 2008 June 2];3:859-861

Available from

http://www.jcdr.net/back_issues.asp?issn=0973-709x&year=2008&month=June&volume=2&issue=3&page=859-861=203

CASE REPORT

An Unusual Approach For Treating A Thyroid Nodule.

Aliasgharzadeh A

ABSTRACT

Background: Thyroid nodules commonly occur in the general population. They are often discovered incidentally. Fine needle aspiration biopsy (FNAB) is the usual practice for correctly diagnosing these nodules.

Case presentation: The patient was a 24 year female. She presented with a thyroid nodule that was discovered incidentally as an otherwise asymptomatic neck mass. When her husband noticed the nodule, he tightly pressed it between his fingers, because of which haemorrhage and a regional wound resulted. In the 2 months and 1 year follow up, there was no nodule in the thyroid, and only a hyperpigmented scar was left at the previous nodule site.

Conclusion: The unusual and exceptional approach of this patient's husband to the thyroid nodule resulted in its disappearance due to external physical pressure. I have not found any report of this kind in my entire search in the medical literature data bases.

Key Words: Thyroid nodule, Treatment, Crushing

Corresponding Author:

Aliasgharzadeh A.MD

Assistance professor of Medicine Endocrine and Metabolism Research Team - Emamreza Teaching Hospital Faculty of Medicine, Tabriz University of Medical Sciences

Endocrine and Metabolism Section - Emamreza Teaching Hospital - Golgasht Avenue TABRIZ - IRAN

Tel: 04113373944 - 09144024918 Fax: 04113373944

E - Mail : asgharzadeha@tbzmed.ac.ir

Introduction


Thyroid nodules are common clinical findings [1]. The precise method of approach to the nodules is controversial [2],[3]. In most cases, thyroid nodules are found incidentally by patients, relatives, by the physician in general physical exams, or by imaging studies [4]. Recommended and generally accepted by endocrinologists, the approach to thyroid nodules [5] is taking history of the nodule, physical examination and assessment of thyroid function by TSH, and then, fine needle aspiration biopsy (FNAB). The results of this study determine the next step for follow up, whether it is suppressive therapy, or

thyroidectomy. In this case report, an unusual and exceptional approach to treat thyroid nodules, will be presented.

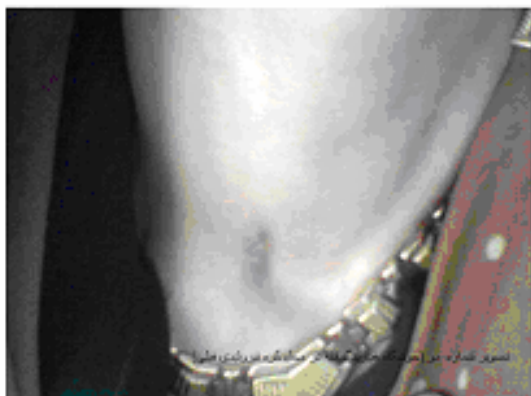Case Presentation

The patient was a 24 year old woman from the rural area of Tabriz – Iran. One month before referral, a swelling on the right side of the anterior neck was found by the patient. A general practitioner (GP) had performed thyroid function tests and a radionuclide scan of the thyroid. Total T4 was 12.5 micorgm/dL, total T3 168 ng/dL, T3RU 25.5% and TSH 0.3 mU/L (patient was on LD contraceptive). Scintigraphy scan [Table/Fig 1] showed a nonhomogenous uptake and an area with low uptake, consistent with a visible lesion. Two days before referral to the endocrine clinic, her husband squeezed the visible nodule between his fingers so tightly, that regional haemorrhage and ulceration resulted. At presentation, the patient was euthyroid. A 2 x 2 cm crusted ulcer was evident on the skin covering the lower portion of the right lobe of the thyroid. I could not palpate the right lobe of the thyroid due to severe pain on the

anterior of the neck at the right. The left lobe of the thyroid was palpable by gentle palpation. Cervical lymph nodes were not palpable. Otherwise, the physical exam was unremarkable. Analgesics and oral antibiotics were prescribed. In the follow up visit 2 months later, the anterior neck ulcer was healed. A hyperpigmented scar was evident in the previous ulcer area. There was no palpable nodule in the thyroid. The patient came for a follow up visit, one year later. The patient was euthyroid. The previous ulcer bed was visible likewise, as a hyperpigmented scar [Table/Fig 2]. There were no other nodules in the thyroid.



Table/Fig 1: Radionuclide scan was showing nonhomogenous uptake and area with low uptake low uptake consistent with visible lesion.



Table/Fig 2: Hyperpigmented scar at the previous nodule site.

Discussion

Usually thyroid nodules present as anterior neck masses. When the masses are found incidentally by patients or their relatives before consulting an expert physician, they can cause extreme anxiety. In most instances, before referral to an endocrinologist [6], multiple visits to the GP, surgeons, and other specialists, are done. Physicians, irrespective

of their knowledge and specialty [7], perform multiple lab studies, imaging such as ultrasound or radionuclide scans, or even occasionally they perform CT scan or MRI [8]. They may do some other studies also [9]. Occasionally, before suitable assessments, patients are directly placed on suppressive therapy [10], intra nodular ethanol injection [11], or surgical or endoscopic thyroidectomy. The logical approach that is applied by endocrinologists, is a history and physical exam, assessment of thyroid function test (TSH, FT4), and FNAB if needed [5]. The approach which was used by this patient's husband was extremely unique and exceptional. He squeezed and crushed the nodule with his fingers such that it disappeared, but a cutaneous ulcer resulted. The author tried to find similar reports in electronic data bases with key words such as thyroid, treatments, case reports, crushing, and nodules. There were no other similar reports.

The method used by this man could have been very dangerous. The pressure could have compressed the airway directly, and suffocation was possible. Also, a large subcutaneous haematoma may have been created, and with airway compression, asphyxia could have threatened the patient's life.

The question which arises is that: can external pressure destroy and ablate the thyroid nodule? Considering that there were no similar reports in the literature or controlled study, we cannot answer the question precisely. Some therapeutic measures that work with internal physical damage can be introduced as solutions. There are reports of spontaneous disappearance of some nodule after FNA (B). However, due to ablation of some nodule in natural history, the effect of FNA in destroying thyroid nodules has been questioned [14]. Ultrasound guided intranodular ethanol injection is a method that may work with physical and chemical injury to the nodule, and results in nodule ablation [15]. Also, laser therapy which can produce intranodular temperature and thermal injury to the nodule, can destroy the nodule [16]. Many thyroid nodules can degenerate spontaneously [17] and result in haemorrhagic cysts. Some of these cysts may not recur after evacuation in FNA.

With regard to these documents, one may conclude that external pressure also can destroy and ablate thyroid nodules. But due to potential hazards of this method, we cannot recommend this as a logical treatment procedure.

References

- [1]. Hegedus, L. Clinical practice. The thyroid nodule. *N Engl J Med* 2004; 351:1764.
- [2]. Castro MR, Gharib H. Continuing controversies in the management of thyroid nodules. *Ann Intern Med.* 2005 Jun 7;142(11):926-31.
- [3]. Costanzo M, Caruso LA, Messina DC, Cavallaro A, Palumbo A, Cannizzaro MA. [Benign thyroid nodule: what is the treatment? Personal experience][Article in Italian] *Ann Ital Chir.* 2005 Jan-Feb;76(1):9-12
- [4]. Furio Pacini.M.D; Leslie J De Groot.MD. Thyroid Nodules. <http://www.thyroidmanager.org/Chapter18/18-nodulesframe.html>
- [5]. Iranian endocrine society. Guideline for diagnosis and management of thyroid nodules. 2004, pages 10-11
- [6]. Ortiz, R, Hupart, KH, DeFesi, CR, Surks, MI. Effect of early referral to an endocrinologist on efficiency and cost of evaluation and development of treatment plan in patients with thyroid nodules. *J Clin Endocrinol Metab* 1998; 83:3803.
- [7]. Clark JR, Freeman JL. Interspecialty and intraspecialty differences in the management of thyroid nodular disease and cancer. *Head Neck.* 2005 Jun;27(6):513-23; discussion 534-4.
- [8]. Radecki, PD, Arger, PH, Arenson, RL et al. Thyroid imaging: comparison of high-resolution real-time ultrasound and computed tomography. *Radiology* 1984; 153:145.
- [9]. Kang, KW, Kim, SK, Kang, HS, et al. Prevalence and risk of cancer of focal thyroid incidentaloma identified by 18F-fluorodeoxyglucose positron emission tomography for metastasis evaluation and cancer screening in healthy subjects. *J Clin Endocrinol Metab* 2003; 88:4100
- [10]. Clark, OH. TSH suppression in the management of thyroid nodules and thyroid cancer. *World J Surg* 1981; 5:39
- [11]. Kim DW, Rho MH, Kim HJ, Kwon JS, Sung YS, Lee SW. Percutaneous ethanol injection for benign cystic thyroid nodules: is aspiration of ethanol-mixed fluid advantageous? *AJNR Am J Neuroradiol.* 2005 Sep;26(8):2122-7
- [12]. Udomsawaengsup S, Navicharern P, Tharavej C, Pungpapong SU. Endoscopic transaxillary thyroid lobectomy: flexible vs rigid laparoscope. *J Med Assoc Thai.* 2004 Sep;87 Suppl 2:S10-4
- [13]. Bahrami A. Spontaneous disappearance of solid thyroid nodules following fine needle aspiration. The 6th congress of Iranian society of Internal Medicine June 1995 Tabriz Iran
- [14]. Gharib H, Mazzaferri EL. Thyroxine suppressive therapy in patients with nodular thyroid disease. *Ann Intern Med.* 1998 Mar 1;128(5):386-94
- [15]. Lee SJ, Ahn IM. Effectiveness of Percutaneous Ethanol Injection Therapy in Benign Nodular and Cystic Thyroid Diseases: Long-term Follow-up Experience. *Endocr J.* 2005 Aug;52(4):455-62
- [16]. Dossing H, Bennedbaek FN, Hegedus L. Effect of ultrasound-guided interstitial laser photocoagulation on benign solitary solid cold thyroid nodules - a randomised study. *Eur J Endocrinol.* 2005 Mar;152(3):341-5
- [17]. Salabe GB. Pathogenesis of thyroid nodules: histological classification? *Biomed Pharmacother.* 2001 Feb;55(1):39-53.