

# Influence of Anabolic Steroid on Tibial Fracture Healing in Rabbits – A Study on Experimental Model

FARIDA AHMAD, SYED MOBASHIR YUNUS, ADIL ASGHAR, N.A.FARUQI

## ABSTRACT

**Introduction:** Anabolic steroid is an established drug for treating catabolic states. The said drug has been shown to restore the lean body mass, to prevent osteoporosis and to correct the impaired immune response, but only few studies have evaluated the effect of the same on fracture healing.

**Methods:** Fracture was produced by an impact device in 24 rabbits which were divided into experimental (I) and control (II) groups of 12 animals each. The experimental groups were further divided into the subgroups IA and IB of equal animals,

which received Nandrolone Decanoate 10 mg/kg intramuscularly, biweekly for 2 weeks and 4 weeks respectively.

**Results and Conclusion:** Radiographs taken on the post fracture day 15 and 40 showed better healing in the Nandrolone Decanoate administered groups as a dense periosteal bone formation and prevention of the local osteoporosis. Histochemical examination of the callus and high serum alkaline phosphatase levels on day 15 and 40 confirmed better mineralization in experimental animals.

**Key Words:** Anabolic steroid, Fracture healing, Tibial fracture model

## INTRODUCTION

Fracture healing is a specialized repair process which involves a well-characterized cascade of events, which includes three major stages i.e. –inflammation reaction, callus formation and callus remodeling [1-4]. The functional recovery after a fracture is often incomplete, especially in the older ages. A catabolic state develops after fracture and following surgery, which contributes to a poor outcome [5-9].

Many patients cannot return to a normal life, which causes a serious impact on their socio-economic status. [10-12]. The patients who sustain fractures, especially those which involve the lower limb, lose body-weight after surgery. This situation leads to generalized weakness, impaired immune response and slower wound and fracture healing [13,14].

Anabolic steroid produces a positive nitrogen and calcium balance, and it is an established drug for treating catabolic states. The effect of an anabolic steroid in the patients who sustain fractures and in animal models, has been evaluated sparingly, although it has been shown to restore the lean body mass, to prevent osteoporosis and to correct the impaired immune response [15,16].

A fracture was created at the mid-diaphysis of the tibia in vivo, for monitoring the bone healing in rabbit. The complete disruption of the cortex and the medulla by an impact force in a pre-drilled tibial shaft is technically simple and is a highly reproducible method for creating a bone defect for normal rabbit fracture healing study. This method does not disturb the normal walking activities of the rabbit [17,18]. Clinically, bridging of the fracture site with cortices or a cortical continuity is the most commonly reported criteria for a radiological assessment of the fracture union at any injury location [19].

In the present study, we examined the differences in the cortical bone healing over a time period of 6 weeks between the control rabbits and the rabbits which received an anabolic steroid. A radiograph was employed for the analysis of the callus mineralization at different time intervals. Decalcified histology was used to describe the callus histopathology features at the tissue level, along with the calcium in the callus, to assess the mineralization activity. Histochemical analysis and serum alkaline phosphatase estimation were done to evaluate the systemic and the local bone turnover.

## MATERIALS AND METHODS

### Experimental Animals

Twenty four albino rabbits (weight: 1.5-2 kg) were obtained from the animal house of J.N. Medical College and they were housed under standard conditions. They were kept on pellet diet (Lipton India limited) and water ad-libitum. The institutional animal ethics committee of the medical college approved the experimental protocol of the study (Registration No. 401/CPCSEA; Dated: 30.03.2010).

### Surgical Protocol And Experimental Design

Rabbits were divided into experimental (I) and control (II) groups of 12 animals each and fractures were produced by using an impact device by the Hiltunen method [20]. The rabbits were anaesthetized by giving thiopentone sodium, 30-50 mg/kg, intraperitoneally. A 1.5 mm Kirschner wire was drilled into the tibial shaft percutaneously, through the tibial tuberosity. The pre-nailed tibial shaft was fractured by an impact device, which resulted in a transverse fracture, which was confirmed by a radiograph. A K-wire was used to get an appropriate alignment and stabilization and to prevent comminution at the fracture site. Group I received injection Nandrolone decanoate (anabolic steroid) intra-muscularly

and the control animals of Group II received equal volumes of the vehicle only. The Group I rabbits were further subdivided into the subgroups IA and IB of six animals each. Subgroup IA animals received Nandrolone Decanoate 10mg/kg intra-muscularly, biweekly for 2 weeks and the subgroup IB rabbits received Nandrolone decanoate 10mg/kg biweekly for 4 weeks.

Radiographs were taken on day 0, day 15 and day 40 to assess the fracture healing. The serum alkaline phosphatase was also estimated on the aforementioned days. After 40 days, the animals were sacrificed and sections were fixed in 10% formalin. Callus was obtained from the fracture sites for doing histochemical and histopathological analyses.

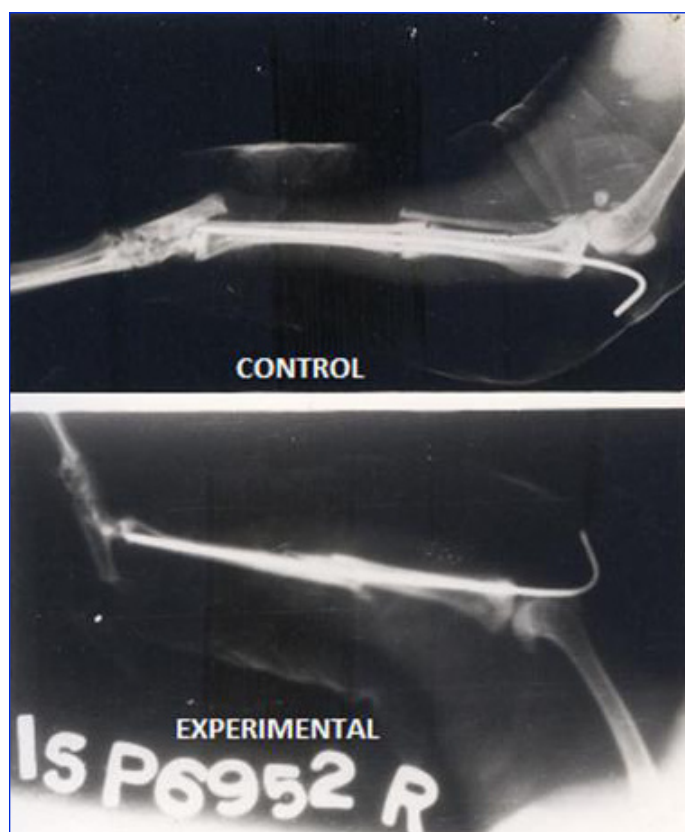
### STATISTICAL ANALYSIS

Student's t-test was used for the parametric data, to compare the control and the experimental groups. A p value of <0.05 was considered to be statistically significant.

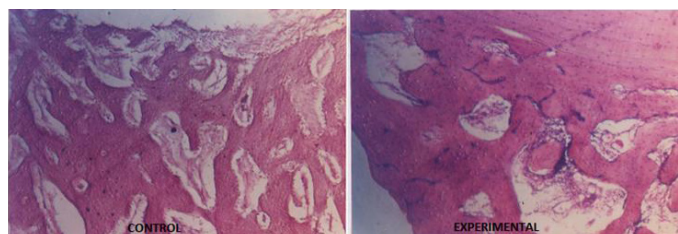
### RESULTS

No significant differences in the body weight or the appetite were noticed throughout the period of the study. The experimental rabbits showed better healing in the form of dense calluses and disappearance of the gap between the fragments by the formation of a cortical as well as a medullary bridging as compared to the control animals, which showed only cortical bridging [Table/Fig-1].

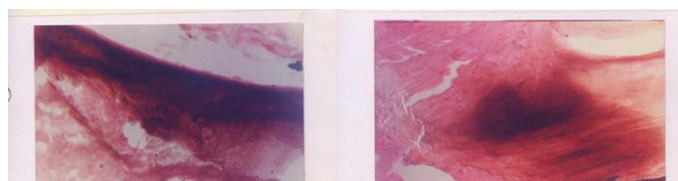Histopathological observation showed very thick trabeculae and the formation of bony lamellae, which led to consolidation in both the groups. But collagen activities and osteoblastic proliferation were significantly better in the experimental group [Table/Fig-2]. A high osteoblastic activity was also confirmed by the histochemical



**[Table/Fig-1]:** Radiographs of fracture tibia in control and experimental animal showing minimum gap and very dense bone formation at fracture site in experimental animal treated with Nandrolone (At 6th week).compared to control



**[Table/Fig-2]:** Section of callus: well developed compact bone formation in experimental animal as compared to control animal. (H&E stain, 50X)



**[Table/Fig-3]:** Section of callus: High alkaline phosphatase activity in experimental animals. (50X) compared to control

Serum alkaline phosphatase ( K.A.U./ 100 ml) , Mean ± SE				
Period	Control	Experimental	% change	P* <0. 001 Highly significant
2 weeks	18.17±0. 75	25. 0± 0.58*	+ 37. 59	
6 weeks	13. 50± 0. 43	19. 83±0. 45*	+ 46. 88	

**[Table/Fig-4]:** Effect of Nandrolone decanoate (10 mg /kg IM) on serum alkaline phosphatase level

Calcium ( mg/g) Mean ± SE				
Period	Control	Experimental	Percent change	P* <0. 01 P** <0. 05 significant
2 weeks	0 .89±0. 01	1. 08± 0. 05*	+ 21. 35	
6 weeks	1 .04± 0.41	1. 21±0. 06**	+ 16. 35	

**[Table/Fig-5]:** Effect of Nandrolone decanoate (10 mg /kg IM) on calcium at fracture site.

Serum alkaline phosphatase ( K.A.U./ 100 ml) , mean ± SE				
Period	2nd week	6th week (40th day)	Percent change	P* <0 . 01 P** <0. 001
Control	18.17±0. 75	10. 62± 0.23*	- 41. 55	
Experimental	25. 0±0. 58	6. 13±0. 87**	-75.48	

**[Table/Fig-6]:** Effect of Nandrolone decanoate (10 mg /kg IM) on calcium at fracture site.

examination of the callus and a high serum alkaline phosphatase level on day15 [Table/Fig-3] in the experimental group [Table/Fig-4]. The mean calcium concentrations in the callus in the control group were 0.89±0.01 and 1.04±0.41 mg/g on days 15 and day 40 respectively.

On the other hand, a significantly better mineralization was observed in the experimental group (1.08±0.05 mg/g on day 15 and 1.21±0.06 mg/g on day 40) [Table/Fig-5]. After 40 days, there was significant fall in the serum alkaline phosphatase level in both the groups, but the level of the fall was significantly higher in the experimental group [Table/Fig-6].

### DISCUSSION

Anabolic steroid is an established drug for the acute catabolic states and the osteoporosis in elderly males. But its role in fracture healing still is inconclusive and no data is available till date for comparison. The Nandrolone decanoate administered groups showed better fracture healing as a dense periosteal bone formation and prevention of the local osteoporosis. This evidence was

reported previously by Yi-Xin He et al., (2011), who had studied the bone healing pattern in mice by inducing ovariectomy-induced osteoporosis [21]. This fact was also confirmed by Aerssens et al., (1993), who observed the affect of oestrogen and progesterone indirectly by performing ovariectomies in female rats [22]. Several other scientists also advocated that anabolic steroids produced a better bone mass density and that they prevented osteoporosis [23-26].

The osteoblastic activities were very high in the Nandrolone administered animals than in the control group. The osteoblastic activity was assessed by measuring the serum alkaline phosphatase levels and locally in the callus by measuring the alkaline phosphatase activity, by Nilsson and Granstrom (1987). The high levels of serum alkaline phosphatase and the callus alkaline phosphatase activity in the experimental group in the present study demonstrated a better fracture healing than that in the control group [27].

Frankle and Borrelli (1990) reported high levels of calcium in the healing callus with the use of anabolic steroids. We observed that the Nandrolone treated animals achieved higher levels of callus calcium than the control group, which showed a better bone mineralization activity [28].

Anabolic steroid on plasma hydroxyproline (HOP) was investigated in young male rabbits, following operative fractures of the radius. The plasma HOP was found to increase during the fracture healing in the control animals, particularly in the first week and during the callus remodelling. The animals which were treated with the anabolic steroid did not present the initial rise, but they presented a sustained increase during the callus remodelling [29]. The administration of an anabolic steroid (17 $\alpha$ -methyl-17 $\beta$ -hydroxy-androsta-1,4-dien-3-one) in rats improved the tensile strength of the experimental granulation tissue and of the healing skin wounds on the 12th postoperative day. This, however, occurred only in the undernourished animals which showed a retarded development of the connective tissue. This difference was also reflected in the collagen content of the granulation tissue. The treatment caused a slight increase in the tensile strength in all the feeding groups on the second postoperative day [30]. In a prospective randomized trial, a protein-rich liquid supplementation in combination with an anabolic steroid, which was given for 6 months to lean elderly women with femoral neck fractures, was shown to positively affect the lean body mass, the ADL and the quality of life (EQ-5D). The fracture healing complications had a negative impact on the body weight, the lean body mass and the quality of life [31].

A study was undertaken to evaluate the effect of an extract of *Cissus Quadrangularis* Linn (CQ) which contained high amounts of Vitamin C, carotene A, anabolic steroidal substances and calcium, on the healing process of experimentally fractured radius-ulnas of dogs. The CQ treated animals revealed a faster initiation of the healing process than the control animals on radiological and histopathological examinations. The treated group also revealed a decrease in the serum calcium levels to a greater extent than the control group. The healing was almost complete on the 21<sup>st</sup> day of the fracture in the treated animals and it remained incomplete in the control animals [32].

Anabolic steroids, especially oxandrolone, have been successfully used in the trauma and the burn patient population to decrease

the lean mass loss in the acute phase of the injury, as well as, to more rapidly restore the lost lean mass in the recovery phase. Several studies have demonstrated an increase in the healing of chronic wounds. However, significant lean mass gains were also present [33]. Falanga et al., [34] reported a stimulation of the collagen synthesis with the anabolic steroid, stanazol. Erlich et al., [35] reported a 10-fold increase in the messenger RNA for collagen synthesis in a human fibroblast culture with oxandrolone. Tenenbaum et al., [36] reported an increased synthesis of bone, collagen, matrix, and epidermis in a wound of the oral cavity which was stimulated with oxandrolone. A histological analysis in our study also revealed more densely packed collagen with higher number of fibroblasts and mononuclear cells. Anabolic steroids have also been shown to trigger the release of the transforming growth factor beta by fibroblasts, which stimulates the bone formation in the granulation tissues [37].

## CONCLUSION

From the above facts, we can conclude that anabolic steroids produce a better fracture healing by exaggerating the periosteal bone formation and by achieving a high osteoblastic activity and a better mineralization of the callus. They also seem to exert mild inhibition of the bone resorption without affecting or even stimulating the bone formation. Thus, anabolic steroids will definitely improve the fracture healing outcome and reduce the morbidity and the negative socio-economic impact. This was an initial study which was done to test the effect of Nandrolone decanoate on fracture healing, which showed positive results. We intend to do future evaluation with multiple doses and for a longer duration of time.

## REFERENCES

- [1] Ferguson C, Alpern E, Miclau T, Helms JA. Does adult fracture repair recapitulate embryonic skeletal formation? *Mech Dev.* 1999; 87:57-66.
- [2] Einhorn TA. The cell and molecular biology of fracture healing. *Clin Orthop Relat Res.* 1998:S7-S21.
- [3] Gerstenfeld LC, Cho TJ, Kon T, Aizawa T, Tsay A, Fitch J, et al. Impaired fracture healing in the absence of TNF-alpha signaling: the role of TNF-alpha in endochondral cartilage resorption. *J Bone Miner Res.* 2003; 18:1584-92.
- [4] Einhorn TA. The science of fracture healing. *J Orthop Trauma.* 2005; 19:S4-6.
- [5] Hedström M, Sääf M, Dalén N. Low IGF-I levels in hip fracture patients: a comparison of 20 coxarthrotic and 23 hip fracture patients. *Acta Orthop Scand.* 1999;70:145-48.
- [6] Patterson B, Cornell C, Carbone B, Levine B, Chapman D. Protein depletion and metabolic stress in elderly patients who have a fracture of the hip. *J Bone Joint Surg Am.* 1992; 74-A: 251-60.
- [7] Hillier S, Cooper C, Kellingray S, Russell, G; Hughes, H; Coggon, D; Fluoride in drinking water and risk of hip fracture in the UK: a case control study. *Lancet.* 2000;22:265-69.
- [8] Thibaud D, Burckhardt P, Costanza M, Importance of albumin, 25(OH)-vitamin D and IGFBP-3 as risk factors in elderly women and men with hip fracture. *Osteoporosis Int.* 1997; 7:457-62.
- [9] Delmi M, Rapin CH, Bengoa JM, Delmas PD, Vasey H, Bonjour JP; Dietary supplementation in elderly patients with fractured neck of the femur. *Lancet.* 1990; 335:1013-16.
- [10] Sernbo I, Johnell O. Consequences of a hip fracture: a prospective study over 1 year. *Osteoporosis Int.* 1993; 3:148-53.
- [11] Hedström M, Gröndal L, Örtengren R, Ahl T. Serum albumin and deep infection in femoral neck fractures: a study of 437 cases followed for one year. *Int Orthop.* 1998; 22:182-84.
- [12] Fox KM, Magaziner J, Hawkes WG, Yu-Yahiro, J, Hebel, JR, et al. Loss of bone density and lean body mass after hip fracture. *Osteoporosis Int.* 2000;11:31-35.
- [13] Kay SP, Moreland JR, Schmitter E. Nutritional status and wound healing in lower extremity amputation. *Clin Orthop.* 1987; 217:253-56.



- [14] Puskarich CL, Nelson CL, Nusbickel FR, Stroope HF. The use of two nutritional indicators in identifying long bone fracture patients who do and do not develop infections. *J Orthop Res*. 1990; 8:799-803.
- [15] Berger JR, Pall L, Hall CD, Simpson DM, Berry PS, Dudley R; Oxandrolone in AIDS-wasting myopathy. *AIDS*. 1996; 10:1657-62.
- [16] Ferreira IM, Verreschi IT, Nery LE, Goldstein RS, Zamel N, Brooks D; et al. The influence of 6 months of oral anabolic steroids on body mass and respiratory muscles in undernourished COPD patients. *Chest*. 1998; 114:19-28.
- [17] Monfoulet L, Rabier B, Chassande O, Fricain JC. Drilled hole defects in mouse femur as models of intramembranous cortical and cancellous bone regeneration. *Calcif Tissue Int*. 2010; 86:72-81.
- [18] Campbell TM, Wong WT, Mackie EJ. Establishment of a model of cortical bone repair in mice. *Calcif Tissue Int*. 2003; 73:49-55.
- [19] Corrales LA, Morshed S, Bhandari M, Miclau III T. Variability in the assessment of fracture-healing in orthopaedic trauma studies. *J Bone Joint Surg Am*. 2008; 90:1862-68.
- [20] Hiltunen A, Vuorio E, Aro HT. A standardized experimental fracture in the mouse tibia. *J orthop Res*. 1993; 11 (2): 305-12.
- [21] Yi-Xin He ,Ge Zhang,Xiao-Hua Pan, Zhong Liu, Li-zhen Zheng, Chun-Wai Chan, et al. Impaired bone healing pattern in mice with ovariectomy-induced osteoporosis: A drill-hole defect model. *Bone*. 2011;48 (6):1388-1400.
- [22] Aerssens J, Van Audekercke R, Geusens P, Schot LPC, Osman AA, Dequeker J. Mechanical properties, bone mineral content, and bone composition (collagen, osteocalcin, IGF-I) of the rat femur: influence of ovariectomy and nandrolon decanoate (anabolic steroid) treatment. *Calcif Tissue Int*. 1993;53 (4): 269-77.
- [23] Carrazzo M. Evaluation of the effect of anabolic steroids, calcitonin and 25-hydroxycholecalciferol on the spongy bone of rats. *Rev Rhum Mal Osteoarthritis*. 1985;32 (1):17-19.
- [24] Erdtsieck RJ, Pols HA, van Kuijk C, Birkenhäger-Frenkel DH, Zeelenberg J, Kooy PP et al. Course of bone mass during and after hormonal replacement therapy with and without addition of nandrolone decanoate. *J Bone Miner Res*. 1994; 9 (2):277-83.
- [25] Hassanger C Christiansen . Epidemiology, biochemistry and some results with treatment of postmenopausal osteoporosis. *Wien Med Wochenshr*. 1993;143 (14-15):389-99.
- [26] Johansen JS, et. al. Treatment of postmenopausal osteoporosis: is the anabolic-steroid nandrolone decanoate a candidate? *Bone Miner*. 1989;6 (1): 77-86.
- [27] Granstrom G and Nilsson LP. Experimental mandibular fracture: Studies on bone repair and remodellation. *Scand J. Plast Reconstr Surg Hand Surg*. 1987; 21 (2):159-65.
- [28] Frankle M and Borrelli J. The effects of testosterone propionate and methenolone enanthate on the healing of humeral osteomies in the Wistar Rat. *J. Invest. Surg*. 1990;3 (2):93-113.
- [29] Lyritis G, Papadopoulou Z, Nikiforidis P, Batrinos M, Varonos D . Effect of cortisone and an anabolic steroid upon plasma hydroxyproline during fracture healing in rabbits. *Acta Orthop Scand*. 1975 Apr; 46(1):25-30.
- [30] J. Viljanto, H. Isomäki and E. Kulonen. Effect of an anabolic steroid on the tensile strength of granulation tissue in various nutritional states. *Acta Endocrinol*. November. 1, 1962; 41: 395-99.
- [31] Tidermark J. Quality of life and femoral neck fractures. *Acta Orthop Scand Suppl*. 2003 Apr;74(309):1-42.
- [32] Deka DK, Lahon LC, Saikia J, Mukit A. Effect of clssus quadrangular/s in accelerating healing process of experimentally fractured radius-ulna of dog: a preliminary study. *Indian journal of pharmacology*. 1994; 26: 44 – 45.
- [33] Robert H. Demling. The Role of Anabolic Hormones for Wound Healing in Catabolic States. *Journal of Burns and wounds Vol. 4*:46-62.
- [34] Falanga V, Greenberg A, Zhou L. Stimulation of collagen synthesis by the anabolic steroid stanazol. *J Invest Dermatol*. 1998;11:1193-97.
- [35] Erlich P. The influence of the anabolic steroid oxandrolone upon the expression of procollagen types I and II MRNA in human fibroblasts cultured in collagen or plastic. *Wounds*. 2001;13:66-72.
- [36] Tennenbaum R, Shkear G. Effect of the anabolic steroid oxandrolone on wound healing. *Oral Surg*.1970;30:834-35.
- [37] Demling RH. Oxandrolone, an anabolic steroid, enhances the healing of a cutaneous wound in the rat. *Wound Repair Regen*. 2000;8:97-102.

**AUTHOR(S):**

1. Dr. Farida Ahmad
2. Dr. Syed Mobashir Yunus
3. Dr. Adil Asghar
4. Prof. N.A. Faruqi

**PARTICULARS OF CONTRIBUTORS:**

1. Associate Professor, Department of Pharmacology, JN Medical College, Aligarh, Uttar Pradesh, India.
2. Associate Professor, Department of Anatomy, JN Medical College, Aligarh, Uttar Pradesh, India.
3. Assistant Profrssor, Department of Anatomy, HIMSR, Jamia Hamdard New Delhi, India.
4. Professor, Department of Anatomy, JN Medical College, Aligarh, Uttar Pradesh, India.

**NAME, ADDRESS, E-MAIL ID OF THE CORRESPONDING AUTHOR:**

Dr. Farida Ahmad,  
Associate Professor, Department of Pharmacology,  
J.N. Medical College, A.M.U., Aligarh – 202002,  
Uttar Pradesh, India.  
Phone: 09358258725  
E-mail: fahmad32@yahoo.com

**FINANCIAL OR OTHER COMPETING INTERESTS:**

None.

Date of Submission: **Jul 21, 2012**  
Date of Peer Review: **Aug 23, 2012**  
Date of Acceptance: **Nov 09, 2012**  
Date of Publishing: **Jan 01, 2013**