

Anterior Dislocation of the Shoulder Due to an Idiopathic Deltoid Contracture-the Report of a Rare Presentation

SATYADEV VADAPALLI

ABSTRACT

Post injection fibrosis leading to muscle contracture is a known complication. Deltoid fibrosis is known to occur following trauma or an intramuscular injection. Idiopathic Deltoid fibrosis leading to

abduction contracture and anterior dislocation of the shoulder is a rare entity. Prompt diagnosis and surgery by distal release of fibrosed Deltoid muscle will lead to good functional recovery.

Key Words: Abduction contracture, Deltoid fibrosis, Shoulder dislocation, Distal release

INTRODUCTION

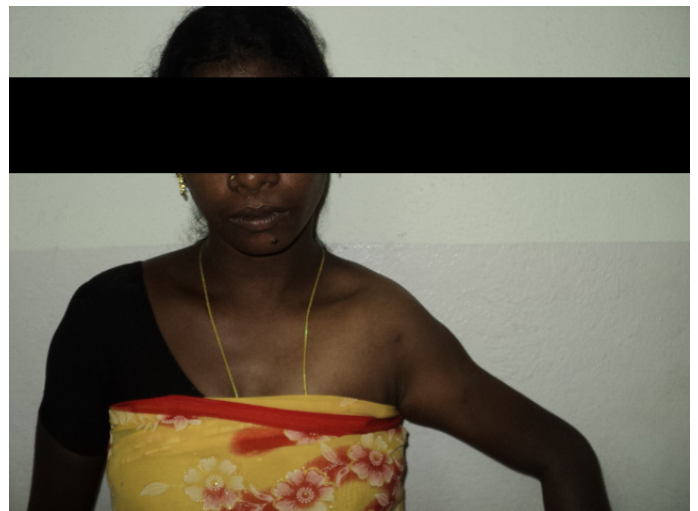Contracture of the middle fibres of the deltoid muscle, which is caused by an injection, is a known complication. This injury will also result in an abduction contracture of the shoulder due to the fibrosis of the middle fibres of the deltoid. An idiopathic isolated deltoid contracture which presents as an anterior dislocation shoulder, is a very rare condition. This is a case report of an anterior dislocation of the shoulder which was caused by an idiopathic deltoid contracture, which had a good surgical outcome with a distal release of the fibrosed deltoid muscle.

CASE REPORT

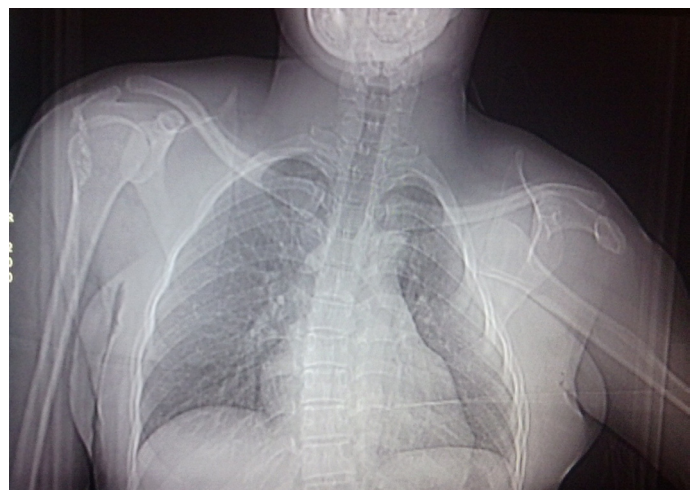A twenty seven years old female presented with deformity of the left shoulder and pain while undertaking strenuous agricultural labour activities. At the age of five, her parents had noticed a mild deformity of her left shoulder, with no limitation of activities. They denied any history of an injection, injury or infection to the shoulder. The child was shown to a local paediatrician but was not advised any treatment. The deformity progressed and the girl found it increasingly difficult to bring the left arm to the side of her body. There was no progression of the deformity after she attained menarche.

On examination, an abduction deformity of the left shoulder, of 30°, dimpling of the skin, and a palpable fibrous band at the middle of the deltoid, were noticed [Table/Fig-1]. The head of the humerus was felt anteriorly in the sub coracoid region. All the other movements of the shoulder were normal. A forceful adduction produced pain and winging of the scapula. The right shoulder was normal on examination, with a full range of movements. Skiagrams revealed an anterior dislocation of the left shoulder [Table/Fig-2]. CT scans, both axial and 3D reconstruction images showed an anteriorly dislocated humeral head with no hypoplasia of the glenoid cavity or any changes in the surrounding bony structures [Table/Fig-3 & 4].

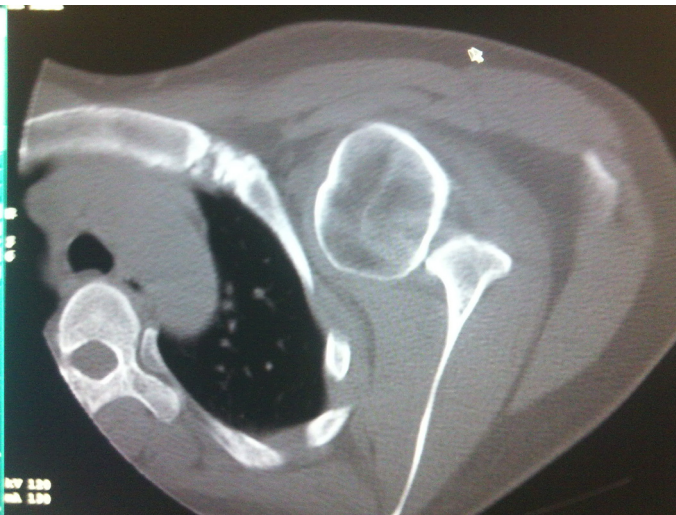After duly explaining about the procedure and the complications, a consent for surgery was obtained from the patient. She was operated by making a longitudinal incision over the left shoulder. The middle fibres of the deltoid could be easily identified as a white



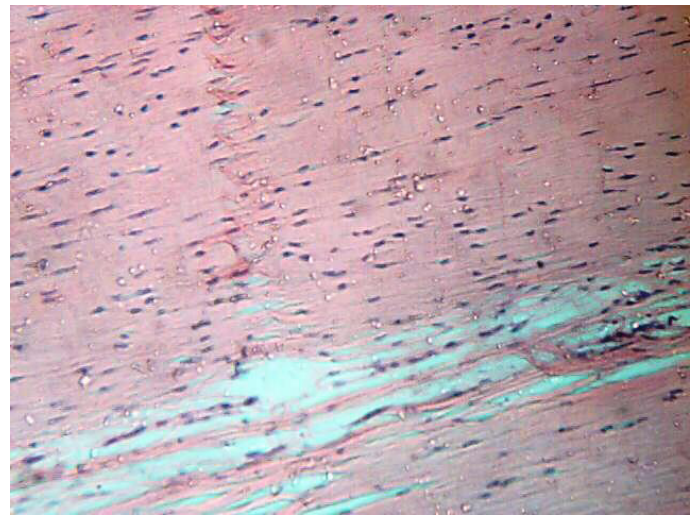
[Table/Fig-1]: Clinical photograph showing abduction contracture of the Shoulder



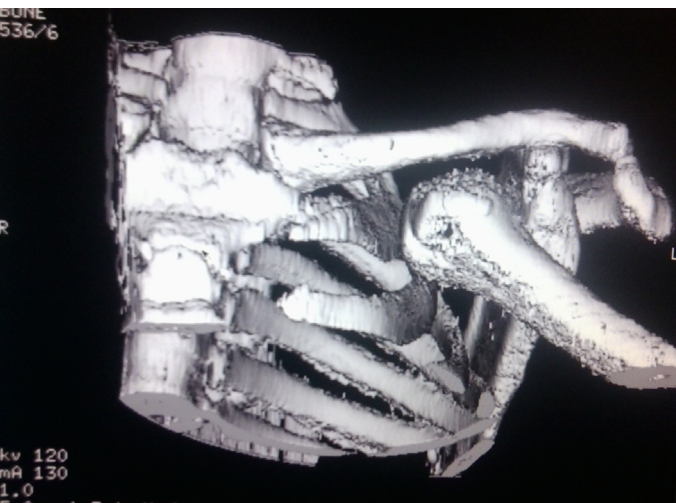
[Table/Fig-2]: X ray showing anterior dislocation of the Left shoulder



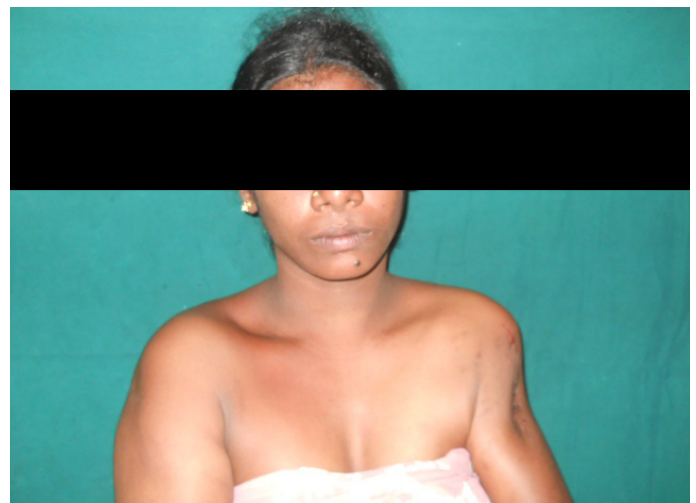[Table/Fig-3]: Axial image with bone window reveals anterior dislocation of humeral head



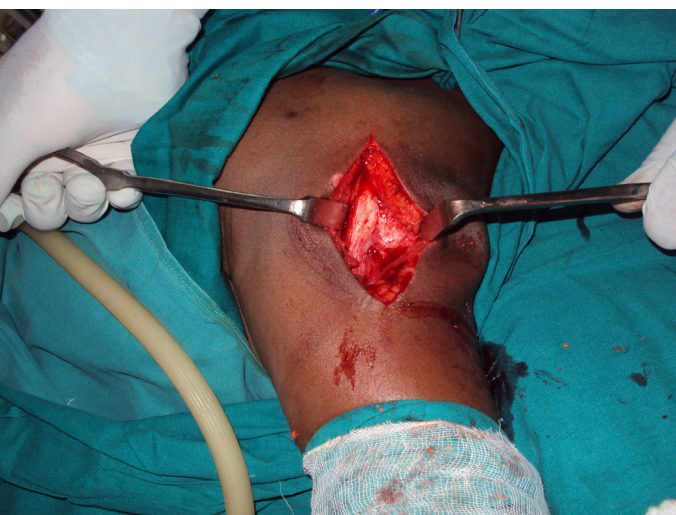[Table/Fig-6]: H & E stain of the excised fibrous band showing collagen and bundles of fibrocytes



[Table/Fig-4]: 3D Volume rendered image showing anterior dislocation of humeral head



[Table/Fig-7]: Post-Operative photograph showing the corrected deformity with operative scar



[Table/Fig-5]: Intra operative photograph showing the white glistening fibrous band

thick fibrous band [Table/Fig-5]. The fibrous band was released from its insertion by using diathermy. The shoulder was held in the adducted position, the remaining fibrous strands were released and the deformity was corrected. The excised fibrosed deltoid muscle was subjected to a histopathological examination. The wound was closed and the limb was suspended in an arm sling. Gentle active and passive exercises were commenced from the second post-operative day.

The histopathological examination revealed a normal skeletal muscle with fibro fatty connective tissue, with collagenization and focal mononuclear cell infiltration, which suggested non-specific myositis [Table/Fig-6]. The deformity was totally corrected, the patient was able to perform all the activities without any pain and the full range of movements of the shoulder were restored [Table/Fig-7]. The patient was followed up for one year and she was found to attend to her daily routine activities and agricultural labour work without any difficulty.

DISCUSSION

A deltoid contracture is usually caused by post injection fibrosis [1] or it may be a part of the congenital contracture of various muscle groups [2]. Some larger series were presented by Shanmuga Sundaram and Chatterjee [1,3]. Idiopathic isolated deltoid contracture is a rare entity with only few cases being reported in the literature. A deltoid fibrosis with anterior dislocation of the shoulder is very uncommon [2,4]. Chari et al reported two cases. Jih-Yang Ko et al., noted antero superior subluxation of the humeral head in 23 shoulders (18 patients) in preoperative radiographs and reported two cases of recurrent anterior dislocation of the shoulder pre operatively [5]. Bhagat et al reported bilateral antero inferior subluxation in one case and Ogawa reported one case [6].

Debabrata Banerji et al., (2008) reported 5 cases of anterior subluxation of the shoulder among 19 patients. In his series, 13 out of

19 cases were idiopathic and there were no dislocations [7]. The anterior subluxation was noted in all the 5 patients who had the contraction band for more than 10 years. The commonest side of occurrence of the idiopathic deltoid contracture was the left side.

Lion L.Y. reported that the deltoid contracture mimicked a dislocation in the routine ski grams but 3-D CT/MRI showed no dislocation. But in the present case, the dislocation was present in the routine ski grams and CT scans.

Jih Yong felt that the position of the humeral head gets altered, depending on the part of the deltoid that is contracted. Pulling of the middle and posterior fibres causes abduction and external rotation of the arm and the humeral head migrates anteriorly and superiorly and it rotates externally. Bhattacharyya [8] has given an anatomical explanation that “the middle part of the deltoid is multi pinnate and it has four intra muscular septa that extend distally from the acromion to interdigitate, with three ascending septae from the deltoid tuberosity of the humerus”. The middle fibres normally contain more connective tissue than other components of the deltoid muscle and usually than the site where the fibrous contractures develop.

Anterior glenohumeral dislocations in children are very rare and they involve high energy trauma. In a rare event of a severe injury, a physeal separation is more common than a dislocation [9]. In this present case, the condition was of an insidious onset and a slow progression, without any history of an overt trauma to the shoulder. In Rowe's review on 500 dislocated shoulders, only eight patients were under the age of 10 years [10].

A deltoid contracture which results in an abduction contracture of the shoulder and winging of the scapula has few differentials which mimic the same presentation. Brachial plexus palsy also results in abduction contracture and winging of the scapula. However, it involves the infraspinatus and the teres minor muscles. Dimpling of the skin and a palpable fibrous band are against the diagnosis of brachial plexus palsy. Involvement of the long thoracic nerve of Bell, which results in the palsy of the serratus anterior, leads to winging of the scapula. A deltoid contracture can be the cause of pain in the shoulder and it may be misdiagnosed as frozen shoulder.

The present patient noticed the deformity at the age of five and the longstanding contracture gradually resulted in an abduction contracture and dislocation, without any restriction on her activities of daily living. The limitation was mainly in reaching the opposite shoulder. The deformity was corrected by a simple distal release and the patient was able to take up all the activities of daily living in two weeks time.

The reported case differs from other reports in that it had a very late presentation, nearly 22 years after its onset and with the absence of any hypoplastic / hyperplastic changes of the surrounding structures and the absence of any weakness of the other groups of muscles. There were no complications like recurrence, keloid formation or reduction in the power of the deltoid muscle, even a year after the surgical procedure.

REFERENCES

- [1] Shanmugasundaram.TK Post injection Fibrosis of Skeletal muscle: A clinical problem. A personal series of 169 cases. *International Orthopaedics. (SICOT)*. 1980; 4: 31-37.
- [2] Chari PR, Rao YV, Rao BK. Congenital abduction contracture with dislocation of shoulder in children a report of two cases. *Aust N Z J Surg*. 1979; 49: 105-06.
- [3] Chatterjee P, Gupta SK. Deltoid contracture in children of central Calcutta. *J Pediatr Orthop*. 1983;3:380-83.
- [4] Lion LY, Zhang LJ, Zhao Q. Deltoid contracture mimicking shoulder dislocation in a 7-year-old boy. *Orthopade*. 2010 Sep;39(9):874-78.
- [5] Ko JY, An KN, Yamamoto R. Contracture of the deltoid muscle: Results of distal release. *J Bone Joint Surg Am*. 1998;80:229-38.
- [6] Bhagat S, Bansal M, Sharma H, Jandhyala R, Amin P, Pandit J. A rare case of progressive bilateral congenital abduction contracture with shoulder dislocations treated with proximal deltoid release. *Arch Orthop Trauma Surg*. 2008 Mar;128(3):293-96.
- [7] Banerji D, De C, Pal AK, Das SK, Ghosh S, Dharmadevan S. Deltoid contracture: a study of nineteen cases. *Indian J Orthop*. 2008 Apr;42(2):188-91.
- [8] Bhattacharyya. S. Abduction contracture of the shoulder from contracture of the intermediate part of the deltoid: Report of three cases. *J Bone Joint Surgery (Br)*.1966; 48(1):127-31.
- [9] John F Sarwark, Erik C King, Joseph A Janicki. Proximal Humerus, Scapula and Clavicle. In: James H Beaty and James R Kasser, Editors. *Rockwood and Wilkins': Fractures in Children, 7th Ed.China: Lippincott William and Wilkins; 2010 ; 635.*
- [10] Rowe CR. Prognosis in dislocation of the shoulder. *J Bone Joint Surg Am*. 1956;38:957-77.

AUTHOR(S):

1. Dr. Satyadev Vadapalli

PARTICULARS OF CONTRIBUTORS:

1. Professor, Department of Orthopaedics, Konaseema Institute of Medical Sciences, Amalapuram, Andhra Pradesh, India.

NAME, ADDRESS, E-MAIL ID OF THE CORRESPONDING AUTHOR:

Dr. Satyadev Vadapalli,
Professor, Department of Orthopaedics,
D.no= 70-7-2/6, Siddhartha Nagar,
Near IMA Hall, Kakinada -533003, India.
Phone: 9440179533
E-mail: drsatyadev9@yahoo.com

FINANCIAL OR OTHER COMPETING INTERESTS:

None.

Date of Submission: **Oct 10, 2012**
Date of Peer Review: **Nov 17, 2012**
Date of Acceptance: **Dec 28, 2012**
Date of Publishing: **Feb 01, 2013**