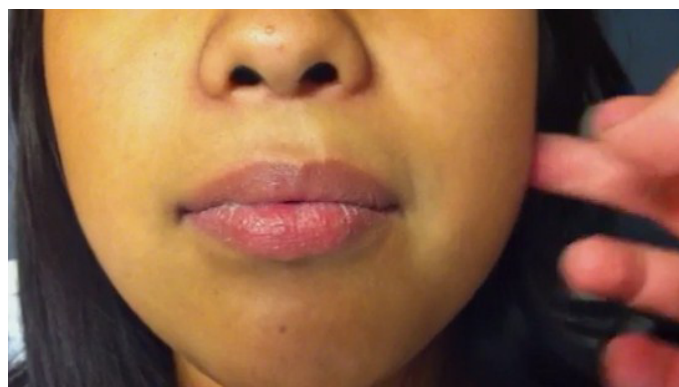


Chvostek's and Trousseau's signs in a Case of Hypoparathyroidism

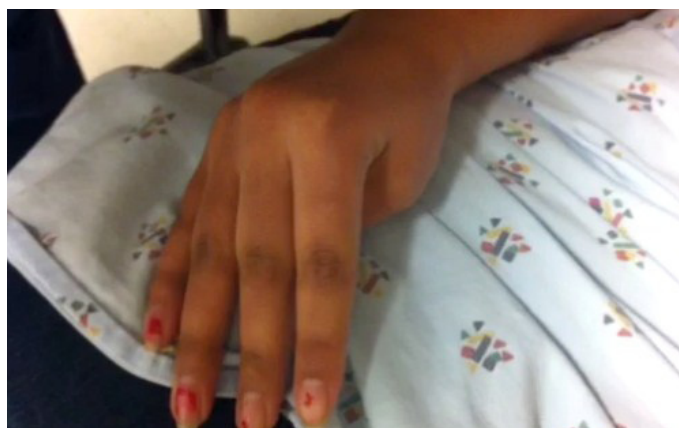
MOHAMMAD R. MOHEBBI, KURT A. ROSENKRANS, MICHAEL J. JUNG

A 15-year-old girl presented with concerns about possible seizure activity during sleep. Her family described it as stiffness and shaking of extremities that lasted for three minutes. There was no postictal period. Upon arrival to the Emergency Room, she was complaining of cramping in lower extremities. She mentioned that she has had occasional cramping in arms and legs for the past two years. On exam, Chvostek's sign (twitching of facial muscles in response to tapping over the facial nerve. [Table/Fig-1] and Video-1 and Trousseau's sign (carpopedal spasm induced by pressure applied to the arm by an inflated sphygmomanometer cuff. [Table/Fig-2] and Video-2 was present. Her total calcium level was 5.5 mg/dL (normal range 9.2-11). Serum albumin level was normal. Serum magnesium was 1.6 mg/dL (1.7-2.6). Serum phosphate level was 4.8 mg/dL (2.7-4.5). Parathyroid hormone level was 0.3 pg/mL (1.6-6.9). Her symptoms resolved after correction of the calcium and other electrolytes. She was discharged on oral calcium supplement and scheduled to follow-up with pediatric endocrinology for management of hypoparathyroidism.



[Table/Fig-1]: Chvostek's sign (twitching of facial muscles in response to tapping over the facial nerve)

Video available on website



[Table/Fig-2]: Trousseau's sign (carpopedal spasm induced by pressure applied to the arm by an inflated sphygmomanometer cuff)

Video available on website

AUTHOR(S):

1. Dr. Mohammad R. Mohebbi
2. Dr. Kurt A. Rosenkrans
3. Dr. Michael J. Jung

PARTICULARS OF CONTRIBUTORS:

1. Siouxland Medical Education Foundation, University of Iowa, 2501 Pierce Street, Sioux City, IA 51104, USA.
2. Siouxland Medical Education Foundation, University of Iowa, 2501 Pierce Street, Sioux City, IA 51104, USA.
3. Siouxland Medical Education Foundation, University of Iowa, 2501 Pierce Street, Sioux City, IA 51104, USA.

NAME, ADDRESS, E-MAIL ID OF THE CORRESPONDING AUTHOR:

Dr. Mohammad Reza Mohebbi,
Siouxland Medical Education Foundation,
University of Iowa, 2501 Pierce Street,
Sioux City, Iowa, 51104, USA.
Phone: +1-712-294-5000
Fax: +1-712-294-5092
E-mail: mohammad-mohebbi@uiowa.edu

FINANCIAL OR OTHER COMPETING INTERESTS:

None.

Date of Submission: **Jan 07, 2013**
Date of Peer Review: **Feb 07, 2013**
Date of Acceptance: **Feb 25, 2013**
Date of Publishing: **May 01, 2013**