

Calcific Tendinitis of the Rotator Cuff: A Review

SUSHIL G KACHEWAR, DEVIDAS S KULKARNI

ABSTRACT

Calcifying tendinitis of the rotator cuff is a common disorder; its underlying mechanism still remains unknown. Although details of the clinical presentation(s) and pathological changes which are associated with calcific tendinitis are available, conservative management of this condition remains a topic of debate. About 90% of the patients can be treated non – operatively, but as some are resistant to conservative treatment; newer techniques or surgery should be indicated.

Rheumatologists and radiologists have often described this shoulder abnormality, leading to its progressive differentiation from other painful shoulder syndromes.

The conservative treatment includes the use of non – steroidal anti – inflammatory agents, roentgen therapy, physical modalities for controlling the pain and for preventing loss of joint mobility, local steroid injections, and open or arthroscopic surgeries.

Results of non – operative treatments have also been satisfactory. These include heat, cold, range of motion and pendulum exercises, diathermy, short – wave, and radiation therapy. Rest, immobilization with a sling, and oral non – steroidal and steroid anti – inflammatory medications have also been mentioned.

This review aimed at looking at calcific tendinitis of the rotator cuff with a wide vision in the light of modern advances; while at the same time, not disregarding the past experiences.

Key words: Calcific tendinitis of shoulder, Rotator cuff, Imaging, Plain radiograph shoulder, Conservative management

INTRODUCTION

Calcifying tendinitis of the rotator cuff is a common disorder and the underlying cause is still not fully understood. Many names have been used to describe it: some of them, such as ‘calcific periartthritis’, emphasise the extra – articular site of the deposit; others, such as ‘periarticular apatite deposition’, mention the nature of the compound which is found in the calcification; and the more recent ones, such as ‘calcifying tendinitis’ [1 – 3], emphasise the active process that might explain the deposition. Other nomenclatures for this entity include calcific/calcifying/calcified/calcareous tendonitis/tendinopathy. While a significant amount of information is available on the clinical presentation(s) and pathological changes which are associated with calcific tendinitis, the conservative management of this condition remains a topic of debate. About 90% of the patients can be treated non – operatively, but some are resistant to conservative treatment and surgery is indicated in such cases.

Rheumatologists and radiologists have often described this shoulder abnormality, leading to its progressive differentiation from other painful shoulder syndromes [4].

The management of calcific tendinopathy remains controversial, and it includes the use of non – steroidal anti – inflammatory agents, roentgen therapy, physical modalities for controlling the pain and for preventing loss of joint mobility, local steroid injections, and open or arthroscopic surgeries [5,6].

Management of the patients with calcific tendinitis varies. Non – operative treatments have been employed with reportedly good results. Non – operative interventions include heat, cold, range of motion and pendulum exercises, diathermy, short-wave, and radiation therapy. Rest, immobilization with a sling, and oral non – steroidal and steroid anti – inflammatory medications have also been mentioned [7 – 9].

Incidence and Demographics

Calcific tendinitis is one of the most common causes of non-traumatic pain in the shoulder [10, 11]. Bosworth [12] reported an incidence of 2.7% in 6061 asymptomatic office workers when both shoulders were examined by radiography; Uthhoff and Sarkar [13] reported that Welfing et al found an incidence of 7.5% in 200 asymptomatic patients and of 6.5% in 925 symptomatic patients. Calcific tendinitis is commonly found in people of the older age groups [14,15].

Stages of calcification

Pre – calcification Stage

Patients usually do not have any symptoms in this stage. At this point in time, the sites where the calcifications tend to develop, undergo cellular changes that predispose the tissues to developing calcium deposits.

Calcific Stage

During this stage, calcium is excreted from cells and it then coalesces into calcium deposits. When it is seen, the calcium looks chalky; it is not a solid piece of bone. Once the calcification has formed, a so – called resting phase begins; this is not a painful period and it may last for a varied length of time. After the resting phase, a resorptive phase begins – this is the most painful phase of calcific tendonitis. During this resorptive phase, the calcium deposit looks like toothpaste.

Postcalcific Stage

This is usually a painless stage, as the calcium deposit disappears and as it is replaced by a more normal appearing rotator cuff tendon.

[Table/Fig-1] Shows Calcific tendinitis of the left supraspinatus tendon, as was seen on high resolution musculoskeletal ultrasound and plain radiographs.

Pathogenesis of Calcific Tendinitis

The natural history of calcific tendinitis has been described as degeneration of the supraspinatus tendon, followed by its calcification and eventually, its rupture into the subacromial bursa. The model which is used most frequently for the pathogenesis of calcific tendinitis of the supraspinatus tendon is that of a degenerative process with secondary calcification within the tendon fibres [16, 17]. The localisation of the calcific deposits in the supraspinatus tendon is thought to occur most likely as a result of 1 of 2 causes: (1) an early impingement syndrome and a longstanding impingement, leading to the degeneration of the tendon fibres, which then leads to calcification; or (2) in patients without an impingement syndrome, the localisation of the calcium deposit may be related to the blood supply of the region.

Calcium crystals are deposited primarily in the matrix vesicles, which coalesce to form large deposits during the formative phase. The fibro cartilage is slowly eroded by the expanding deposit. Radiographic diffraction studies which were done on dehydrated specimens of the calcific deposits have revealed calcium hydroxyapatite $\text{Ca}_{10}(\text{PO}_4)_6(\text{OH})_2$ as the only inorganic constituent of the deposits [14]. The resting phase denotes a variable time period of local inactivity; then the appearance of thin-walled vascular channels at the edge of the deposit heralds the beginning of the resorptive phase. In this phase, the deposit is invaded by macrophages, polymorphonuclear cells, and fibroblasts that phagocytose the deposit. The trigger phenomenon for the commencement of the resorptive phase has not yet been elucidated.

The postcalcific stage is characterised by granulation tissue which replaces the space which is left behind by the removal of the calcium deposit. The postcalcific stage and the resorptive phase of the calcific stage appear to occur concurrently. As the granulation tissue matures to a scar, the collagen and fibroblasts are oriented along the longitudinal axis of the tendon.

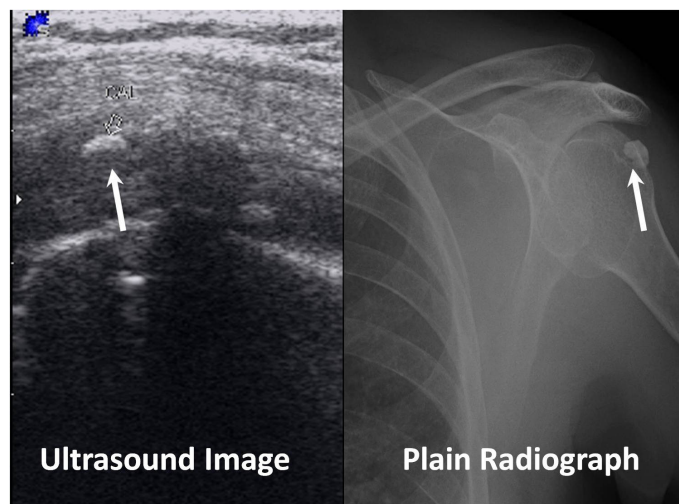
Conservative management of calcific tendinitis

Iontophoresis

Iontophoresis is a process that allows increased penetration of the ionized molecule across or in to the tissue by application of low electric current. It has been found that the use of acetic acid iontophoresis and physiotherapy in the treatment of calcifying tendinitis of the shoulder, result in better clinical and radiologic effects than those which are observed in subjects who are treated by physiotherapy alone [18]. A definite reduction in the calcific area and its density has also been reported with this therapy [19].

The physiologic basis for this approach rests on the passage of ionizable substances through the skin — mainly through the hair follicles and sweat gland canals — through the polar effect of the direct (galvanic) current, which thus triggers the migration of the ionized molecules which are placed under the same polarity electrode, towards the opposite polarity electrode. In this way, acetic acid, which is an inorganic anion, is applied under the cathode (negative electrode) and it will migrate towards the anode (positive electrode) while it is submitted to galvanic current. Because the calcification consists mostly of hydroxyapatite crystals which are insoluble in water and soluble in acidic pH, it is reasonable to expect a regression of the calcification.

In the context of adverse reactions or intolerance to anti-inflammatory agents, acetic acid iontophoresis, because of its non-invasive character, remains a frequently used treatment for calcifying tendinitis of the shoulder.



[Table/Fig-1]: Shows calcific tendinitis of left supraspinatus tendon as seen on high resolution musculoskeletal ultrasound and plain radiograph of left shoulder

Extracorporeal Shock Wave Therapy (ESWT) for Calcific Tendinitis

Extracorporeal shock wave therapy (ESWT) is a non-invasive treatment that involves the delivery of low- or high-energy shock waves via a device to a specific site within the body. These pressure waves travel through fluid and soft tissue; their effects occur at sites where there is a change in impedance, such as the bone/soft-tissue interface. It is thought to disrupt fibrous tissue, with subsequent promotion of revascularisation and healing of tissue. It has also been hypothesised that the shock waves may reduce the transmission of pain signals from the sensory nerves and/or that they may stimulate healing. On that basis, ESWT has been proposed as an alternative to surgery.

Whenever conservative therapy had not been effective in relieving pain and other symptoms, extracorporeal shock-wave therapy (ESWT) had been used [20, 21], yielding results such as relief from pain and improved functions [22–26] that were sometimes as good as those which were achieved by means of surgical procedures.

Radial Shock-Wave Therapy

A Radial Shock Wave (RSW) is a low- to medium-energy shock wave that is pneumatically generated through the acceleration of a projectile which is present inside the handpiece of the treatment device and that is then transmitted radially from the tip of the applicator to the target zone. The pressure and the energy density decrease by the third power of the penetration depth in the tissue. Radial shock waves show a lower peak pressure and a considerably longer rise time than Extracorporeal Shock Waves (ESWs). In Radial Shock-Wave Therapy (RSWT), the focal point is not centred on the target zone, as it occurs in ESWT, but on the tip of the applicator. The energy at the focal point of the shock wave per impulse is called the “Energy Flux Density” (EFD) and it is recorded as joules per area. The effective total energy of a treatment is defined by the number and EFD of the single impulses and by the geometrical measurement of the focal point. Low-Energy Shock Waves (EFD less than 0.1 mJ/mm^2) are generally differentiated from high-energy waves (EFD of $0.2\text{--}0.4 \text{ mJ/mm}^2$) [23].

Therapeutic Ultrasound for Calcific Tendinitis

Ultrasound is a sound wave that has a frequency which is greater than 20 KHz. It is generated by applying an alternate current to a piezoelectric crystal (which is found in the transducer which is in the sound head). This crystal contracts and expands at the same

frequency at which the current changes its polarity. The sound field which is generated by this crystal, in turn, makes the molecules in the sound field vibrate and oscillate.

Ultrasound stimulates the accumulation of the peripheral-blood mononuclear cells by activating endothelial cells. It may also act indirectly by increasing the intracellular calcium levels [27]. Since activated endothelial cells express and release a variety of chemo attractant substances such as chemokines (monocyte chemo attractant protein, interleukin-8, regulated upon activation normal T-cell expressed and secreted [RANTES]) and cytokines (interleukin-2 and stem-cell factor) [28-30], migrating macrophages might be involved in the phagocytosis of calcified particles. At higher intensities, ultrasound may trigger or accelerate the disruption of apatite-like microcrystals. The appearance of these smaller calcium crystals may then stimulate macrophages to remove calcifications by phagocytosis [31, 32]. Finally, the increases in the temperature of tissue which is exposed to ultrasound may increase blood flow (i.e., induce hyperaemia) and metabolism, thus facilitating the disintegration of calcium deposit.

Microwave Diathermy for the Treatment of Calcific Tendinitis

Microwave Diathermy produces hyperthermia in the tissue, which in turn reduces symptoms, and probably favours resorption of calcium deposits. The analgesic effect might be mediated peripherally and/or centrally by inhibition of the noxious evoked discharge of ascending tract neurones [33]. This increase in blood perfusion [34,35] may increase metabolic rate, and could facilitate the disintegration of calcium deposits. Hyperthermia may also stimulate the accumulation of peripheral blood mononuclear cells by activating endothelial cells. Since activated endothelial cells express and release a variety of chemotactic substances, migrating macrophages might be involved in the phagocytosis of calcified particles.

New techniques of management, like percutaneous lavage aspiration can be used. In this method, under local anaesthesia; the calcific deposits are mechanically broken up by puncturing them with a needle and aspirating the calcific material with the help of saline suction. Lavage aspiration with sonographic guidance has been quoted to become the optimal modality for an effective treatment of this painful condition [36]. Use of warm saline has been found to reduce the duration of the procedure and improve calcification dissolution, thereby reducing the frequency of bursitis which follows such procedures [37].

Another technique is the use of cimetidine, for the treatment of chronic calcific tendinitis of the shoulder [38].

It has been concluded that following arthroscopic treatment, the good clinical results do not last long and the affected shoulders have lower clinical scores than healthy shoulders. Supraspinatus tendon tears have been seen more often after calcium removal [39]. Additional subacromial decompression has been found to reduce the postoperative pain [39]. Among modern surgical methods which were carried out for this condition, it has been found that the arthroscopic conventional suture-bridge technique was better in terms of patient satisfaction, functional outcome, and rates of re-tear as compared to the arthroscopic double-row technique which was used for full-thickness rotator cuff tears [40].

In calcific tendinitis, because of calcium deposition in the rotator cuff area, the flexibility is limited and pain develops. Exercise [41], being a non – invasive treatment option for this condition,

should always be the first choice. Rotator cuff exercises like medial rotation, lateral rotation and angled front raises help in retaining shoulder joint movements. Yoga is a subtle form of exercise that improves the flexibility and reduces stress. A dolphin pose helps in stretching the shoulders [41].

CONCLUSION

Calcific tendinitis of the shoulder is a burning problem today, for which, at the moment, prevention appears to be the best cure. Proper exercise and yoga can help in preventing this delimiting malady. Therapies like Iontophoresis, ESWT, RSW, Therapeutic Ultrasound and Microwave Diathermy are of advantage when the disease is diagnosed on time and it has been found to be non responsive to pain killers. Each of these modalities has a potential for reducing the calcification in the tendon. Surgery is only warranted when all these modalities fail to retrieve the patient from pain and discomfort.

REFERENCES

- [1] Uthoff HK. Calcifying tendinitis an active cell mediated calcification. *Virchows Arch.* [Pathol Anat] 1975; 366:51-58.
- [2] Uthoff HK, Sarkar K, Maynard JA. Calcifying tendinitis. A new concept of its pathogenesis. *Clin Orthop.* 1976; 118:164-68.
- [3] Mc Kendry RJR, Uthoff HK, Sarkar K, Hyslop PSG. Calcifying tendinitis of the shoulder: prognostic value of clinical histologic and radiologic features in 57 surgically treated cases. *J Rheumatol.* 1982; 9:75-80.
- [4] Resnick D. Calcium hydroxyapatite crystal deposition disease. In: Resnick D, Niwayama G. Diagnosis of bone and joint disorders. Philadelphia: W B Saunders, 1981; 1575-97.
- [5] Perron M, Malouin F. Acetic acid iontophoresis and ultrasound for the treatment of calcifying tendinitis of the shoulder: A randomized control trial. *Arch Phys Med Rehabil.* 1997;78:379 –84.
- [6] Gimblett PA, Saville J, Ebrall P. A conservative management protocol for calcific tendinitis of the shoulder. *J Manipulative Physiol Ther.* 1999; 22:622 – 27.
- [7] Nutton RW, Stothard J. Acute calcific supraspinatus tendinitis in a three-year-old child. *J Bone Joint Surg Br.* 1987; 69:148.
- [8] Plenk HP. Calcifying Tendinitis of the Shoulder: A critical study of the value of x-ray therapy radiology. 1952; 59:384-89.
- [9] Rowe CR: Calcific tendinitis. Instr Course Lect. 1985; 34:196 – 98.
- [10] Rogers LF, Hendrix RW. The painful shoulder. *Radiol Clin North Am.* 1988; 26(6):1359-71.
- [11] Steinbrocker O. Painful shoulder. In: Arthritis and allied conditions. Tenth edition. Daniel J. McCarty (editor). Philadelphia, Lea and Febiger, 1985;1461-510.
- [12] Bosworth BM. Calcium deposits in the shoulder and subacromial bursitis. A survey of 12,122 shoulders. *JAMA.* 1941; 116:2477-82.
- [13] Uthoff HK, Sarkar K. Calcifying tendonitis. *Baillieres Clin Rheumatol.* 1989; 3:567-81.
- [14] Hernandez-Santana A, Yavorsky A, Loughran ST, McCarthy GM, McMahon GP. New approaches in the detection of calcium-containing microcrystals in synovial fluid. *Bioanalysis.* 2011; 3(10):1085-91.
- [15] Hammer WI. Functional soft tissue examination and treatment by manual methods. 3rd Edition. Jones and Bartlett Publishers: Sudbury, MA. 2007; 27-61.
- [16] Harvie P, Pollard TC, Carr AJ. Calcific tendinitis: natural history and association with endocrine disorders. *J Shoulder Elbow Surg.* 2007; 16(2):169-73.
- [17] Kelley WN, Harris ED Jr, Ruddy S, Sledge CB. Textbook of Rheumatology. 2nd ed. Philadelphia: WB Saunders; 1985; 440-42.
- [18] Leduc BE, Caya J, Dumont M. Treatment of calcifying tendinitis of the shoulder by acetic acid iontophoresis: a double-blind randomized controlled trial'. *Arch Phys Med Rehabil.* 2003 Oct; 84(10):1523-27.
- [19] Perron M, Malouin F. in their study 'Acetic acid iontophoresis and ultrasound for the treatment of calcifying tendinitis of the shoulder: a randomized control trial.' *Arch Phys Med Rehabil* 1997; 78:379-84.
- [20] Gerdesmyer L, Wagenpfeil S, Haake M, et al. Extracorporeal shock wave therapy for the treatment of chronic calcifying tendonitis of the rotator cuff: a randomized controlled trial. *JAMA.* 2003; 290: 2573-80.

- [21] Loew M, Jurgowski W, Mau HC, Thomsen M. Treatment of calcifying tendinitis of rotator cuff by extracorporeal shock waves: a preliminary report. *J Shoulder Elbow Surg.* 1995; 4:101-06.
- [22] Loew M, Daecke D, Kusnierczak D, et al. Shock-wave therapy is effective for chronic calcifying tendinitis of the shoulder. *J Bone J Surg Br.* 1999; 81:863-67.
- [23] Cosentino R, De Stefano R, Selvi E, et al. Extracorporeal shock wave therapy for chronic calcific tendinitis of the shoulder: single blind study. *Ann Rheum Dis.* 2003; 62:248-50.
- [24] Pan PJ, Chou CL, Chiou HJ, et al. Extracorporeal shock wave therapy for chronic calcific tendinitis of the shoulders: a functional and sonographic study. *Arch Phys Med Rehabil.* 2003; 84:988-93.
- [25] Wang CJ, Yang KD, Wang FS, et al. Shock wave therapy for calcific tendinitis of the shoulder. *Am J Sports Med.* 2003; 31:425-30.
- [26] Gerdesmeyer L, Maier M, Haake M, Schmitz C. Physikalischtechnische Grundlagen der extrakorporalen Sto_wellentherapie (ESWT). *Orthopade.* 2002; 31:610-17.
- [27] Mortimer AJ, Dyson M. The effect of therapeutic ultrasound on calcium uptake in fibroblasts. *Ultrasound Med Biol.* 1988; 14:499-506.
- [28] Proost P, Wuyts A, van Damme J. The role of chemokines in inflammation. *Int J Clin Lab Res.* 1996; 26:211-23.
- [29] Ley K. Molecular mechanisms of leukocyte recruitment in the inflammatory process. *Cardiovasc Res.* 1996; 32:733-42.
- [30] Smith RE, Hogaboam CM, Strieter RM, Lukacs NW, Kunkel SL. Cell-to-cell and cell-to-matrix interactions mediate chemokine expression: an important component of the inflammatory lesion. *J Leukoc Biol.* 1997; 62:612-19.
- [31] Naccache PH, Grimard M, Roberge C, et al. Crystal-induced neutrophil activation. I. Initiation and modulation of calcium mobilization and superoxide production by microcrystals. *Arthritis Rheum.* 1991; 34:333-42.
- [32] Terkeltaub R, Zachariae C, Santoro D, Martin J, Peveri P, Matsushima K. Monocyte-derived neutrophil chemotactic factor/interleukin-8 is a potential mediator of crystal-induced inflammation. *Arthritis Rheum.* 1991; 34:894-903.
- [33] Kanui TI. Thermal inhibition of nociceptor-driven spinal cord neurones in the cat: A possible neuronal basis for thermal analgesia. *Brain Res.* 1987; 402:160-63.
- [34] Song CW. Effect of local hyperthermia on blood flow and micro-environment: A review. *Cancer Res.* 1984; 44:4721-30.
- [35] Sekins KM, Emery AF, Lehmann JF, Mc Dougall JA. Determination of perfusion field during local hyperthermia with the aid of finite element thermal models. *J Biom Engineer.* 1982; 104:272- 79.
- [36] Saboeiro GR. Sonography in the Treatment of Calcific Tendinitis of the Rotator Cuff. *JUM.* October 2012; 31:1513-18.
- [37] Sconfienza LM, Bandirali M, Serafini G, Lacelli F, Aliprandi A, Leo GD, Sardanelli F. Rotator Cuff Calcific Tendinitis: Does Warm Saline Solution Improve the Short-term Outcome of Double-Needle US-guided Treatment? [Cited 2013 April 17] Available from www.rsna.org/content/early/2011/11/30/radiol.11111157.full.
- [38] Yokoyama M, Aono H, Takeda A, Morita K. Cimetidine for chronic calcifying tendinitis of the shoulder. *Reg Anesth Pain Med.* 2003; 28 (3): 248-52.
- [39] Balke M, Bielefeld R, Schmidt C, Dedy N, Liem D. Calcifying tendinitis of the shoulder: midterm results after arthroscopic treatment. *Am J Sports Med.* 2012; 40(3):657-61.
- [40] Kim KC, Shin HD, Lee WY, Han SC. Repair integrity and functional outcome after arthroscopic rotator cuff repair: double-row versus suture-bridge technique. *Am J Sports Med.* 2012; 40(2):294-99.
- [41] Rail K. Exercise for calcific tendonitis in the Shoulder. [Cited 2013 April 17] Available from: <http://www.livestrong.com/article/308143-exercise-for-calcific-tendonitis-in-the-shoulder/>

Author(s):

1. Dr Sushil G Kachewar
2. Dr Devidas S Kulkarni

Particulars of Contributors:

1. Associate Professor, Department of Radio-diagnosis, Rural Medical College (RMC), PIMS, Loni, India.
2. Professor, Department of Radio-diagnosis, Rural Medical College (RMC), PIMS, Loni, India.

Name, Address, E-Mail Id of The Corresponding Author:

Dr Sushil Kachewar,
Associate Professor, Department of Radio-diagnosis,
Rural Medical College, PIMS, Loni, India.
Phone: 9921160357
E-mail: sushilkachewar@hotmail.com

Financial or Other Competing Interests: None

Date of Submission: **05 May, 2012**
Date of Peer Review: **22 Feb, 2013**
Date of Acceptance: **01 Jun, 2013**
Date of Publishing: **01 Jul, 2013**