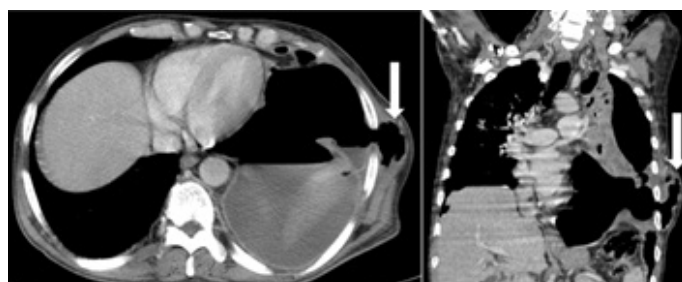


A Rare Case of Tubercular Pyo-Pneumothorax Herniating through the Inter-Costal Drainage Site

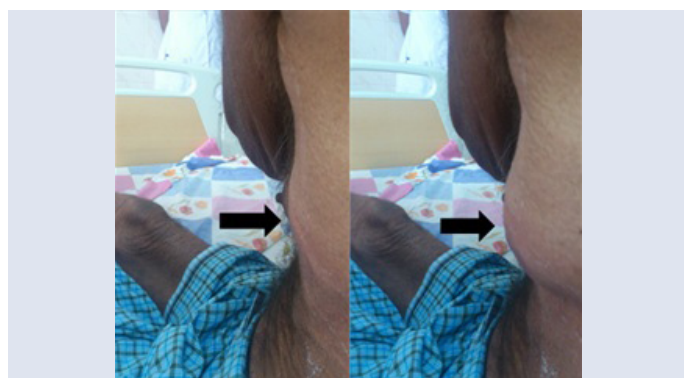PETER GEORGE, MAROLI ROSHAN, SWAPNA PONMALERI KOROTH

Key words: Pyo-pneumothorax, Tuberculosis, Intercostal drainage site, Herniation

A 53 year old diabetic male, who was on anti – tubercular treatment, presented with an expansile swelling on his chest, at the intercostal drainage (ICD) site. He was diagnosed to have a left sided tubercular hydro – pneumothorax, about six weeks earlier. He had noticed the swelling at the ICD site, 5 days ago and he had no pain. Clinically, an expansile swelling of size 5 x 4 cm, was seen at the 6th ICS, in the mid axillary line, which was partially reducible, with palpable crepitations [Table/Fig-1]. The left hemi – thorax showed reduced movements and breath sounds. Contrast enhanced computer tomographic (CECT) images of thorax showed left upper lobe consolidation, with cavities and a hydro – pneumothorax. The left pleural space was seen to extend through the dehiscence on lateral chest wall, forming an air – filled subcutaneous swell-



[Table/Fig-2]: Transverse and coronal images by CECT of thorax showing pleural space extending through the left lateral chest wall dehiscence forming an air-filled subcutaneous swelling(marked with white arrows)



[Table/Fig-1]: Serial photographs demonstrating an expansile swelling with expiratory and inspiratory movements in left infra axillary area(marked with black arrows)

ing. [Table/Fig-2]. Anti-tubercular therapy was continued and a fresh ICD was inserted at the lower intercostal space, which drained the purulent fluid. After a week, repair and layered suturing was done at the site of dehiscence. The wounds approximated and healed over the next 3 – 4 weeks. A pyo-pneumothorax which is caused by tuberculosis is common in endemic areas [1]. There is one report in the literature on herniation of an emphysematous bulla through an ICD site [2]. However, herniation of a pyo-pneumothorax through a closed ICD site was not found in our literature review.

REFERENCES

- [1] Kim HY, Song KS, Goo JM, Lee JS, Lee KS, Lim TH. Thoracic sequelae and complications of tuberculosis. *Radiographics*. 2001; 21: 839-58.
- [2] Okur E, Tezel C, Baysungur V, Halezeroglu S. Extrathoracic herniation of a lung bulla through a tube thoracostomy site. *Interact Cardiovasc Thorac Surg*. 2008; 7: 1210-11.

Author(s):

1. Dr Peter George
2. Dr Maroli Roshan
3. Dr Swapna Ponmaleri Koroth

Particulars of Contributors:

1. Associate Professor, Department of Medicine, Father Muller Medical College, Mangalore – 575002, India.
2. Professor, Department of Medicine, Father Muller Medical College, Mangalore – 575002, India.
3. Assistant Professor, Department of Medicine, Father Muller Medical College, Mangalore – 575002, India.

Name, Address, E-Mail Id of The Corresponding Author:

Dr Peter George,
Associate Professor, Department of Medicine,
Father Muller Medical College, Father Muller Road,
Mangalore, Karnataka, India.
Phone: +91-9845177660, +91-824 2238000
Fax: +91-824 2436352
E-mail: drpetergeorge2002@yahoo.com

Financial or Other Competing Interests: None

Date of Submission: 13 Dec, 2012
Date of Peer Review: 24 Feb, 2013
Date of Acceptance: 10 Jun, 2013
Date of Publishing: 01 Jul, 2013