

# Efficacy of Cheiloscopy in Determination of Sex Among South Indians

VIJAY KAUTILYA D.<sup>1</sup>, PRAVIR BODKHA<sup>2</sup>, NAVEEN RAJAMOHAN<sup>3</sup>

## ABSTRACT

**Introduction:** Human identification plays a vital role in any crime investigation. Along with the various other established methods, cheiloscopy also plays a key role in linking the criminal with the crime. The ability of a technique in differentiating the sex of a person in the field can help in screening a large number of suspects. This study evaluated the efficacy of cheiloscopy in determination of sex among South Indians. It also studied the pattern of dimorphism in the lips and lip prints of south Indians.

**Material and Methods:** Lip prints from 100 medical students (50 males and 50 females) were obtained and were analyzed, based on Tsuchihashi and Suzuki classification, to check for dimorphism. Lip dimensions were studied by using standard sliding calipers for dimorphism.

**Results and Discussion:** The most common pattern of lip print among males was Type III as compared to Type I in females. The outer four portions of the lip showed statistically significant differences in males and females. Middle portion of the lip was statistically insignificant in sex determination, based on lip print patterns. Thickness of the lip was significantly larger in males as compared to that in females and this criterion could be used to establish a logistic regression for determination of sex of a person.

**Conclusion:** Lips not only significantly differ among the males and females in the pattern of the lip print that they present, but they also differ in their size. These features can effectively be used to determine the sex of a person accurately.

**Key words:** Cheiloscopy, Identification, Sex determination, South Indians

## INTRODUCTION

Human identification is a vital event in any crime investigation and developments in forensic science have aided in the application of a variety of techniques for achieving this purpose. The advent of fingerprinting and DNA evidence have perhaps revolutionized the approach towards human identification. These techniques have redefined the levels of precision that can be achieved for establishing identity of a person. Knowledge on all other less utilized, equally flawless techniques becomes necessary when these can't be applied.

Cheiloscopy is one such forensic identification technique which has shown promising results lately. Lip prints are a characteristic pattern of fissures in the form of ridges and grooves called Sulci Labiourm on the labial mucosa, present in the zone of transition between the inner labial mucosa and the outer skin. The study of the patterns produced by the lip prints and their application is called as cheiloscopy or Quiloscopy [1, 2].

RFischer was the first person to describe the lip prints and Sir Edmond Locard first suggested their application in human identification [2]. Dr. Martins Santos, in 1960, provided a simple classification of lip prints for use in human identification [2]. Yasuo Tsuchihashi and Kazuo Suzuki of Japan also suggested their own classification of lip prints and suggested that lip prints exhibited individual specificity [2]. This was followed up by extensive research in most parts of the world, to authenticate the application of cheiloscopy in identification. Over a period of time, it has come to light that lip print patterns suggest a lot about the sex, race, occupation, habits, blood group and paternity of a person. Specific data on an extensive population have been generated over time in this area. Lip prints have proven to be as accurate as fingerprints in establishing individuality of a person, except in uniovular twins, where they are thought to be similar unlike fingerprints [2].

Thus, lip prints have a high degree of evidentiary value whenever

they are recovered at the scene of crime. Sex, stature, age and race of a person are the four pillars of human identity when it comes to forensic identification. Any method of identification which can successfully establish in any of these pillars at the scene of crime can help in ruling out a large number of people from the suspect pool.

In this study, we tried to check the efficacy of cheiloscopy in determining the sex of a person among the South Indian population. The lip prints were divided into six distinct portions and using Yasuo Tsuchihashi and Kazuo Suzuki's classification of lip prints, predilection of each of these patterns to different portions of the lip were studied. Though a lot of studies have been successfully established the applicability of cheiloscopy in determining sex of a person, it is common knowledge that such studies can be population specific and that they need to be studied in various populations. Also, what is unique to our study was that we tried to develop a logistic linear regression from the measurements of the lip print to determine the sex of a person, as patterns in the lip prints at the scene of crime need not be clearly visible due to smudging. In such situations, these newer criteria become very useful in determining the sex of a person.

## MATERIAL AND METHODS

This study was conducted among 100 medical students (50 boys and 50 girls) of Shri Sathya Sai Medical College and Research Centre during the months of June and July, 2012 after obtaining institutional ethical committee clearance. Voluntary informed consents of medical students of south Indian origin were obtained, by considering mother tongue as inclusion criteria (Telugu, Tamil, Kannada and Malayalam). Subjects with any lip anomalies or any active lesions on the lips were excluded. Subjects with any known allergy to lip stick were also excluded.

Dark coloured, non-glossy, non-metallic less moisture containing lip stick was used to develop the lip print. After cleaning the surface

of the lip, lip stick enough for the upper lip was taken on a swab and uniformly smeared on the lip. The lip stick was allowed to settle for a minute, after which a transparent cellophane tape slightly larger than the thickness of the lip was uniformly and gently applied to the lip from right to left. This was removed in one swing and stuck to bond paper. The same procedure was used for the lower lip and hence, the lip prints were collected, with the lips being relaxed and slightly separated from each other. All the lip prints were collected by one person, so as to reduce the errors in collection of the sample. This procedure of collection was similar to what was used by Yogesh et al., [1] and Sharma et al., [3].

Each of the lip print collected were kept in a separate file with details of the subjects. The lip prints were later studied, based on the patterns described by Tsuchihashi and Suzuki. This has been shown in [Table/Fig-1].

Further, the length and thickness of the lips were measured using standard sliding calipers. Measurements for the upper and lower lips were measured separately. Length of the lip was measured between the outermost visible points on the lip print at the angle of the mouth. Thickness of the lip was measured for the upper and lower lip in the midline, at the philtrum. All the measurements were taken by one person using the same calipers and the findings were tabulated.

The data collected was analyzed by using SPSS, version 16 to determine the various frequencies and their significance in determination of sex of the person.

## RESULTS

For analysis of the lip prints, the lips were divided into six portions. The center portion of the lip is more likely to be found at the scene of the crime when analyzing cigarette butts or glassware, as was suggested by Sivapathasundharam et al., [4] and Wadhwan et al., [5]. Hence, the central 15 mm of the lip was considered as a separate portion, as this would have significant practical value. This gave us six portions, namely:

### In the Upper lip

1. Right upper portion.
2. Upper middle portion.
3. Left upper portion.

### In the lower lip

1. Right lower portion.
2. Lower middle portion.
3. Left lower portion.

Each of these portions was observed for the lip print pattern with a hand lens and the data obtained was tabulated. The Tsuchihashi and Suzuki's classification consists of six Types of lip print patterns, namely, Type I (full thickness groves), Type I' (partial groves), Type II branched groves, Type III (crossed groves), Type IV (reticular pattern) and Type V (miscellaneous). These are shown in [Table/Fig-1]. It was observed that in some portions of the lip, there was more than one Type of print. In such cases, to provide uniformity, the most commonly occurring Type of print in the portion was considered.

The subjects who volunteered for the study consisted of 50 boys and 50 girls of the age group of 18-25 years. Considering whole lip together, the most common pattern found in males was Type III (25%), followed by Type I(22%), Type II(21.3%), Type I'(15.3%), Type V(8.3%) and Type IV(8.1%) as compared to females, where the commonest was Type I (30%), followed by Type II (21%), Type I' (19.3%), Type III (13%), Type V (12%) and Type IV (8%).

In the upper lip, when considered separately, the most common print in males was Type I' (21.3%), followed by Type I (20%), Type III (20%), Type II (18.7%), Type V (11.3%) and Type IV (8.7%). In females, the most common lip print was Type I(26%), followed by Type I' (23.3%), Type V (18.5%), Type II (15.3%), Type III and Type

IV (12% each).

In the lower lip, the most commonest Type in males was Type III (30%), followed by Type I (24.1%), Type II (24%), Type I' (9.3%), Type IV (7.3%) and Type V (5.3%). In females, the most common pattern of lip print was Type I (43%), followed by Type II (26.7%), Type I' (15.3%), Type II (14%), Type V (6%), and Type IV (4%).

Not always can one get a complete lip print from the scene of a crime. As has been stated before, some portions of the lip can be more commonly found in the crime scene than in others. In such situations, the data referring to the lip as a whole does not help. Hence, the pattern of the lip print in each portion of the lip, when divided into six portions, was considered separately and the significance of the finding was calculated using Pearson's Chi-square test. The results of the analysis are given in [Table/Fig-2].

Using sliding calipers, lengths and thicknesses of both the upper and lower lips were measured in the lip print separately for the upper lip and the lower lip. The thickness of the lip was measured at the centre of the lip for all the prints. No significant differences were found in the lengths of the lips among males and females. However, the thicknesses of the lips differed significantly in males and females. In males, the average thickness of the upper lip was 13.3mm as compared to 9.5mm in females, the difference in the average among males and females being 3.8mm in the upper lip. The maximum and minimum thicknesses of the upper lip in males were 17.93mm and 11.58mm respectively. In females, the maximum and minimum thicknesses of the upper lip were 13.6mm and 7.01mm respectively.

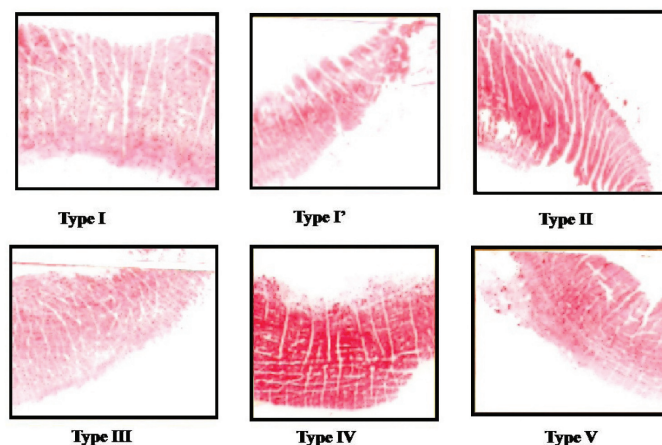
In the lower lip, the average thickness of the lip in males was 14.01mm as compared to 11.09mm in females, the difference in the average among the males and females being 2.92mm. The maximum and minimum thicknesses of the lower lip in males were 17.9mm and 11.58mm respectively. In females, the maximum and minimum thicknesses of the lower lip were 16.4mm and 7.02mm respectively.

As there were statistically significant differences among the thicknesses of both the upper and lower lips in males and females, logistic regression equation was calculated for determination of sex of the person with the thickness of the lip. The equation which we got from the data collected was as follows:

$$S = 18.546 - 1.071(\text{Upper Lip thickness}) - 0.508(\text{lower Lip thickness}),$$

cut off value for S being 0.5 ie. If S was < 0.5, the lip print belonged to a male and if S was > 0.5, the lip print belonged to a female.

This was statistically significant at a p value of less than 0.001. The positive predictive accuracy of the equation was 90% when it was randomly tested in the same population group.



[Table/Fig-1]: Different patterns of lip prints as per Tsuchihashi and Suzuki classification

Sextant of the lip		Sex of the person	Lip print pattern as described by Tsuchihashi and Suzuki					Significance (p)	
			Type I	Type I'	Type II	Type III	Type IV		Type V
Upper lip	Right Upper portion	Males	14	30	22	20	2	12	p= 0.045
		Female	30	22	6	20	0	22	
	Upper middle portion	Males	24	20	10	8	22	16	p= 0.949
		Female	18	20	8	8	30	16	
	Left upper portion	Males	22	14	24	32	2	6	p= 0.009
		Female	30	28	32	8	6	16	
Lower lip	Right lower portion	Males	10	2	38	44	0	6	p= 0.012
		Female	26	10	34	18	0	12	
	Lower middle portion	Males	48	16	6	2	22	6	p= 0.760
		Female	52	18	6	6	12	6	
	Left lower portion	Males	14	10	28	44	0	4	p= 0.027
		Female	24	18	40	18	0	0	

**[Table/Fig-2]:** Percentage occurrence of lip print patterns in each portion in the upper lip

## DISCUSSION

As has been discussed previously, different techniques of identification can be of significant benefit in establishing the correct identity of a person. Cheiloscopy has been proven to be one such very reliable technique. Absence of population specific and gender specific data can hamper its application as evidence. Hence, analysis and testing of such data in various population groups become absolutely essential.

In our study, we tried to analyze the lip print patterns among 100 medical students of South Indian origin. The most common lip print pattern found among them was Type I (52%). When sexual dimorphism was considered, the most common pattern found in females was Type I (30%), as compared to Type III (25%) in males. A significant sexual dimorphism was demonstrated in the lip prints, as was shown in other studies of Sharma et al., [3], Wadhwan et al., [5], Narang et al., [6] and Sharma et al., [7]. However, studies of Gondivkar et al., [8] and Patel et al., [9] found Type II pattern to be the most common among females.

Vats et al., [1], in a study which was done on north Indian population, showed sexual dimorphism in the lip print patterns among different communities. Among Brahmin males, the most common patterns found were Type II and Type III as compared to Type IV and Type I' among Brahmin females. Among the Jat community, Type III was the most common pattern found in males and in females, mixed patterns were more common. Type V pattern was not found in any of the females. Results of the study were statistically significant.

Sharma et al., [3], in a study which was done on 40 subjects, found that Types I and I' were more common in females as compared to Type IV in males. Females were likely to have same pattern in all four quadrants as compared to males who were more likely to have different patterns in all four quadrants.

Narang et al., [6], in their study which was done on 250 subjects, found Type III to be the most common pattern in the lips. Their study showed that the positive predictive value for males, based solely on the lip print patterns, was 92.5% as compared to 81.82%. There was a statistically significant sexual dimorphism in the lip print and this can be efficiently used for prediction of the sex of the person.

Similarly, Sharma et al., [7], in a study which was done on 100 children, could successfully predict sex of the males in 88% of the cases as compared to 90% among females, based only on the lip print patterns. They also suggested application of newer criteria, based on total number of rugae in each quadrant. Females had more rugae as compared to males.

Accuracy of prediction, based only on lip print patterns, was found to be 92% in males and 95% in females, in study of Gondivkar et al., [8]. All these studies showed a statistically significant dimorphism in the lip print patterns among males and females.

In our study, when the upper and lower lip were separately considered, it was found that, Type I was the most common print among females in both the lips, but in males, Type I' was more likely to be found in the upper lip as compared to Type III in the lower lip.

Vahanwala et al., [10], in a study, differentiated the sex of a person, based on dominance of the lip print pattern. Their findings were similar to those of our study. They suggested that presence of Type I and Type I' or Type I and Type II as the dominant patterns in the lip suggested that the prints belonged to females. Presence of Type III, Type IV or Type V varied patterns as the dominant Types suggested that the prints belonged to males.

Malik et al., [11] also found in a study which was done on 100 subjects, that Type I and Type I' were the most dominant Types of patterns in females. Type IV and Type V patterns were the dominant patterns in males. They claim to have a predictive accuracy of 96% in females and that of 90% in males. Dongarwar et al., [12] also reported that Type I and Type I' were the most common patterns in females. Type IV and Type V patterns were most common in males. They had a predictive accuracy of 95% in correct sex determination.

It is not uncommon to find partial lip prints at the scene of crime. Centre portion of the lip has special importance, as it is more likely to be found at the scene of crime and hence, has to be studied separately. In our study, we divided the lip into six portions to study them separately for sexual dimorphism. In the right upper portion of the lip, the most common pattern among males was Type I' as compared to Type I in females. In the upper middle portion, the most common pattern among males was Type I as compared to Type IV in females. Similarly, in the left upper portion, the most common pattern among males was Type III as compared to Type II among females. Type IV (Reticular pattern) was never found in the right upper portion of the lip among females.

In the right lower portion of the lip, the most common pattern which was found was Type III among males as compared to Type II among females. In the lower middle portion, the most common print pattern which was found was Type I in both males and females. In the left lower portion, the most common lip print pattern which was found was Type III in males and it was Type II in females. Type IV (Reticular pattern) was never found in the outer portions of the lower lip among both males and females.

This dimorphism showed excellent statistical significance in the outer portions of the lip, with the right lower portion showing the best statistical significance (p= 0.012). However, the findings which were noted for the middle portions of the lip were insignificant statistically and they couldn't be effectively and efficiently used for sex determination. Based on the lip print patterns, only the outer portions of the lip can be effectively used for sex determination.

Augustine et al., [13], in a study which was done on 600 rural and urban subjects in Maharashtra, found that Type III and Type I patterns were more common in the lateral segments of the upper lip as compared to Type IV in the medial segment of the upper lip. Similarly, in the lower lip, Type III was more common in the lateral segment as compared to Type I in the medial segment. Type IV pattern was more common among females in the lateral segment as compared to Type I among males.

In a similar quadrant based study which was done by Amith et al., [14] on 200 dental students, it was found that among females, Type I was most common in the upper right quadrant and left upper quadrant as compared to Type I in males. In the left lower quadrant and right lower quadrant, Type I was most common in females as compared to Type II in males. The findings were statistically significant for sex determination.

In our study, the lengths and thicknesses of the upper and lower lips in the centre were measured. The length of the lip did not show any significant difference among the males and females. However, the lips differed significantly in their thicknesses. There was a difference of about 3mm in the lip thickness between both the upper and lower lips separately, among males and females. Male lips were thicker as compared to female lips. This large difference of 6mm in the thickness of the lip did not occur due to collection error, as all the prints were collected by the same person by applying same technique. Applying excess pressure which was enough to widen the lips by 6 mm would definitely smudge the pattern visible on the lip print, which was not case in any of the prints. Hence, this difference in the thickness of the lip prints was reliable, which was used to calculate the logistic regression formula, as has been described in the results for determination of the sex of the person. This formula, when tested, gave a correct prediction rate of 90% and it was highly significant statistically with  $p < 0.001$ . This was quite unique for our study and it can be reliably be applied for sex determination from the centre portion of the lip, which is logically found in most of the scenes of crime.

## CONCLUSION

This study which was conducted among 100 on South Indian

medical students, demonstrated the efficacy of cheiloscopy in determination of sex of a person. The patterns of lip prints found, showed significant sexual dimorphism among males and females. The outer portion of the lip can more reliably differentiate the sex of the person, based on the lip print pattern, as compared to the centre portion of the lip. Male lips are thicker as compared to female lips and this criterion can effectively differentiate sex of the person.

## DECLARATION

This paper was presented at SIMLA -2012 conference and only the abstract is published in the conference abstract booklet.

## REFERENCES

- [1] Vats Y, Dhall JK, Kapoor AK. Gender variation in morphological patterns of lip prints among some north Indian population. *J of Forensic Dental Sci.* 2012; 4(1): 19-24.
- [2] Prabhu RV, Dinakar AD, Prabhu AD, Rao AP. Cheiloscopy: revisited. *J of Forensic Dental Sci.* 2012; 4(1): 47-53.
- [3] Sharma P, Saxena S, Rathod V. Cheiloscopy: The study of lip prints in sex identification. *J of Forensic Dental Sci.* 2009; 1(1): 24-27.
- [4] Sivapathasundharam B, Prakash PA, Sivakumar G. Lip prints (Cheiloscopy). *Indian J Dent Res.* 2001; 12(4):234-7
- [5] Wadhwan V, Urs AB, Manchanda A. Sex Determination Using Three Methodologies as a Tool in Forensic Dentistry. *JIDA.* 2011; 5(1):77-81.
- [6] Narang RS, Arora PC, Randhawa K. Cheiloscopy as an aid to forensic methodology. *Ind J Comprehensive Dental Care.* 2011; 1(1):57-61.
- [7] Sharma P, Saxena S, Rathod V. Comparative reliability of cheiloscopy and palatoscopy in human identification. *Ind J of dental Res.* 2009; 20(4): 453-57.
- [8] Gondivkar SM, Indurka RA, Degwekar S, Bhowate R. Cheiloscopy for sex determination. *J of Forensic Dental Sci.* 2009; 1(2): 56-60.
- [9] Patel S, IshPaul, Madhusudan AS, Ramesh G, Sowmya GV. A study of lip prints in relation to gender, family, blood group. *International Journal of Oral and Maxillofacial Pathology;* 2010;1(1):4-7.
- [10] Vahanwalla S, Nayak CD, Pagare SS. Study of lip prints as an aid to sex determination. *Medico-legal Update.* 2005; 5: 93-98.
- [11] Malik R, Goel S. Cheiloscopy-A deterministic aid for forensic sex determination. *J of Ind Acad of oral Med and Radiology.* 2011; 23(1): 17-19.
- [12] Dongarwar GR, Bhowate RR, Degwekar SS. Cheiloscopy-Method of Person Identification and Sex Determination. *Scientific report.* 2013; 2(1): 612 doi:10.4172/scientificreports.612.
- [13] Augustine J, Barpande SR, Tupkari JV. Cheiloscopy as an adjunct to forensic identification: a study of 600 individuals. *J Forensic Odontostomatol.* 2008; 27(2):44-52.
- [14] Amith HV, Anil V Ankola, Nagesh L. Lip Prints – Can it Aid in Individual Identification. *J Oral Health Comm Dent.* 2011; 5(3):113-18.

### PARTICULARS OF CONTRIBUTORS:

1. Assistant Professor, Department of Forensic Medicine & Toxicology, SSSMCRI, Ammapettai, Chennai, Tamil Nadu, India.
2. Professor & Head, Department of Forensic Medicine & Toxicology, SSSMCRI, Ammapettai, Chennai, Tamil Nadu, India.
3. Undergraduate MBBS Student, SSSMCRI, Ammapettai, Chennai, Tamil Nadu, India.

### NAME, ADDRESS, E-MAIL ID OF THE CORRESPONDING AUTHOR:

Dr. Vijay Kautilya D,  
G-3, D Block, Sathya Sai Quarters, SSSMCRI, Ammapettai- 603108, Chennai, Tamil Nadu, India.  
Phone: 09448651848, E-mail: Kautilya.dactroo@gmail.com

FINANCIAL OR OTHER COMPETING INTERESTS: None.

Date of Submission: **Nov 28, 2012**  
Date of Peer Review: **May 21, 2013**  
Date of Acceptance: **Aug 12, 2013**  
Date of Publishing: **Oct 05, 2013**