

Nonrotation of Intestine: A Case Report

ASHWINI CHAMANAHALLI APPAJI¹, ROOPA KULKARNI², JAYANTHI S. KADABA³

ABSTRACT

Nonrotation of intestine is a congenital abnormality of the midgut which is due to error in the process of rotation. Errors in the 2nd and 3rd stage of rotation can lead to series of abnormalities in the form of malrotation and reversed rotation. As a consequence, the relative position of other organs like caecum, intestine, meckel's diverticulum changes. This can lead to missing diagnosis of common clinical conditions such as appendicitis. The incidence of nonrotation is 1:500. The congenital abnormality appears to be rare as this could be an incidental abnormality. The symptoms of nonrotation of intestine could be biliary vomiting, recurrent abdominal pain. This could be due to midgut volvulus and intestinal obstruction which happens as a consequence of nonrotation of the intestine. The investigations used for detection and confirmation are CT Imaging. Other associations of nonrotation of the intestine are peritoneal bands. Here we report a case of nonrotation of intestines. In the cadaver of age around 70 years, the small intestinal loops were situated in the right side of the abdominal cavity and large intestine looped on the left side of the abdominal cavity. This was also associated with aberrant position of the caecum and appendix. There were associated peritoneal bands extending from the ascending colon to the left side the abdominal wall. The bands had been removed to visualize the large intestinal loops.

Keywords: Nonrotation, Peritoneal bands, Intestinal obstruction, Volvulus

INTRODUCTION

During development, intestines are in the form of a loop outside the abdominal cavity called as physiological umbilical hernia. At 10th week of intrauterine life, the intestine returns into the abdominal cavity by a complex process of developmental events called Rotation and Zygosis [1]. Due to the complexity in this process, errors in the location of the alimentary canal are mostly confined to the midgut loop when compared to that of foregut and hindgut. As a result, it becomes very much essential to be aware of the anatomical location of intestines due to errors in rotation of midgut loop especially for surgeons and radiologists.

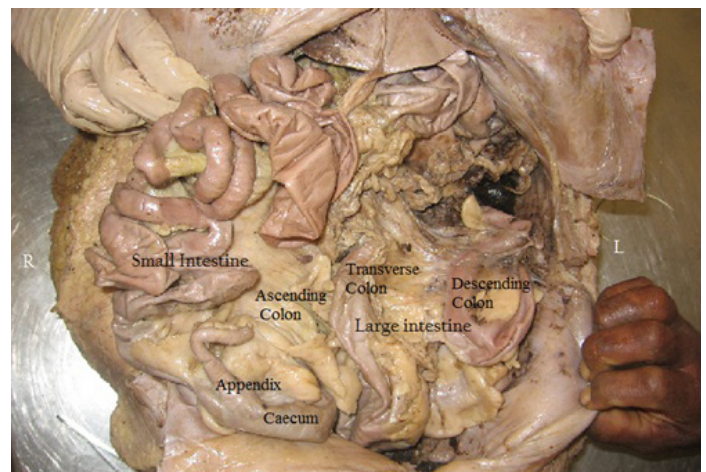
MATERIAL AND METHODS

During the routine undergraduate dissection of abdominal cavity of cadavers, the anterior abdominal wall was incised and opened. When the greater omentum and the stomach were retracted, the anomalies mentioned were detected in the cadaver aged around 70 years.

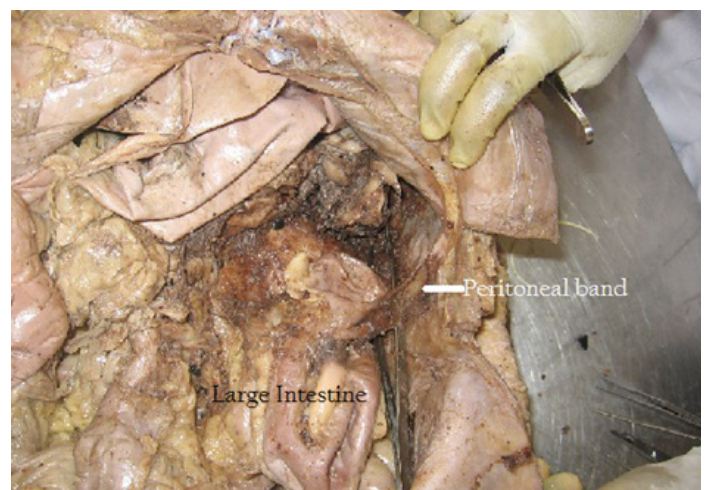
CASE REPORT

On observation, it was noticed that the small intestinal loops were on the right side and the large intestine was seen in left side of the abdominal cavity [Table/Fig-1]. This was evident, when the small intestinal loops were pulled to the left to find the ascending colon absent in the right paracolic gutter. The beginning of the large intestine was identified by looking out for the vermiform appendix. It was seen in the right iliac fossa. The ascending colon was identified as shown in the [Table/Fig-1] just to the right of the midline. But the transverse colon was not seen. This was seen only when the peritoneal band adjacent to the ascending colon was cut open. The band was extending from the ascending colon to the descending colon. Another band was noticed from the right colic flexure to left side of the abdominal wall [Table/Fig-2]. The descending colon continued as sigmoid colon. The sigmoid colon was normal in position. The sigmoid mesocolon was shorter.

Thus, the anomaly was Nonrotation of the intestine with the presence of bands which occur due to error in the rotation of the gut. The superior mesenteric artery was normal in position, anterior to the duodenum.



[Table/Fig-1]: showing the small intestine on the right side and the large intestine on the left side of the abdominal cavity



[Table/Fig-2]: showing peritoneal bands between large intestine and the lateral abdominal wall

DISCUSSION

The development of midgut is a very dynamic process extending from the 5th week to 10th week. During this time the midgut tube herniates outside as physiological hernia and returns back to the abdominal cavity in a organized and sequential manner. If this sequential return of the midgut gets disorganized, it leads to anomalies of rotation of the gut in the form of nonrotation, malrotation and reversed rotation.

Nonrotation occurs when the intestinal loop fails to reenter the abdominal cavity as in exomphalos. Defects in 2nd and 3rd stage of rotation leads to abnormalities like malrotation and reversed rotation. Nonrotation occurs where the umbilical ring is wider leading to enmasse entry of the intestinal loop. This results in small intestine on the right side and the large intestine to the left of the midline [2]. The present case description simulates the above mentioned abnormality. Hence this case is Nonrotation of intestine.

Anomalies during 2nd stage of intestinal rotation are more common in the form of partial gut rotation, malrotation of midgut loop, subphrenic caecum and mobile proximal colon [3].

These anomalies tend to occur when the umbilical ring is wider and the normal sequence of the return of the prearterial and postarterial segment is lost. Non-rotation results in undue narrow base and lengthening of the mesentery leading to ptosis, torsion and volvulus [4,5].

Normal rotation of intestine leads to a broad attachment of the mesentery thus preventing the twisting of intestines. If there is malrotation of intestines, abnormal attachment of mesentery occurs. This narrow attachment of the mesentery may predispose the intestine to volvulus which can progress to ischemia and necrosis [6].

The incidence of malrotation is 1 in 500 live births. Its true prevalence is unknown though incidence by gastrointestinal contrast studies reveal 1 in 500. Midgut volvulus is the common cause of biliary vomiting and abdominal pain in children [7]. Its importance relates to clinical condition like intestinal obstruction leading to ischemia and hemorrhage [8].

The incidence reported may not be the true incidence as they may be asymptomatic throughout life without getting detected.

Congenital malrotation usually shows up in the first month of life. But the signs of identification are not obvious and are nonspecific. The diagnosis depends on the radio imaging techniques especially the CT imaging. In a few of them it may diagnosed by incidental imaging [9]. Usually the case detection is an autopsy finding or incidental finding during gastroenterostomy.

Nonrotation of the intestine usually presents with chronic/recurrent vague abdominal pain, may be postprandial. The location is non-specific occurring in epigastric fossa to other areas of the abdominal cavity. As a result, the pain is initially managed conservatively and later by surgical correction. Any patient with recurrent abdominal pain, signs and symptoms of abdominal obstruction, duodenal ulcers should be investigated to rule out malrotation of intestine [10].

Non-rotation of intestine may lead to aberrant position of appendix and caecum [11].

Because of this, the standard symptoms and signs are not elicited

in appendicitis and diseases of the caecum. This may mislead the surgeons in common clinical conditions.

Disarrangement of intestines may be associated with peritoneal bands. The most common is Ladd bands. These bands extend from the misplaced caecum to the peritoneum and liver by crossing the duodenum [9]. These can also extend between different parts of intestines.

In this case, there were many peritoneal bands. One large band extended from the ascending colon to the left colic flexure. Only on removal of this band was the transverse colon exposed. Another band extended from the descending colon to the lateral abdominal wall on the left side.

These types of peritoneal bands may predispose to internal hernias, volvulus leading to intestinal obstruction. It also leads to small compartments created which can form a potential storehouse of infection and be a cause for fever of unknown origin.

CONCLUSION

The incidence of nonrotation appears to be rare as detection is incidental unless there are symptoms of recurrent abdominal pain, biliary vomiting. Defective rotations of the intestine may lead to signs of midgut volvulus resulting in ischemia and infarction. They need the assistance of radio imaging techniques for detection and confirmation. Non-rotation/malrotation of the intestines becomes important to the surgeons because location of appendix is different – so the clinical presentation of appendicitis is different and the procedure of surgery changes depending on the location. Due to change in position of small intestine, the position of meckel's diverticulum again changes. Another observation that was made was the presence of bands – this could result in volvulus and leading to intestinal obstruction. Thus, a thorough knowledge of the embryology of rotation of gut, malrotation and its anatomy should be known to the surgeon.

REFERENCES

- [1] Keith L Moore, Persaud T V N (2008), Before We are Born Essentials of Embryology and Birth Defects, Saunder's Elsevier Publication, 8th edition, The Alimentary or Digestive System: 146-48.
- [2] Miller AJW, Rode H, Cywes S. Malrotation and Volvulus in Infancy and Childhood. *Seminars in Pediatric Surgery*. 2003;12 (4): 229-36.
- [3] Keith L Moore, Persaud T V N (2008), The developing Human-Clinically Oriented Embryology, Saunder's Elsevier Publication, 8th edition, The Digestive System:231.
- [4] Marx R. Nonrotation of Intestine. *Annals of Surgery*. 1939;109(1): 49-56.
- [5] Pazhanivel M, Ramamoorth M, Venkataraman J. Nonrotation of Intestine. *CMAJ*. 2008;179 (1): 49-50.
- [6] Vinocur DN Lee EY Eisenberg RN. Neonatal Obstruction of Intestine. *American Journal of Radiology*. 2012; 197: W1-W10.
- [7] Kamal M I. Defusing the intra-abdominal ticking bomb: intestinal malrotation in children. *CMAJ* 2000;162(9): 1315-17.
- [8] Belgaumkar A, et al. Small bowel haemorrhage associated with partial midgut malrotation in a middle-aged man. *World Journal of Emergency Surgery*. 2009; 4: 1-4.
- [9] Pickhardt PJ Bhalla S. Intestinal Malrotation in Adolescents and Adults: Spectrum of Clinical and Imaging Features. *American Journal of Radiology*. 2002; 179(6): 1429-35.
- [10] MAJ Monty L, Gohl M C. Midgut Nonrotation in Adults. *American Journal of Surgery*, 1975; 129: 319-23.
- [11] Vosburgh A S. Nonrotation of Intestine. *Annals of Surgery*. 1913; 58(6): 822-27.

PARTICULARS OF CONTRIBUTORS:

1. Associate Professor, Department of Anatomy, M S Ramaiah Medical College, Bangalore, India.
2. Professor, Department of Anatomy, M S Ramaiah Medical College, Bangalore, India.
3. Professor, Department of Anatomy, Vydehi Institute of Medical Sciences, Bangalore, India.

NAME, ADDRESS, E-MAIL ID OF THE CORRESPONDING AUTHOR:

Dr. Ashwini Chamanahalli Appaji,
Associate Professor, Department of Anatomy, M S Ramaiah Medical College, Bangalore, 1465, 5th Main,
2nd Stage, 1st E Block, Rajajinagar, Bangalore - 560010.
Phone: +91-9845994708; E-mail: ashwinishivaprasad@gmail.com

FINANCIAL OR OTHER COMPETING INTERESTS: None.

Date of Submission: **May 12, 2013**

Date of Peer Review: **Jul 27, 2013**

Date of Acceptance: **Aug 20, 2013**

Date of Publishing: **Nov 10, 2013**