

Metastatic Cardiac Tumor from Bronchogenic Carcinoma via Pulmonary Vein: A Case Report

RUDRESH HIREMATH¹, AISHWARYA K C.², GRISELDA PHILOMENA NORONHA³, SIDDAPPA B. NAIK⁴, SHRUNGA TEJASVI⁵

ABSTRACT

Metastatic tumors of the heart are more common than the primary cardiac tumors. Bronchogenic carcinoma is one of the common primaries for cardiac metastases. Cardiac metastasis from bronchogenic carcinoma via pulmonary vein is rare occurrence. We present a case of central bronchogenic carcinoma with left atrial tumor thrombus via right superior pulmonary vein.

Keywords: Cardiac metastasis, Tumor extension via pulmonary vein, Bronchogenic carcinoma

INTRODUCTION

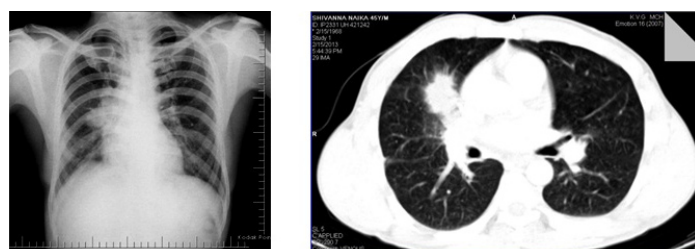
Metastatic tumors of the heart are more common than the primary cardiac tumors [1]. The reported incidence of primary cardiac tumors ranges from 0.001% to 0.03 % [1]. Most of the cardiac metastases are undetected before the death. Autopsy studies have found cardiac metastases to be present in up to 20% of patients with neoplasms [2]. Most common cause for cardiac metastases is malignant melanoma, followed by leukemia, lymphoma, lung and breast carcinoma [1,2]. Bronchogenic carcinoma can metastasize to heart via direct extension, hematogenous spread, lymphatic spread or via transvenous route. Cardiac metastases from bronchogenic carcinoma via transvenous route are rare occurrence [3].

CASE REPORT

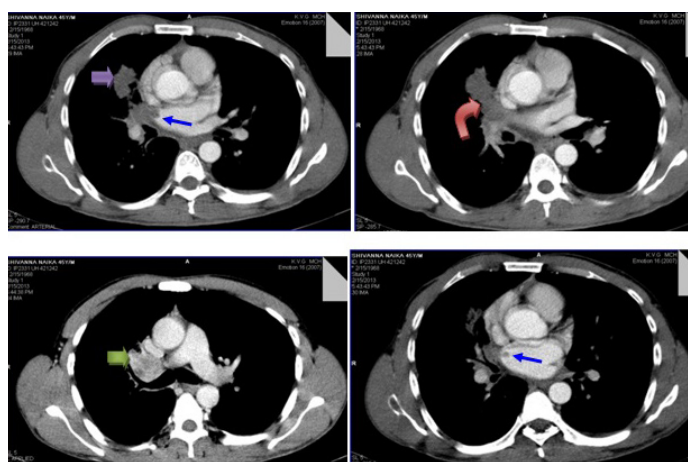
45-year-old male patient presented with severe chest pain & back pain since three months not relieved completely by analgesics to orthopedic department. Patient also complaints of fever on & off, unproductive cough and significant history of weight loss. With these complaints patient was referred to department of Radiodiagnosis K V G medical college Sullia for chest radiograph. Chest radiograph postero-anterior view revealed a well defined spiculated right hilar mass lesion with enlarged right hilum suggestive of lymphadenopathy. Small sclerotic lesion is noted in the right 5th rib [Table/Fig-1].

Patient referred for the contrast enhanced computed tomography (CT) of chest for conforming & staging of the tumor. CT chest was performed with Siemens Emotion 16 slice multidetector CT before and after injecting intravenous non ionic contrast material. High resolution computed tomography of lungs was also performed for better delineation and identification of intrapulmonary metastases.

Contrast enhanced CT chest revealed a well defined spiculated heterogeneously enhancing mass lesion in the right hilar region measuring 37 x 64 x 67 mm with areas of necrosis within. Enlarged enhancing right hilar lymph node is noted. Enhancing subpleural nodules are noted in the right lung. Multiple well defined lytic lesions were noted in the right scapula, multiple ribs & in D1 and



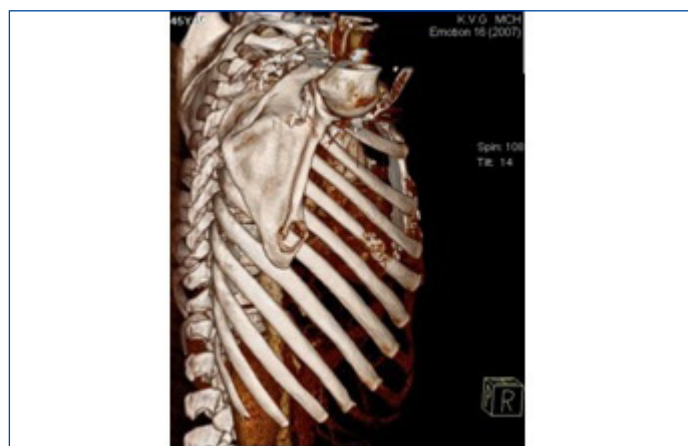
[Table/Fig-1]: Chest radiograph Postero-anterior view & CT thorax lung window showing spiculated right hilar mass



[Table/Fig-2]: Contrast enhanced axial CT scan, shows enhancing right hilar mass lesion (purple arrow) with hilar lymphadenopathy (green arrow). Note right superior pulmonary vein is dilated showing enhancing thrombus within (curved red arrow) and extending into the left atrium. Tumor thrombus is seen floating in the contrast filled left atrium (blue thin arrow)

L1 vertebral bodies [Table/Fig-2]. Right superior pulmonary vein was dilated with enhancing soft tissue density mass arising from the spiculated right hilar mass and extending into the left atrium. Left atrial intra cardiac mass is seen as enhancing soft tissue density filling defect, measuring 08 x 09 mm [Table/Fig-3]. No evidence of direct pericardial infiltration from the lung mass was noted.

Radiological diagnosis of bronchogenic carcinoma with mediastinal nodal, skeletal, cardiac and pleural metastases was given with



[Table/Fig-3]: CT Volume rendered technique image showing lytic lesions in the right scapula & right fifth rib

stage of IV according to new TNM staging. Patient was referred for the higher center for further treatment.

DISCUSSION

Lung cancer metastases are too far common in people living with lung cancer. Nearly 50 % of newly diagnosed lung cancers already demonstrate metastases within the lung, brain, liver, adrenal gland, and osseous structures [4].

Metastases to the heart and pericardium are much more common, approximately 20 – 40 times than the primary cardiac tumors and are generally associated with poor prognosis [5]. A study conducted with review of 3314 consecutive autopsies by Abraham KP concluded that incidence of cardiac and pericardial metastasis is 10 to 12 % of all patients with malignancies [6]. According to Lam KY and Chan who conducted study on 12,485 consecutive autopsies metastases to heart were found in 1.23 % compared with a 0.056 % prevalence of primary cardiac tumors [7]. Impairment of the cardiac function occurs in approximately 30 % of patients with cardiac metastases and is usually attributable to pericardial effusion [5].

Cardiac metastases can occur by four routes of spread, retrograde lymphatic extension, hematogenous, local extension or transvenous route [8]. The predominant route of cardiac metastases is by retrograde lymphatic channels in the mediastinum resulting in small epicardial tumor implants [5]. Bronchogenic carcinoma, esophageal carcinoma and breast carcinoma can cause direct extension of the primary tumor through the invasion of pericardium [5].

The final pathway of spread of tumor through transvenous route can occur into the right atrium through the inferior or superior vena cava and into the left atrium through the pulmonary veins. Renal cell carcinoma is most common malignancy extending into right atrium via inferior vena cava. Bronchogenic carcinoma and some metastatic tumors of lung, especially metastases from osteogenic sarcoma of bone, extend into the left atrium through pulmonary veins [8].

Cardiac metastases from bronchogenic carcinoma may be via direct extension of primary tumor or combination of lymphatic or hematogenous dissemination. According to study conducted by Tamura et al the incidence of cardiac & pericardial metastases in patients with bronchogenic carcinoma was 17 to 31 % [9]. Only few cases of cardiac metastasis from bronchogenic carcinoma via

pulmonary veins in left atrium have been reported [9,10].

Patients with these tumor thrombus in left atrium may represent with murmurs, syncopal attacks or sudden cardiac death [10]. Unfortunately this tumor thrombus may further throw systemic emboli which may result in brain metastases or stroke [10].

Availability of extensive imaging modalities like multidetector computed tomography, Magnetic resonance imaging and transesophageal echocardiography helps in the diagnosis & characterizing these tumor thrombi and helps in the preoperative surgical planning [3].

CONCLUSION

Bronchogenic carcinoma is one of the causes for cardiac metastatic tumors, metastasizing via retrograde lymphatic spread, hematogenous spread or by direct extension. Intracardiac extension of lung tumor via pulmonary veins in the left atrium is rare occurrence & can pose a serious problem of systemic embolization apart from sudden cardiac death due to massive tumor emboli.

REFERENCES

- [1] Burke AP & Virmani R. Tumors of the heart & great vessels. In Atlas of tumor pathology. Fascicle 16, Series 3. Washington DC, Armed forces institute of pathology, 1996.
- [2] Glancy DL & Roberts WC. The heart in malignant melanoma. A study of 70 autopsy cases. *Am J Cardiol.* 1968; 21: 555–71.
- [3] Blackwood GA & Stephen S. Radiological case of the Month. *Applied Radiology.* November 1999.
- [4] Stacy J. UyBico, Carol C. Wu, Robert D. Suh, Nanette H. Le, Kathleen Brown and Mayil S. Krishnam. Lung Cancer Staging Essentials: The New TNM Staging System and Potential Imaging Pitfalls, *Radio Graphics.* September. 2010; 30: 1163-81.
- [5] Caroline Chiles, Pamela K. Woodard, Fernando R. Gutierrez, Kerry M. Link. Metastatic involvement of heart & pericardium: CT & MR imaging, *Radio Graphics.* 2001; 21:439–49.
- [6] Abraham KP, Reddy V, Gattuso P. Neoplasms metastatic to the heart: review of 3314 consecutive autopsies. *Am J Cardiovasc Pathol.* 1990; 3:195-98.
- [7] Lam KY, Dickens P, Chan ACL. Tumors of the heart: A 20-year experience with a review of 12,485 consecutive autopsies. *Arch Pathol Lab Med.* 1993; 117:1027-31.
- [8] Schoen FJ, Berger BM, Guerina NG. Cardiac effects of noncardiac neoplasms. *Cardiol Clin.* 1984; 2:657-70.
- [9] Tamura A, Matsubara O, Yoshimura N, Kasuga T, Akagawa S, Aoki N. Cardiac metastasis of lung cancer: a study of metastatic pathways and clinical manifestations. *Cancer.* 1992; 70:437-42.
- [10] Lin MT, Ku SC, Wu MZ, Yu CJ. Intracardiac extension of lung cancer via the pulmonary vein. *Thorax.* 2008;63(12):1122.

PARTICULARS OF CONTRIBUTORS:

1. Associate Professor, Department of Radio-Diagnosis, K.V.G. Medical College Hospital, Sullia, Dakshina Kannada, Karnataka, India.
2. Assistant Professor, Department of Radio-Diagnosis, K.V.G. Medical College Hospital, Sullia, Dakshina Kannada, Karnataka, India.
3. Resident, Department of Radio-Diagnosis, K.V.G. Medical College Hospital, Sullia, Dakshina Kannada, Karnataka, India.
4. Resident, Department of Radio-Diagnosis, K.V.G. Medical College Hospital, Sullia, Dakshina Kannada, Karnataka, India.
5. Resident, Department of Radio-Diagnosis, K.V.G. Medical College Hospital, Sullia, Dakshina Kannada, Karnataka, India.

NAME, ADDRESS, E-MAIL ID OF THE CORRESPONDING AUTHOR:

Dr. Rudresh Hiremath,
Associate Professor, Department of Radio-Diagnosis, K.V.G Medical College, Sullia,
Dakshina Kannada, Karanataka-574 327, India.
Phone: 09945560627, E-mail: drrudresh76@yahoo.co.in

FINANCIAL OR OTHER COMPETING INTERESTS: None.

Date of Submission: **Mar 02, 2013**
Date of Peer Review: **May 13, 2013**
Date of Acceptance: **May 29, 2013**
Date of Publishing: **Nov 10, 2013**