

Donor Site Evaluation: Anterior Iliac Crest Following Secondary Alveolar Bone Grafting

NANDAGOPAL VURA¹, RAJIV REDDY K.², SUDHIR R.³, RAJASEKHAR G.⁴, VARUN RAJA KALUVALA⁵

ABSTRACT

Introduction: The use of autogenous bone graft for Secondary alveolar bone grafting is well established in the treatment of cleft lip and palate patients.

Aims and Objectives: To evaluate post-operative morbidity of anterior iliac crest graft after secondary alveolar bone grafting in cleft patients.

Material and Methods: Forty patients during the period from July 2008 to March 2013, who underwent secondary alveolar bone grafting by harvesting graft from anterior iliac crest in Mamata Dental Hospital, Khammam, Andhra Pradesh, India are included in the present study. Unilateral and bilateral cleft patients who had undergone secondary alveolar bone grafting (SABG) with anterior iliac crest as their donor site have been selected and post-

operative complications from the surgery were evaluated with the help of a questionnaire which included pain, gait disturbances, numbness and scar problems (infection, irritation).

Results: Patients who were operated gave maximum score for pain as 8 on visual analogue scale. No pain was observed in any of the cases after 8 days, gait disturbances were seen in all patients (limping) for 2-6 days, there was no post-operative numbness with all the patients returning to their routine in 6- 15 days and 90% of the patients gave a satisfied response towards scar.

Conclusion: From the results in our study the morbidity after harvesting bone from iliac crest was found to be moderate to low, which had minimal complications and were well tolerated and greater acceptance from the patient.

Keywords: Cleft alveolus, Iliac crest, Secondary Alveolar Bone Grafting

INTRODUCTION

Autogenous bone grafting for the alveolar cleft was well established in the treatment of cleft lip and palate patients. Various donor sites for secondary alveolar bone grafting (SABG) have been described. Iliac crest, calvarium, mandibular symphysis and tibia are among them. The iliac crest is considered to be the "gold standard" of donor sites [1-4]. Because of its accessibility and the quantity of bone available (approximately 50 cm³ of corticocancellous bone), [5-8] relative ease of bone harvest and the defect is both well covered and less prone to pathological fracture.

Some authors have contradicted the use of iliac crest as donor site [2,4,6]. They found considerable degree of morbidity and post-operative complications, such as chronic pain, gait disturbances, numbness and visible scar. But iliac bone graft is still considered as the first choice as a donor site. In the present prospective study the post-operative complications following bone harvesting from anterior iliac crest in cleft patients were evaluated using a questionnaire.

MATERIAL AND METHODS

Forty patients visiting the department of oral and maxillofacial, Mamata Dental College, Khammam, Andhra Pradesh, India, surgery were included in the study who were treated by secondary alveolar bone grafting by using anterior iliac crest as donor site during the period from July 2008 to March 2013. Ethical committee approval was taken from the institute and after obtaining informed consent from the patients, the post-operative complications were assessed periodically, according to the questionnaire given by Swan et al., [9] which was administered in the local language [Table/Fig-1]. The study was blinded to the observer who evaluated the patients and was unaware of the outcome of the study. Patients who underwent SABG elsewhere with donor site other than anterior iliac crest were excluded from the study.

All the variables pertaining to the post-operative complications were

assessed by a list of questionnaire. All the patients were reviewed post-operatively after 1 week, 15 days, 1 month, and 3 months to 9-12 months respectively. At every appointment the donor site was evaluated and details were recorded.

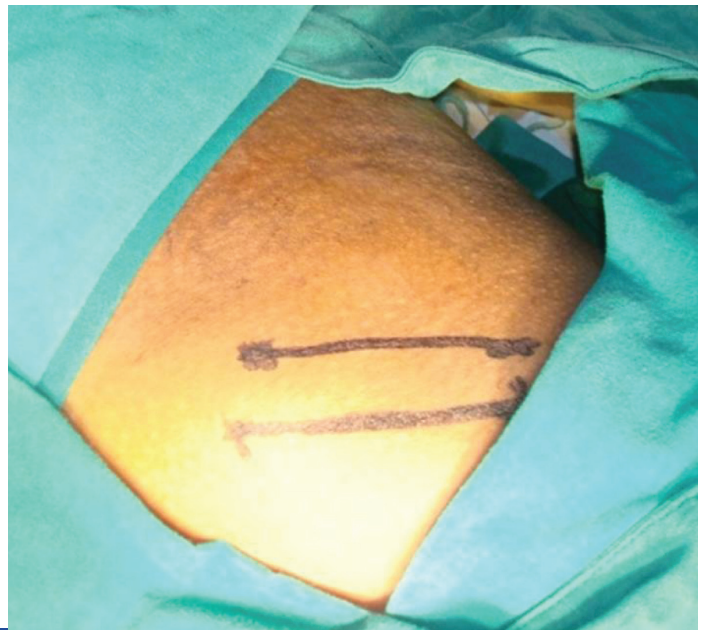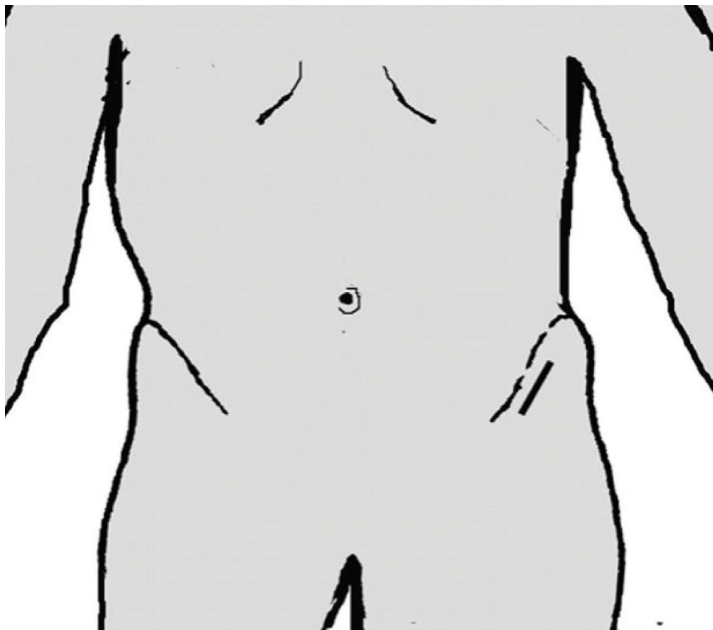
Pain was assessed by eliciting the severity using visual analogue scale and the duration of pain was recorded.

Gait disturbance, duration of limping and walking with or without the help of an aid was evaluated. The number of days to revert back to normal gait and days taken to return to their normal activity were asked. All the variables were recorded.

Complications like numbness or any sensory loss in the lower limb region postoperatively and finally regarding satisfaction by the presence of scar on the hip region were also recorded. The data obtained was entered in to Microsoft excel word sheet and subjected

- How long did the pain persist in the hip region after operation?
 - Grade the pain over the VAS (VISUAL ANALOGUE SCALE PROVIDED)?
- | | | | | | | | | | | |
|---------|---|-----------|---|---------------|---|---------------|---|-------------|---|---------------------|
| 0 | 1 | 2 | 3 | 4 | 5 | 6 | 7 | 8 | 9 | 10 |
| NO PAIN | | MILD PAIN | | MODERATE PAIN | | MODERATE PAIN | | SEVERE PAIN | | WORST PAIN POSSIBLE |
- How long it took in days for the patient to walk normally after operation?
 - How many days did it take to return to his normal activity after operation?
 - Did the patient had any limp after surgeryyes/no
 - If yes, for how many days
 - Did he use any walking aid (walking stick, wheel chair)
 - Whether or not the patient continued to experience walking problems after the first 2 post-operative weeks and for how long
 - Is there any numbness over the operated site and lower limb after the operation?
 - Was there any problem with the scar (like any infection, irritation, persistent ache)?
 - Are you satisfied with the appearance of the scar over the hip?
SATISFIED/ UNSATISFIED

[Table/Fig-1]: questionnaire for evaluating post-operative complications



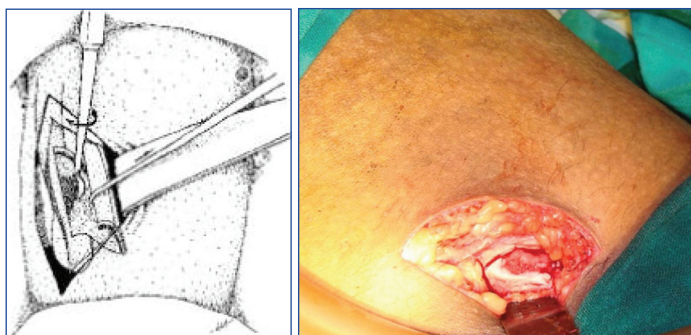
[Table/Fig-2]: A: Illustration of the marking of incision; B: Marking of the incision intra operatively on right anterior iliac region

to descriptive statistics which included maximum, minimum, mean, median, and standard deviation for each study variable.

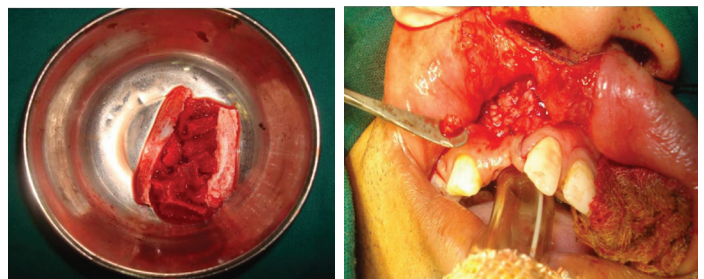
SURGICAL TECHNIQUE

All surgeries were performed by a single surgeon with assistance taken from colleagues, by medial trap door technique for harvesting bone from anterior iliac region. All procedures were performed under general anaesthesia in supine position allowing simultaneous preparation at the recipient site. Pre-operative antibiotics were given to all the patients. Under aseptic conditions, orotracheal intubation was done and procedure was performed simultaneously at donor and recipient sites. At the donor site, the iliac crest was palpated, and with the non-surgical hand the skin over the crest was displaced medially before the incision was made (for aesthetic reasons and to avoid irritation of scar from tight clothes). The area of the iliac crest was infiltrated using 2% lignocaine containing 1:1,00,000 adrenaline.

Incision was placed 2cm away from the anterior superior iliac spine [Table/Fig-2a, 2b], over the displaced skin measuring about 3-5 cm avoiding damage to the lateral femoral cutaneous nerve and damage to the growth centre (anterior iliac spine). Dissection was continued following the axis of the iliac crest through the subcutaneous tissues and fascialata directly over the crest with minimal undermining. A medially based trap door was outlined with anterior and posterior vertical stop cuts creating a hinge joint medially [Table/Fig-3a, 3b]. Then blocks of cancellous bone was harvested using a small osteotome and a bone gouge. After sufficient amount of bone graft was taken around 20–30cc, it was transferred to the recipient site simultaneously [Table/Fig-4a, 4b]. Then, the whole area was

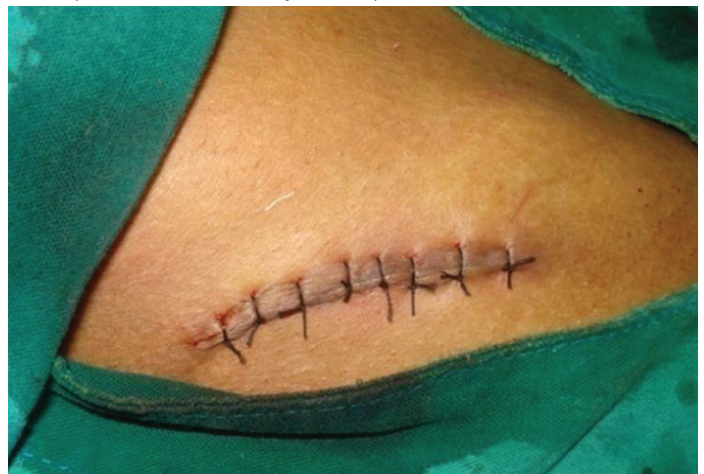

[Table/Fig-3]: A: Illustration of medial trap door technique; B: Intra operative image showing medial trap door technique



[Table/Fig-4]: A: Collected bone graft from anterior iliac region; B: Placement of harvested bone graft at the recipient site.

irrigated, haemostasis achieved. The trap door was repositioned and if required it is secured using resorbable sutures. Then the incision was closed in layers using 3-0 vicryl and 3-0 silk for skin [Table/Fig-5]. The incision was covered by a compression plaster under pressure to avoid any dead space



[Table/Fig-5]: Surgical site closure

POST-OPERATIVE CARE

Patients were encouraged to mobilise on the second post-operative day with support from the assistants or nursing staff. Patients were advised to maintain oral hygiene and not to strain over the operated area for at least two weeks and avoid any strenuous physical activities (like running, jumping, weight lifting and sports) for minimum of 3-6 months post-operatively.

RESULTS

Out of the 40 subjects included in the study 8 subjects were of less than 10 years of age, 25 subjects were in the range of 11 to 20 years and 7 subjects were in the range of 21 to 30 years. Eleven subjects had bilateral cleft alveolus and 29 subjects had unilateral cleft alveolus (11 had on right side and 18 on the left side). The age at the time of surgery ranged from 8 to 30 years. The follow up period varied from 3 months to 4 years prospectively [Table/Fig-6].

Age Range	No. of Subjects	M:F Ratio	No. of Unilateral Cleft Subjects	No. of Bilateral Cleft Subjects
1-10	8	6:2	9	2
11-20	25	19:6	16	6
21-30	7	6:1	4	3

[Table/Fig-6]: Demographic Data

Pain Experience

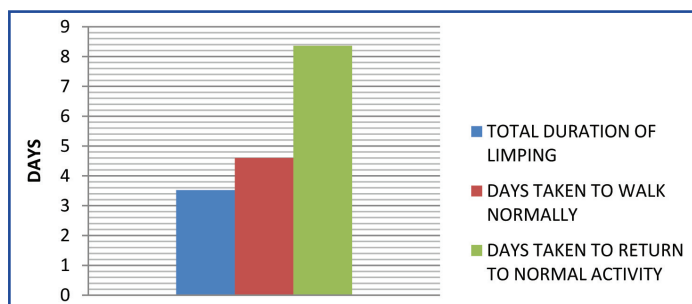
All the patients suffered from pain. The average duration of pain is around 6.32 ± 0.9 days. Visual analogue scale was used to assess the severity of pain and the mean grading was around 7.68 ± 0.47 and pain in the hip region is more when compared to the oral region.

Gait Disturbances

Patients were encouraged to walk after first 24 hours post-operatively with the help of assistant or nursing staff. All the patients had mild to moderate gait disturbances post-operatively. The average duration of limping was 3.52 ± 1.38 days, and period taken to walk normally was 4.6 ± 1.41 days. The number of days taken to return to normal activity was 8.36 ± 1.93 days. No patient experienced any gait disturbances two weeks post-operatively [Table/Fig-7, 8].

Variable	Mean	Median	SD	Maximum	Minimum
Duaration of Pain	6.32	7	0.9	8	5
Severity of Pain (Vas)	7.68	8	0.47	8	7
Total Duration of Limping in Days	3.52	3	1.38	6	2
Days Taken to Walk Normally	4.6	4	1.41	7	3
Days Taken to Return to Normal Activity	8.36	8	1.93	15	6

[Table/Fig-7]: Measured variables for mean, median & standard deviation



[Table/Fig-8]: Gait Evaluation

	Percentage
Scar Satisfaction	92%
Use of any Walking Aid	20%

[Table/Fig-9]: Percentage of some variables used for the study

Paresthesia and Infection

None of the patients complained about any paresthesia or any infections in the donor site during the follow up appointments.

Scar and Patient's Satisfaction

92% the patients were satisfied with the post-operative scar which

was hidden lateral to the hip.

DISCUSSION

The use of autogenous bone graft from the anterior iliac crest was proven to be "gold standard" for SABG and it is well established [1–4]. The iliac crest provides suitable site for augmentation because of its abundant cancellous bone and for its osteoconductive and osteoinductive properties. However, the autogenous bone grafts are known to be associated with many post-operative complications from mild to moderate degree but with shorter duration such as infection, inguinal and liver hernia, [10] nerve injury, [11] gait abnormality [12–14]. Peritoneal tear, sensory loss and paresthesia and rare complications like iliac abscess [15]. Complications can be associated depending on the harvesting technique or the method used [16]. Harvesting bone from iliac crest through medial trap door technique using the anterior approach by dissecting the gluteus medius and tensor fascialata was well tolerated by all the patients with low morbidity rate. None of the patients suffered major noticeable complications, all the patients tolerated with less morbidity.

The post-operative pain and discomfort are assessed by the visual analogue scale of 0 – 10. Where, '0' indicates no pain and '10' as severe pain. And the results of the present study show deviation of pain maximum as 8 and minimum as 5.

Gait disturbance is the most common complication observed next to pain. Previous studies by Rawashdeh et al., [16] the average duration of limp walking was 6.6 ± 5.4 days and no patient showed gait disturbance four weeks post-operatively. Limping was reported in 19 patients in a study conducted by Zaid et al., [13] the post-operative limp was resolved after 10.4 days and 50% of the patients had gait disturbances even after 14th post-operative day [17]. In our study the average duration of limping was 3.5 ± 1.38 days due to pain and no patient had experienced any gait disturbance two weeks after the surgery.

Scar formation studies suggests [1] 92% patients were pleased with the aesthetic outcome of the scar when a length of incision was from 30–50 mm. Rudmann reported a mean of 29 mm [18], Canady et al., a mean of 42 mm [19] Cohen et al., [20] reported a scar length of 40 mm and Grossman et al., reported scar length of 23–46mm during follow up of 9–12 months. [21] However in our study 90% of patients were satisfied with the postoperative scar.

In a study conducted by Pollock R et al., [22] on donor site morbidity, cosmesis and overall satisfaction with iliac crest bone graft for anterior cervical discectomy and fusion, they found no major complications in trephine group and open group patients with no statistically significant difference in morbidity.

In a similar study conducted by Matsa S et al., [23] on evaluation of morbidity associated with iliac crest harvest for alveolar cleft bone grafting, they found that young patients have increased tolerance Temporary sensory loss or post-operative sensory disturbances i.e., parasthesia were reported [2,4]. None of the patients in the present study complained about any paresthesia in the donor site or limb region (100%) during follow up of three months and further, compared to other studies which reported 22.7% sensory disturbances [3].

Unusual complications like delayed iliac abscess may occur which was reported by De Riu G et al., [15] due to the foreign body granuloma stimulated by the bone wax generously spread to the harvesting site of the bone, which was not observed in any of our cases.

CONCLUSION

SABG in cleft patients using iliac bone gives adequate amounts of corticocancellous bone which has osteoconductive and inductive

properties. It gives adequate amount of graft material sufficient enough for unilateral or bilateral cleft alveolus cases. But still a study with large series of cases will provide more sound data to assess post-operative morbidity of anterior iliac crest is required. The present study supports the view that iliac crest continues to be a unique donor site for secondary alveolar bone grafting with better patient compliance.

REFERENCES

- [1] Albert A, Leemrijse T, Druet V, Delloye C, Cornu O: Are bone autografts still necessary in 2006? A three-year retrospective study of bone grafting: *Acta Orthop Belg.* 2006; 72(6):734-40.
- [2] Sen MK, Miclau T: Autologous iliac crest bone graft: should it still be the gold standard for treating non unions? : *Injury.* 2007; 38(Suppl 1):S75-80.
- [3] Heidrun Schaaf, Stefan Lendeckel, Hans-Peter Howaldt Donor site morbidity after bone harvesting from the anterior iliac crest *Oral Surg Oral Med Oral Pathol Oral Radiol Endod.* 2010;109:52-58.
- [4] Eufinger H, Leppanen H: Iliac crest donor site morbidity following open and closed methods of bone harvest for alveolar cleftosteoplasty: *J Craniomaxillofac Surg.* 2000; 28(1):31-8.
- [5] Mazock JB, Schow SR, Triplett RG: Posterior iliac crest bone harvest: Review of technique, complications and use of an epidural catheter for postoperative pain control. *J Oral Maxillofac Surg.* 2003; 61: 1497- 1503.
- [6] Kager AN, Marks M, Bastrom T, Newton PO: Morbidity of iliac crest bone graft harvesting in adolescent deformity surgery. *J Pediatr Orthop.* 2006; 26: 132-134.
- [7] Kessler P, Thorwarth M, Bloch-Birkholz A, Nkenke E, Neukam FW: Harvesting of bone from the iliac crest: a comparison of the anterior and the posterior sites. *Br J Oral Maxillofac Surg.* 2005; 43: 51-56.
- [8] Freilich MM, Sandor GK: Ambulatory in-office anterior iliac crest bone harvesting. *Oral Surg Oral Med Oral Pathol Oral Radiol Endod.* 2006; 101: 291-98.
- [9] Swan MC, Goodacre TE: Morbidity at the iliac crest donor site following bone grafting of the cleft alveolus: *Br J Oral Maxillofac Surg.* 2006; 44:129.
- [10] T. Nodarian, E. Sariali, F. Khiami, H. Pascal-Mousselard, Y. Catonné Iliac crest bone graft harvesting complications: A case of liver herniation: *Orthopaedics & Traumatology: Surgery & Research* (2010) 96, 593–96.
- [11] Mischkowski RA, Selbach I, Neugebauer J, Koebke J, Zöllner JE: Lateral femoral cutaneous nerve and iliac crest bone grafts: anatomical and clinical considerations. *Int J Oral Maxillofac Surg.* 2006; 35: 366e372.
- [12] Arrington ED, Smith WJ, Chambers HG, et al. complications of iliac crest bone graft harvesting. *Clin orthop.* 1996; 329: 300-09.
- [13] Zaid H. Baqain, Mohammed Anabtawi, Ashraf Abu Karaky, Ziad Malkawi; Morbidity From Anterior Iliac Crest Bone Harvesting for Secondary Alveolar Bone Grafting: An Outcome Assessment Study: *J Oral Maxillofac Surg.* 2009; 67:570-75.
- [14] Kolomvos N, et al. Iliac crest morbidity following maxillofacial bone grafting in children: A clinical and radiographic prospective study, *J Craniomaxillofac Surg.* 2010 Jun;38(4):293-302.
- [15] G. De RIU, S.M. Meloni, M.T. Raho, R Gobbi, Tullio: delayed iliac access as an unusual complication of an iliac bone graft in an orthognathic case: *Int. J. oral Maxillofac. Surg.* 2008; 37: 1156 – 58.
- [16] M. A. Rawashdeh: Morbidity of iliac crest donor site following open bone harvesting in cleft lip and palate patients. *Int. J. Oral Maxillofac. Surg.* 2008; 37: 223–27.
- [17] Nicole Falkensammer, Robert Kirmeier, Et Al: Modified Iliac Bone Harvesting – Morbidity And Patients Experience: *J Oral Maxillofac Surg.* 2009; 67: 1700- 05.
- [18] Rudman RA: Prospective evaluation of morbidity associated with iliac crest harvest for alveolar cleft grafting. *J Oral Maxillofac Surg.* 1997; 55:219.
- [19] Canady JW, Zeitler DP, Thompson SA, et al: Suitability of the iliac crest as a site for harvest of autogenous bone grafts. *Cleft Palate Craniofac J.* 30:579, 1993.
- [20] Cohen M, Figueroa AA, Haviv Y, Schafer ME, Aduss H. Iliac versus cranial bone for secondary grafting of residual alveolar clefts. *Plast Reconstr Surg.* 1991; 87:423–27.
- [21] Grossman MG, Ducey SA, Nadler SS, Levy AS: Meralgia paresthetica: diagnosis and treatment. *J Am Acad Orthop Surg.* 2001; 9: 336-44.
- [22] Pollock R, Alcelik I, Bhatia C, Chuter G, Lingutla K, Budithi C, Krishna M. Donor site morbidity following iliac crest bone harvesting for cervical fusion: a comparison between minimally invasive and open techniques. *Eur Spine J.* 2008;17:845-52.
- [23] Matsa S, Murugan S, Kannadasan K. Evaluation of morbidity associated with iliac crest harvest for alveolar cleft bone grafting. *J Maxillofac.Oral.Surg.* 2012;11:91-95.

PARTICULARS OF CONTRIBUTORS:

1. Professor, Department of Oral and Maxillofacial Surgery, Mamata Dental College, Khammam, India.
2. Reader, Department of Oral and Maxillofacial Surgery, Mamata Dental College, Khammam, Andhrapradesh, India.
3. Reader, Department of Oral and Maxillofacial Surgery, Mamata Dental College, Khammam, Andhrapradesh, India.
4. Professor and Head, Department of Oral and Maxillofacial Surgery, Mamata Dental College, Khammam, Andhrapradesh, India.
5. Post Graduate, Department of Oral and Maxillofacial Surgery, Mamata Dental College, Khammam, Andhrapradesh, India.

NAME, ADDRESS, E-MAIL ID OF THE CORRESPONDING AUTHOR:

Dr. Nandagopal Vura,
Professor, Department Of Maxillofacial Surgery, Mamata Dental College, Khammam, Andhrapradesh, India.
Phone: +91 9908296688, E-mail: vura_gopal@yahoo.co.uk

Date of Submission: **Sep 01, 2013**
Date of Peer Review: **Sep 29, 2013**
Date of Acceptance: **Oct 14, 2013**
Date of Publishing: **Nov 10, 2013**

FINANCIAL OR OTHER COMPETING INTERESTS: None.