

# Morphometric Study of Left Coronary Artery Trunk in Adult Human Cadavers: A Study on the Eastern Region Population

SANCHITA ROY<sup>1</sup>, AVANISH GUPTA<sup>2</sup>, BALJIT KAUR NANRAH<sup>3</sup>, MINAKSHI VERMA<sup>4</sup>, RITABAN SAHA<sup>5</sup>

## ABSTRACT

**Introduction:** The left coronary artery shows a wide range of morphological variations which has great clinical importance. Difficulties may occur during performance of diagnostic procedures, especially in patients who undergo evaluation of percutaneous coronary interventions or during coronary artery surgeries or prosthetic valve replacements. Even, it has been found that short length of main left coronary artery was one of the congenital factors which predisposed to the development of coronary artery disease. The aim of this work was to determine the variations in the origin, length and divisions of the left coronary artery trunk in the eastern region population of India.

**Materials and Methods:** The present study was carried out on 100 heart samples which were collected from a mixed race population group from West Bengal, India, after preserving them in 10% formalin solution. While carefully maintaining all standard

precautions, scientifically well-planned cadaveric dissections were done and variations were noted.

**Results:** It was found that in all specimens, left coronary artery arose from single ostia at the left posterior aortic sinus. In about 65% cases, ostia was below or at the sinotubular junction (STJ) and in a significant number (35%) of cases, it is above the level of STJ. The mean length of the left coronary artery trunk was found to be  $11.42 \pm 4.98$  mm. LMCA were bifurcated in 56% cases, they were trifurcated in 40% cases and they were tetrafurcated in 2% cases. The results were compared with those of other studies, which showed considerable variations.

**Conclusion:** Thus, this morphometric study done on left coronary artery trunk in the eastern Indian population will be helpful for interventional cardiologists and radiologists for avoiding inadvertent vascular trauma during diagnostic and therapeutic procedures.

**Keywords:** Ostia, Sinotubular junction (STJ), Left posterior aortic sinus

## INTRODUCTION

In the normal heart, oxygenated blood is supplied by two coronary arteries that arise from the ascending aorta. The LMCA originates from the left posterior aortic sinus and it runs towards left, under the left auricle. After a short course, it divides into two vessels, left anterior descending artery and circumflex artery [1]. The left coronary artery trunk presents a wide variability in its morphological expression with regards to its length, level of origin and number of terminal branches. Even the angiographic measurements of coronary artery length are probably less accurate than those seen in post-mortem pathologic studies, due to their under estimation by the effects of rotation angulation and foreshortening [2]. There is a correlation between the length of the main left coronary artery and the atherosclerosis present in its branches or the presence of a complete left bundle branch block [3]. Thus, the knowledge on such variations is important for evaluation of percutaneous coronary artery interventions, coronary artery surgeries or prosthetic valve replacements and last but not the least, for its academic value among upcoming clinicians.

## MATERIALS AND METHODS

From the Department of Forensic Medicine, IPGMER, Kolkata, India. hundred specimens of heart were collected by cutting ribs and sterna and opening of thoracic cavities of the cadavers. The great vessels, ascending aortas and pulmonary trunks were ligated by using threads at two places and they were then cut in between the two ligatures. The parietal pericardium was incised and the heart, along with the proximal part of the great vessels, was taken out of the pericardial cavity. Then, the aorta and the pulmonary trunk were excised about 2 cm above the supra-avalvular ridge. All the collected samples were kept in 10% formalin. After a gradual separation and retraction of the myocardial fascicule, the

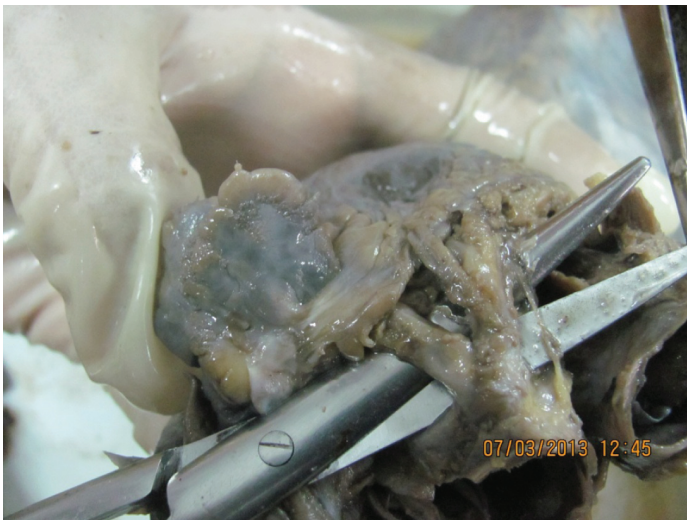Level of Left Coronary Ostium	Numbers	Percentage
Below STJ	33	33%
At STJ	31	32%
Above STJ	34	35%
Total	98	100%

[Table/Fig-1]: Level of left coronary ostium

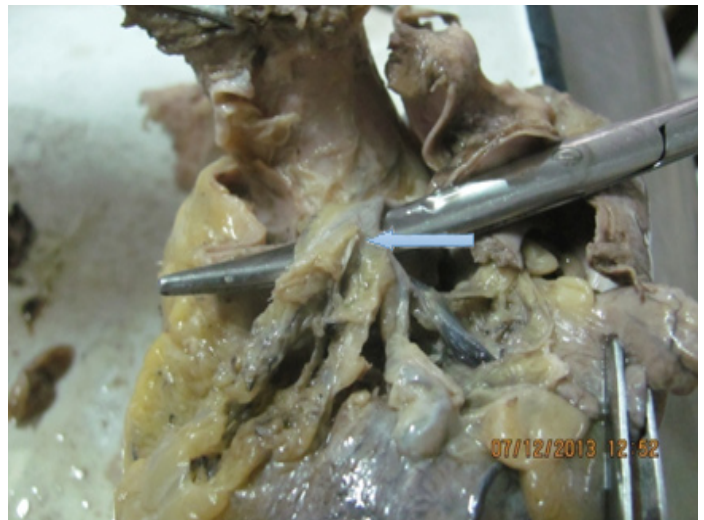left coronary artery was exposed. The length of the main trunk was measured by using a vernier calliper as has been described in [Table/Fig-1] and the branching patterns were noted. The ascending aorta was cut longitudinally (near the Rt posterior non coronary sinus) to check the position, number and level of the left coronary ostium. A statistical analysis was performed by using SPSS (Statistical Package for Social Sciences), version 15.0. The values were represented in number (%) and Mean  $\pm$  Standard deviation.

## RESULTS

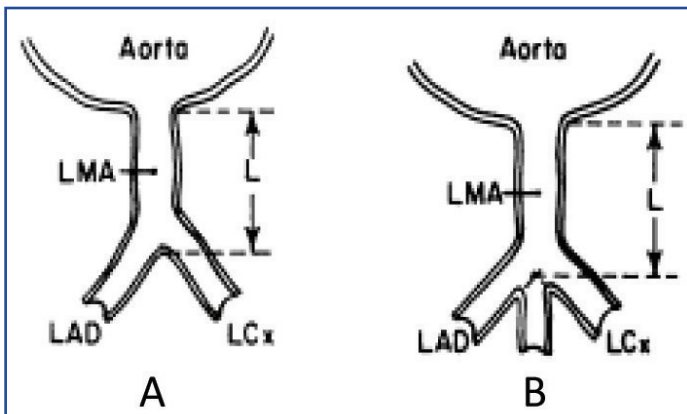
Among 100 samples, 2 were discarded due to severe putrefaction. On dissecting the rest of the cadaveric heart samples, the left coronary artery trunk was found to originate from left posterior aortic sinus in all the cases. The level of ostium was different in relation to STJ (junctional zone between sinuses and tubular part of ascending aorta), which has been shown in [Table/Fig-2]. From the table, it is evident that in a large number of cases (35%), it originated above the level of STJ. In relation to the branching pattern of LMCA, we found bifurcations in 57 samples, i.e., 56% cases, trifurcations in 39 cases, i.e., 40% and in 2 cases, quadrifurcations were seen. In our samples, we did not find any penta-furcations. The mean length of the left coronary artery trunk was found to be  $11.42 \pm 4.98$  mm, the range being 0.5–21.5 mm [Table/Fig-3].



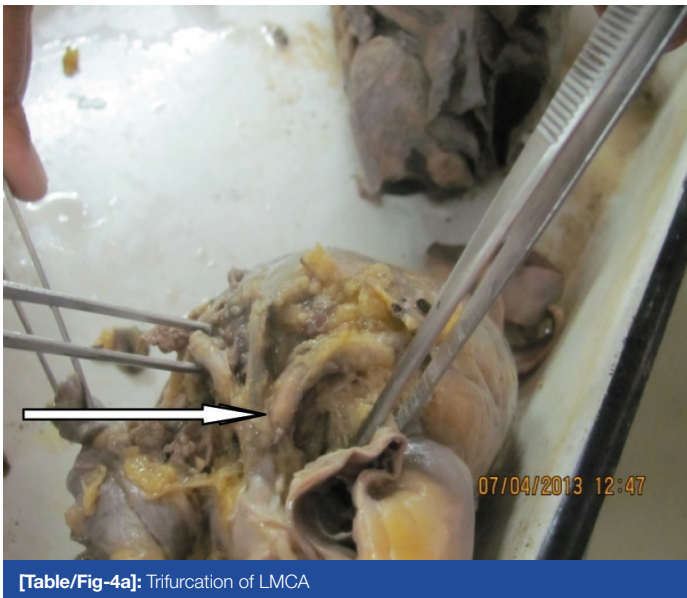[Table/Fig-2]: Short length of left main coronary artery



[Table/Fig-4b]: Tetrafurcation of LMCA



[Table/Fig-3]: Schematic diagrams of cross section through ascending aorta and left coronary artery. In A length (L) of left main coronary artery (LMA) is from outer aortic wall to site of bifurcation into Left ant descending (LAD) and left circumflex (LCX) branches. In B, length of LMA when trifurcation occurs



[Table/Fig-4a]: Trifurcation of LMCA

## DISCUSSION

Sound knowledge on basic anatomy of LCA has recently been emphasized due to increasing use of diagnostic and therapeutic interventional procedures.

The location and level of the ostia are very important for the successful performance of a coronary angiogram during manipulation of the catheter tips. Difficulties may arise more considerably in patients in whom the ostium is above the level of sinotubular ridge (Taylor

and Thorne) [4]. Banchi A [5] reported that the LCA arose at the level of free margin of aortic cusps in 48% cases, above it in 34% cases and below it in 18% cases. A study done by Kalpana R [6] revealed that the ostium was below the STJ in 80% cases and at STJ level in 20% cases. A study done by Dombe DD et al., [7] found that the level of ostium was below STJ in quite a large number of specimens (around 79.7%), whereas it was at the same level as it in 17.2% cases and above its level in only 3.1% cases. In our study, it was found that the level of ostia above the STJ was 35%, at 32% and that its level below STJ was 33%. Slit like ostia were seen in a number of cases. There have been reported cases of sudden deaths which had occurred in young individuals, where during autopsy, left sided ostial opening was found to be slit like [8].

Normally, there is only one ostium in the left posterior aortic sinus for the LCA [Table/Fig-4a,4b]. But multiple ostia were reported in the left posterior aortic sinus. Cavalcanti [9] described that in about 1.82% of the specimens, the circumflex artery and anterior descending artery arose directly from the aorta. Study done by Dombe DD et al., also showed separate origins of these two branches in one sample [7]. Topaz O et al., [10] suggested that recognition of this coronary ostial anomaly was necessary to ensure an accurate angiographic interpretation and that it was important for patients who underwent cardiac surgeries, where there would be selective perfusions of these separate vessels during performances of cardiopulmonary bypass. In our study, we found single ostia at the left posterior aortic sinus in all the specimens which were studied.

In the present study, the mean length of the LMCA was  $11.42 \pm 4.98$  mm, the range being .5 mm to 21.5 mm. Similar study done by Green GE et al., [11] showed that in 48% cases, the LMCA were 10mm or less in length and that in the remaining 52%, the length was upto 25 mm. A study done by Reig and Petit [12] revealed that the average length of the main trunk was  $10 \pm 5.52$ mm (range being 2-23 mm). Gazetopoulos N et al., [3] studied the relation between the length of the main left coronary artery and the degree of atherosclerosis in its branches by post-mortem examination and suggested that in cases with a short main left coronary artery, the atherosclerotic lesions in the anterior descending and circumflex branches appeared earlier, progressed faster at higher levels of severity and led more frequently to myocardial infarction than in cases with a long left coronary artery. During aortic valve surgeries, myocardial perfusion depends on the positioning of one or more cannulas in the coronary arteries. In this regards, the length of LMCA is important, because when catheter is inserted into one of the terminal branches, the opacification of the other branch will not occur and thus, an incomplete image of coronary artery tree will be found.

The division of LMCA also shows wide variations. A comparative study was done along with other previous studies and its results have been depicted in [Table/Fig-5].

Authors and year	Specimen	Branching Pattern
Baptista CA et al., [13]	100	B:60%; T:38.18% Direct LAD & LCx from ostium:1.8%
Cavalcanti JS [9]	100	B:47%; T:40%; Q:11%; P:1%
Reig J and Petit M [12]	100	B:62% Tor Q:38%
Ballesteros LE and Ramirez LM [14]	154	B:52%; T:42.2%; Q:5.8%
Das H [15]	100	B:60%; T:35%; Q:5%
Dombe DD et al., [7]	64	B:54.7%; T:35.9%; Q:7.8% Direct LAD & LCx from ostium:1.6%
Present study	98	B:60%, T:38% Q:2%

[Table/Fig-5]: Comparative study of branching pattern of LMCA

So, this study done on eastern region population of India showed similar branching pattern of left coronary artery trunk as was seen in previous studies, but it showed a high origin of LCA trunk in a significant number of cases.

## REFERENCES

- [1] Johnson D, Shah P, Collins P, Wigley C. Gray's Anatomy: The Anatomical Basis of Clinical Practice. 39<sup>th</sup> ed. Elsevier Churchill Livingstone. 2000; 1014-17.

- [2] Wilson WJ, Lee GB, Amplatz K. Biplane selective coronary arteriography via percutaneous transfemoral approach. *Am J Roentgenol Radium Ther Nucl Med.* 1967;100:332-8.
- [3] Gazetopoulos N, Ioannidis PJ, Marselos A, Kelekis D, Lolos C, Avgonstakis D, Toulatas C. Length of main left coronary artery in relation to atherosclerosis of its branches: A coronary angiographic study. *Br Heart J.* 1976;38(2):180-85.
- [4] Taylor AM, Thorne SA. Coronary artery imaging in grown up congenital heart disease complementary role of magnetic resonance and Xray coronary angiography. *Circulation.* 2000;101(14):1670-78.
- [5] Banchi A. Morphologia dela arteriae coronariae cordis. *Arch Ital Anat. E Embriol.* 1904;3:87.
- [6] Kalpana R. A Study on principal branches of coronary arteries in humans. *J Anat Soc India.* 2003;52(2):137-40.
- [7] Dombe DD, Anitha T, Giri PA, Dombe SD, Ambiyev MV. Clinically relevant morphometric analysis of left coronary artery. *Int J Biol Med Res.* 2012;3(1):1327-30.
- [8] Corrado D, Thiene G, Cocco P, Frescura C. Nonatherosclerotic coronary artery disease and sudden death in the young. *Br Heart J.* 1992;68:601-7.
- [9] Cavalcanti JS. Anatomic variations of the coronary arteries. *Arq Bras Cardiol.* 1995;65(6):489-92.
- [10] Topaz O, Disciascio G, Cowley MJ, Soffer A, Lanter P, Goudrean E, et al. Absent left main coronary artery angiographic findings in 83 patients with separate ostia of the left descending and circumflex arteries at the left aortic sinus. *Am Heart J.* 1991;122:447-52.
- [11] Green GE, Bernstein S, Reppert EH. The length of the left main coronary artery. *Surgery.* 1967 Dec;62:1021-24.
- [12] Reig J, Petit M. Main trunk of the left coronary artery: Anatomic study of the parameters of clinical interest. *Clinical Anatomy.* 2004;17:6-13.
- [13] Baptista CAC, Dido LJA, Prates HC. Types of division of the left coronary artery and the ramus diagnosis of human heart. *Jap Heart J.* 1991;32:323-35.
- [14] Ballesteros LE, Ramirez LM. Morphological expression of the left coronary artery: A direct anatomical study. *Folia Morphol.* 2008;67(2):135-42.
- [15] Das H. Termination of left coronary in the population of Assam. *National Journal of Basic Medical Sciences.* 2005;1(3):145-48.

### PARTICULARS OF CONTRIBUTORS:

1. Assistant Professor, Department of Anatomy, IPGME&R, Kolkata, India.
2. Assistant Professor, Department of Anatomy, IPGME&R, Kolkata, India.
3. Assistant Professor, Department of Anatomy, IPGME&R, Kolkata, India.
4. Assistant Professor, Department of Anatomy, V.C.S.G. Government Medical College, Uttarakhand, India.
5. Demonstrator, Department of Anatomy, IPGME&R, Kolkata, India.

### NAME, ADDRESS, E-MAIL ID OF THE CORRESPONDING AUTHOR:

Dr. Sanchita Roy,  
207A/2, Garfa Main Road, Kolkata-700078, West Bengal, India.  
Phone: 9831767953, E-mail: doctor\_sanchita@yahoo.co.in

FINANCIAL OR OTHER COMPETING INTERESTS: None.

Date of Submission: **Sep 9, 2013**  
Date of Peer Review: **Nov 9, 2013**  
Date of Acceptance: **Dec 19, 2013**  
Date of Publishing: **Feb 03, 2014**