

Morphometric Study of Suprascapular Notch in Indian Dry Scapulae with Specific Reference to the Incidence of Completely Ossified Superior Transverse Scapular Ligament

USHA KANNAN¹, N.S.KANNAN², J.ANBALAGAN³, SUDHA RAO⁴

ABSTRACT

Background: The suprascapular notch, a depression on the lateral part of the superior border of the scapula, medial to the coracoid process, is bridged by the superior transverse scapular ligament, which is sometimes ossified and the foramen which is thus completed, transmits the suprascapular nerve to the supraspinatus fossa. Variations in the morphology of suprascapular notch have been identified as one of the causes of suprascapular nerve entrapment. Rengachary et al. classified this notch into six types, based on its shape.

Aim of Study: To study morphological variations of suprascapular notch in Indian dry scapulae and to analyze the incidence of completely ossified superior transverse scapular ligament with other ethnic populations which have been cited earlier.

Materials and Methods: A total of 400 human dry scapulae which were obtained from the Department of Anatomy of selected

eight medical colleges were analyzed. The type of suprascapular notch was noted and it was recorded as per the description given by Rengachary et al. The results of the present study were compared with the results of previous authors in different populations.

Results: In our study, out of 400 scapulae, 40 (10%), were identified to have completely ossified superior transverse scapular ligaments. The frequencies of various types of suprascapular notches were: Type I -20%, Type II -10%, Type III -52%, Type IV -4%, Type V -4%, Type VI -10%.

Conclusion: Since the suprascapular nerve entrapment syndrome might be caused by complete ossification of superior transverse scapular ligament with formation of suprascapular foramen and other morphometric variations of suprascapular notch, the knowledge on such variations is essential for clinicians, for making a proper diagnosis and for planning the most suitable surgical intervention.

Keywords: Suprascapular notch, Suprascapular nerve, Superior transverse scapular ligament, Suprascapular foramen

INTRODUCTION

The suprascapular notch (SSN) is a depression on the lateral part of the superior border of the scapula, medial to the coracoid process. This structure is bridged by the superior transverse scapular ligament (STSL), which is sometimes ossified and the foramen which is thus completed, transmits the suprascapular nerve (SN) to the supraspinatus fossa [1,2]. Suprascapular nerve supplies motor branches to the muscles supraspinatus and infraspinatus, and sensory branches to rotator cuff muscles, and ligamentous structures of the shoulder and acromioclavicular joints. Accordingly, this notch is an important landmark of the suprascapular nerve during arthroscopic shoulder operations [3,4].

Furthermore, variations in the morphology of suprascapular notch have been identified as one of the causes of suprascapular nerve entrapment [5]. Rengachary et al., [6-8], classified this notch into six types, based on its shape and they also stated that the size of the suprascapular notch played a role in the predisposition for suprascapular nerve entrapment. In their opinion, a small notch gave a greater chance of a nerve impingement than a large one. One of the clinically most important places on the scapula is the suprascapular notch. The suprascapular nerve and vein run below this superior transverse scapular ligament, and above the ligament passes suprascapular artery [9-12].

Morphological variations of the suprascapular notch are very-important clinically for possible predisposing factors, for compression of the suprascapular nerve in this region. In the whole population, approximately 1-2% all shoulder pain is caused by the

suprascapular nerve entrapment syndrome [13]. Suprascapular nerve entrapment was first described by Kopell and Thompson [14]. The result of suprascapular nerve entrapment is weakness of the arm, difficulty in external rotation and abduction, and then, atrophy of the infraspinatus and supraspinatus muscles. This entrapment syndrome is most frequently found in volleyball players and athletes who repeatedly experience stress on their shoulder. These include baseball players, weight lifters, tennis players, fencers, hunters using bows, dancers, figure skaters and individuals with occupations which require a lot of overhead work which requires extreme abduction and external rotation [15-19].

The suprascapular notch type, apart from the anatomical interest, may have some clinical significance for suprascapular nerve entrapment [20-22]. The size and shape of the suprascapular notch may be a factor in suprascapular nerve entrapment, because narrow suprascapular notches have been found in patients with this syndrome [23-28].

Aim of study

To study morphological variations of suprascapular notch in Indian dry scapulae and to analyze the incidence of completely ossified superior transverse scapular ligament with other ethnic populations which have been cited earlier.

MATERIALS AND METHODS

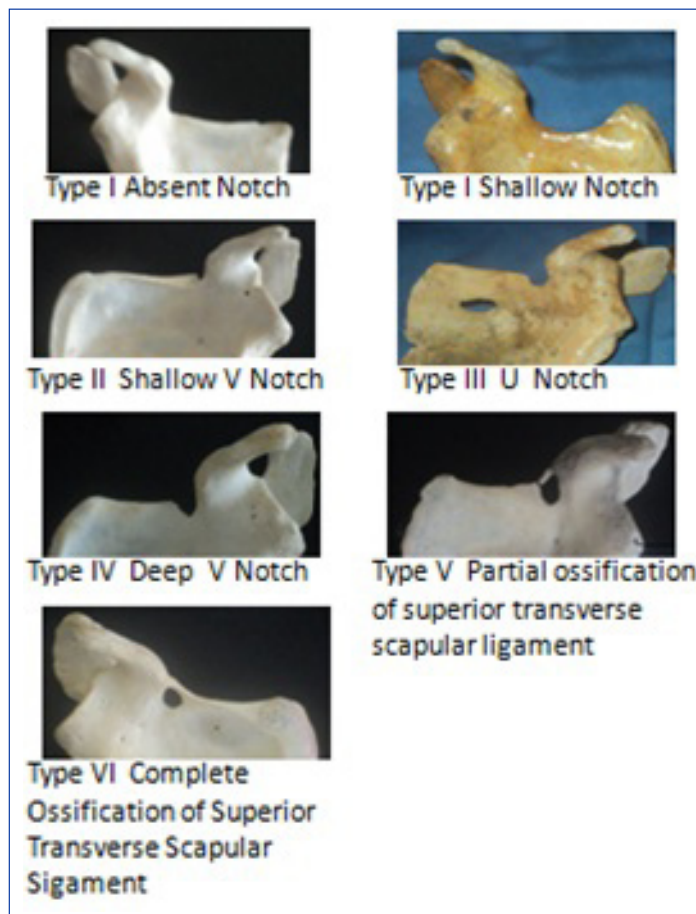
A total of 415 human scapulae of unknown ages and sexes, which were collected from the Department of Anatomy of Mahatma Gandhi

Medical College and Research Institute and other medical colleges in and around Pondicherry, India, were analyzed after obtaining consents and permissions from the heads of the institutions and anatomy departments for the study. Broken scapulae which were 15 in number, were excluded. The study was conducted between March 2013 and September 2013. Representative photographs of various types of suprascapular notches along the superior borders of the scapulae, were taken by using a digital camera (Sony 12.1 Mega pixels) and they were documented.

We followed the classification which was stated by Rengachary et al., [6-8]: Type I –complete absence of notch. Type II -wide blunted V shaped notch occupying a third of superior border of scapula. Type III -symmetrical and U shaped notch with parallel lateral margins. Type IV -small V shaped notch. Type V -U shaped notch with partial ossification of medial part of suprascapular ligament. Type VI -complete ossified ligament with bony foramen of variable size. He also suggested that various transitions existed between these types of notches.

RESULTS

In the present study out of 400 scapulae, 40 (10%) scapulae were found to have completely ossified superior transverse scapular ligaments. Representative photographs of various notch types in our study are shown in [Table/Fig-1]. On analysis of morphological variations of suprascapular notch, we found: Type I -20%, Type II -10%, Type III -52%, Type IV -4%, Type V- 4%, Type VI -10%. [Table/Fig-2].



[Table/Fig-1]: Representative photographs of the various notch types from our study, as per Rengachary's classification

Type	Type I	Type II	Type III	Type IV	Type V	Type VI
Number of Scapulae	80	40	208	16	16	40
Percentage	20%	10%	52%	4%	4%	10%

[Table/Fig-2]: The frequency of various types of suprascapular notch as per Rengachary's classification in our study [6-8]

DISCUSSION

The incidence of completely ossified superior transverse scapular ligaments in our present study was 10% and ranges of 10.57%

Serial No.	Author (year of study)	Total No. of Scapulae Studied	No. Scapulae with suprascapular foramen	(n=17) Percentage
1	G Soni [28]	100	3	3%
2	Khan M A et al., [29]	Single case report		
3	Das et al., [30]	Single case report		
4	Iqbal et al., [31]	250	0	0%
5	Muralidhar Reddy [32]	104	2	1.93%
6	Vyas et al., [33]	300	11	3.67%
7	Kalpana et al., [34]	100	2	2%
8	Pragna et al., [35]	80	3	3.75%
9	Vandana and Sudha et al., [36]	134	17	12.6%
10	Jadhve et al., [25]	350	37	10.57%
11	Present study	400	40	10%

[Table/Fig-3]: Comparative statement of incidence of completely ossified superior transverse scapular ligament in Indian population studied by different authors

Serial No	Author	Population	Percentage of suprascapular foramen
1.	Kajava [37]	Finnish (133)	1.5%
2.	Olivier [38]	French	5-6.5%
3.	Vallois [39,40]	French (200) Italian (200)	6.5% 6.1%
4.	Ticker et al., [41]	American (79)	1.27%
5.	Edelson [42]	American (700)	3.7%
6.	Natsis et al., [43]	Greek (423)	6%
7.	Sinkeet et al., [44]	Kenyan (138)	4%
8.	Urgüden et al., [45]	Turkish (120)	6%
9.	Bayramoglu et al., [46]	Turkish (36)	12.5%
10.	Wang HJ et al., [47]	Chinese (295)	1.36%
11.	DJ Gray [48]	American & Europeans (1,151)	6.34%
12.	DJ Gray [48]	Brazilian (221)	30.76%
13.	Poirier and Charpy et al., [50]	French(60)	5%
14.	Osuagwu et al., [51]	Nigerian	Single case report
15.	R Shane et al., [26]	American (79)	3.7%
16.	Hrdicka [21]	Native America (2792)	2.1-2.9%
17.	Rengachary et al., [6-8]	American (211)	4%
18.	M. Polguj et al., [13]	Poland(86)	7%
19.	Paolo Albino et al., [27]	Italian (500)	3.6%
20.	Present study	Indian (400)	10%

[Table/Fig-4]: Comparative statement of Incidence of suprascapular foramen in different population studied by different authors

and 12.6% have been reported by Vandana and Sudha et al., [36] and Jadhve et al., [28] [Table/Fig-3]. However, Muralidhar Reddy et al., [32], G Soni et al., [28], Vyas et al., [33], Kalpana et al., [34] and Pragna et al., [35] have reported lesser incidences, i.e., 1.93% to 3.75%. The incidence of suprascapular foramen in Indian dry

scapulae was relatively significant in comparison to those seen in other ethnic studies. This observation was significant as compared to those of other studies done on various ethnic populations. It has been reported to be more in Brazilian (30.76%) population, followed by Turkish (12.5%) and American (6.5%) populations [Table/Fig-4].

Ticker et al., [41] classified suprascapular notch on basis of morphological appearance as U and V. Iqbal et al., [21] reported three types of suprascapular notches, based on their shapes, 'U', 'V', 'J' on gross examination, following the observations cited by Bayramoglu et al., [46], Hrdicka [21]. Nastis et al., [43] distinguished V notch on the basis of vertical and transverse diameter measurements and Polguy et al., [13] used geometrical parameters for assessment of V shape suprascapular notch. In our present study, we applied the classification of six types of suprascapular notches, which was stated by Rengachary et al., Morphological classification of suprascapular notch in the present study represented Type III (52%) more, followed by Type I, Type IV and Type VI. Since no uniform standard of classification was followed by different authors, it was difficult to do a reasonable comparative study on the reports of various authors. However, we compared our results with those of few authors who also followed Rengachary's classification [Table/Fig-5]. Our results were in accordance with reports of Muralidhar et al., in Indian population and similar findings on Americans, Kenyans and Italians, which were reported by Rengachary et al., [6-8], Sinkeet et al., [44] and Paolo et al., [27].

Numbers	Population (n)	Type I	Type II	Type III	Type IV	Type V	Type VI
Rengachary et al., [6-8]	American (211)	8%	31%	48%	3%	6%	4%
Sinkeet et al., [44]	Kenyan (138)	22%	21%	29%	5%	18%	4%
Muralidhar [32]	Indian (104)	21.15%	8.65%	59.61%	2.88%	5.76%	1.93%
Paolo Albino et al., [27]	Italian (500)	12.4%	19.8%	22.8%	31.1%	10.2%	3.6%
Present study	Indian (400)	20%	10%	52%	4%	4%	10%

[Table/Fig-5]: Frequency of various types of suprascapular notch (SSN) in different populations

CONCLUSION

Since the suprascapular nerve entrapment syndrome might be caused by complete ossification of superior transverse scapular ligament with formation of suprascapular foramen and other morphometric variations of suprascapular notch, the knowledge on such variations is essential for clinicians, for making a proper diagnosis and for planning the most suitable surgical interventions. Further detailed ventures like: (a) clinical screening of high risk population by specialists of community medicine, sports medicine, orthopaedicians and general surgeons for the incidence of suprascapular nerve entrapment syndrome, (b) confirmation of suprascapular nerve entrapment syndrome by radiologists by using imaging modalities like MRI, CT and Ultrasound and (c) surgical interventions for either open or laparoscopic suprascapular nerve entrapment syndrome, coupled with histopathological studies on suprascapular nerve may throw fresh information on this issue.

ACKNOWLEDGEMENTS

We duly acknowledge with thanks, the cooperation rendered by the Deans/Directors and H.O.D.s of Anatomy Departments of the following Medical Colleges in Pondicherry for permitting us to study the scapulae which were available in their bone labs.

1. Aarupadai Veedu Medical College, India.
2. Indira Gandhi Medical College and Research Institute, India.

3. Pondicherry Institute of Medical Sciences and Research, India.
4. Sri Lakshmi Narayana Institute of Medical Sciences, India.
5. Sri Manakula Vinayagar Medical College and Hospital, India.
6. Sri Venkateswara Medical College, Hospital and Research Centre, India.

And also we duly acknowledge with thanks the cooperation rendered by the Dean and H.O.D. of Anatomy Department of Shri Sathya Sai Medical College and Research Institute, Dean of Mahatma Gandhi Medical College and Research Institute, and Vice Chancellor of Sri Balaji Vidyapeeth University, Pondicherry, India.

REFERENCES

- [1] Ajmani ML. The cutaneous branch of the human suprascapular nerve. *J Anat.* 1994;185:439-42.
- [2] Standing S Ellis H, Healy J, Johnson D, Williams A. Pectoral girdle, shoulder region and axilla. Gray's Anatomy - The Anatomical Basis of Clinical Practice. 39th ed. New York: Elsevier Churchill Livingstone; 2005; 821-2.
- [3] Bigliani, Dalsey RM, McCann PD, April EW. An anatomical study of the suprascapular nerve. *Arthroscopy.* 1990;6:301-5.
- [4] Shishido H, Kikuchi S. Injury to the suprascapular nerve during shoulder joint surgery: an anatomical study. *J Shoulder Elbow Surg.* 2001;10:372-6.
- [5] Callahan JD, Scully TB, Shapiro SA, Worth RM. Suprascapular nerve entrapment: a series of 27 cases. *J Neurosurg.* 1991;74:893-6.
- [6] Rengachary SS, Burr D, Lucas S, Hassanein KM, Mohn MP, Matzke H. Suprascapular entrapment neuropathy: a clinical, anatomical, and comparative study. Part 1: Clinical study. *Neurosurgery.* 1979;5(4):441-6.
- [7] Rengachary SS, Burr D, Lucas S, Hassanein KM, Mohn MP, Matzke H. Suprascapular entrapment neuropathy: a clinical, anatomical, and comparative. Study Part 2: anatomical study. *Neurosurgery.* 1979;5(4):447-51.
- [8] Rengachary SS, Burr D, Lucas S, Brackett CE. Suprascapular entrapment neuropathy: A clinical, anatomical, and comparative study. Part 3. *Neurosurgery.* 1979;5(4):452-5.
- [9] Barwood SA, Burkhart SS, Lo IK. Arthroscopic suprascapular nerve release at the suprascapular notch in a cadaveric model: an anatomic approach. *Arthroscopy.* 2007;23:221-5.
- [10] Harmon D, Hearty C. Diameter of suprascapular nerve in the suprascapular notch. *Pain Phys.* 2008;11:263-4.
- [11] Lafosse L, Tomasi A, Corbett S, Baier G, Willems K, Gobeze R. Arthroscopic release of suprascapular nerve entrapment at the suprascapular notch: technique and preliminary results. *Arthroscopy.* 2007;23:34-42.
- [12] More KL, Dalley AF, Agur AM. Clinical oriented anatomy. 6th Ed ed. Philadelphia: Lippincott Williams and Wilkins; 2010.
- [13] M.Polguy, K.S. J drzejewski, M. Podgórski, M. Topo. Correlation between morphometry of the suprascapular notch and anthropometric measurements of the scapula. *Folia Morphol.* 2011;70(2):109-15.
- [14] Kopell HP, Thompson WAL. Pain and the frozen shoulder. *Surg Gynecol Obstet.* 1959;109:92-6.
- [15] Antoniou J, Tae SK, Williams GR, Bird S, Ramsey MJ, Iannotti JP. Suprascapular neuropathy. Variability in the diagnosis, treatment, and outcome. *Clin Orthop Rel Res.* 2001;386:131-8.
- [16] Cummins CA, Messer TM, Nuber GW. Suprascapular nerve entrapment. *J Bone Joint Surg.* 2000;82-A:415-24.
- [17] Edeland HG, Zachrisson BE. Fracture of the scapular notch associated with lesion of the suprascapular nerve. *Acta Orthop Scand.* 1975;46(758):763.
- [18] Ferretti A, Cerullo, G, Russo G. Suprascapular neuropathy in volleyball players. *The Journal of Bone Joint Surg AM.* 1987;69:260-3.
- [19] Vastamaki M GH. Suprascapular nerve entrapment. *Clin Orth Rel Res.* 1993;297(135):143.
- [20] Bhatia DN, de Beer JF, van Rooyen KS, du Toit DF. Arthroscopic suprascapular nerve decompression at the suprascapular notch. *Arthroscopy.* 2006;22(1009):1013.
- [21] Hrdicka A. The scapula: visual observations. *Am J Phys Anthropol.* 1942;-29(73):94.
- [22] Zehetgruber H, Noske H, Lang T, Wurnig C. Suprascapular nerve entrapment: a meta-analysis. *Int Orthop.* 2002;26:339-43.
- [23] Ofusori D, Ude R, Okwuonu Ch, Adesanya O. Complete absence of the suprascapular notch in a Nigerian scapula: a possible cause of suprascapular nerve entrapment. *Int J Shoul Surg.* 2008;2(85):86.
- [24] Yücesoy C, Akkaya T, Özel O, Cömert A, Tüccar E, Bedirli N, et al. Ultrasonographic evaluation and morphometric measurements of the suprascapular notch. *Surg Rad Anat.* 2009;31(409):414.
- [25] Jadhav SD, Patil RJ, Roy PP, Ambali MP, Doshi MA. Supra scapular foramen in Indian dry scapulae. *NJCA.* 2012;1(3):133-5.
- [26] R.Shane Tubbs, Carl Nechtman, Anthony V. D'Antoni, Mohammadali M. Shoja, Martin M. Mortazavi, Marios Loukas, Curtis J. Rozzelle, Robert J. Spinner. Ossification of the suprascapular ligament: A risk factor for suprascapular nerve compression? *Int J Shoulder Surg.* 2013;7(1):19-22.
- [27] Paolo Albino, Stefano Carbone, Vittorio Candela, Valerio Arceri, Anna Rita Vestri, Stefano Gumina. Morphometry of the suprascapular notch: correlation with scapular dimensions and clinical relevance. *BMC Musculoskelet Disord.* 2013;14:172.

- [28] G Soni VS Malik, L Shukla, S Chhabra, N Gaur. Morphometric Analysis of the Suprascapular Notch. *The Internet Journal of Biological Anthropology*. 2012;5(1):DOI:10.5580/2B19.
- [29] Khan MA. Complete ossification of the suprascapular transverse ligament in an male adult. *Int J Morphol*. 2006;24(2):195-6.
- [30] Srijit Das, Rajesh Suri, Vijay Kapur. Ossification of Superior Transverse Scapular Ligament and its Clinical Implications. *Sultan Qaboos Univ Med J*. 2007 August;7(2):157-60.
- [31] Iqbal K, Iqbal R, Khan, SG. Anatomical variations in shape of suprascapular notch of scapula. *J Morphol Sci*. 2010;27(1):1-2.
- [32] Muralidhar Reddy Sangam. A Study on the Morphology of the Suprascapular Notch and Its Distance from the Glenoid Cavity. *J Clin Diagn Res*. 2013;7(2):189-92.
- [33] Vyas KK, Rajput HB, Zanzrukiya KM, Suttarwala I, Sarvaiya BJ, Shroff BD. An osseous study of suprascapular notch and various dimentions of safe zone to prevent suprascapular nerve injury. *Indian Journal of Applied Basic Medical Sciences*. 2013;15(20):27.
- [34] Kalpana Thounaojam Renuca Karam, N. Saratchandra Singh. Ossification of transverse scapular ligament. / Volume 2/ Issue 12/ March 25, 2013: 1790-1791. *Journal of Evolution of Medical and Dental Sciences*. 2013;2(12):1790-1.
- [35] Pragna Patel, S V Patel, S M Patel, Badal Jotania, Sanjay Chavda, Dhara Patel. Study of variations in the shape of the suprascapular notch in Dried Human Scapula. *Int J Biol Med Res*. 2013;4(2):3162-4.
- [36] Vandana R, Sudha Patil. Morphometric study of Suprascapular Notch. *National Journal of Clinical Anatomy*. 2013;2(3):140-44.
- [37] Kajava Y. Über den Schultergiirtel der Finen. *Ann Acad Sci Fenn, Series A* 1924;21(5):1-69.
- [38] Olivier G. Pratique anthropologique. Le scapulum. Paris: Vigot Freres; 1960.
- [39] Vallois H.V. L'os acromial dans les races humaine. *L' Anthropologie* 1925;35:977-1022.
- [40] Vallois HV. Variations de la cavite glenoide de l' omoplate. *Soc Biol Comptes Rendus Hebdomadaires Seances et memoires*. 1926;94(559):560.
- [41] Ticker JB, Djurasovic M, Strauch RJ, April EW, Pollock RG, Flatow EL, et al. The incidence of ganglion cysts and other variations in anatomy along the course of the suprascapular nerve. *J Shoulder Elbow Surg*. 1998;7(5):472-8.
- [42] Edelson JG. Bony bridges and other variations of the suprascapular notch. *J Bone Joint Surg Br*. 1995;77:505-6.
- [43] Natsis K, Totlis T, Tsikaras P, Appell HJ, Skandalakis K. Proposal for classification of the suprascapular notch: a study on 423 dried scapulas. *Clin Anat*. 2007;20:135-9.
- [44] Sinkeet SR, Awori KO, Odula PO, Ogeng'o JA, Mwachaka PM. The Suprascapular notch: its Morphology and distance from the glenoid cavity in a Kenyan population. *Folia Morphol*. 2010;69:241-5.
- [45] Urgüden M, Ozdemir H, Dönmez B, Bilbasar H, Oguz N. Is there any effect of suprascapular notch type in iatrogenic suprascapular nerve lesions? An anatomical study. *Knee Surg Sports Traumatol Arthrosc*. 2004;12(241):245.
- [46] Bayramoglu A, Demiryürek D, Tüccar E. Variations in anatomy at the suprascapular notch possibly causing suprascapular nerve entrapment: An anatomical study. *Knee Surg Sports Traumatol Arthrosc*. 2003;11:393-8.
- [47] Wang HJ, Chen C, Wu LP, Pan CQ, Zhang WJ, Li YK. Variable morphology of the suprascapular notch: an investigation and quantitative measurements in Chinese population. *Clin Anat*. 2011;24(1):47-55.
- [48] DJ Gray. Variations in human scapulae. *American Journal of Physical Anthropology*. 2013;29(1):57-72.1942.
- [49] Silva JG, Abidu-Figueiredo M, Fernandes RMP, Aureliano-Rafael F, Sgrott EA, Silva SF, et al. High incidence of ossification of superior transverse scapular ligament in Brazilians and its clinical significance. *Int J Morphol*. 2007;25(4):855-9.
- [50] Poirier P, A Charpy. *Traité d'anatomie humaine*. 3rd ed. Paris: 1911.
- [51] Osuagwu FC, Imosemi IO, Shokunbi MT Complete ossification of the superior transverse scapular ligament in a Nigerian male adult. *Int J Morphol*. 2005;23(2):121-2.

PARTICULARS OF CONTRIBUTORS:

1. Assistant Professor, Department of Anatomy, Mahatma Gandhi Medical College and Research Institute, Pillaiyarkuppam, Pondicherry, India.
2. Associate Professor, Department of General Surgery, Mahatma Gandhi Medical College and Research Institute, Pillaiyarkuppam, Pondicherry, India.
3. Professor, Department of Anatomy, Mahatma Gandhi Medical College and Research Institute, Pillaiyarkuppam, Pondicherry, India.
4. Professor and HOD, Department of Anatomy, Mahatma Gandhi Medical College and Research Institute, Pillaiyarkuppam, Pondicherry, India.

NAME, ADDRESS, E-MAIL ID OF THE CORRESPONDING AUTHOR:

Dr. Usha Kannan,
Assistant Professor, Department of Anatomy, Mahatma Gandhi Medical College and Research Institute, Pillaiyarkuppam,
Pondicherry-607402, India.
Phone: 9843320521, E-mail: drushakannan@yahoo.com

FINANCIAL OR OTHER COMPETING INTERESTS: None.

Date of Submission: **Oct 14, 2013**
Date of Peer Review: **Nov 09, 2013**
Date of Acceptance: **Dec 19, 2013**
Date of Publishing: **Mar 15, 2014**