

# Single Therapeutic Catheterization for Treatment of Late Diagnosed Native Coarctation of Aorta Using A Covered Stent

ALPER V URAL<sup>1</sup>, ILKER MURAT CAGLAR<sup>2</sup>, FATMA NIHAN TURHAN CAGLAR<sup>3</sup>, SERKAN CIFTCI<sup>4</sup>, OSMAN KARAKAYA<sup>5</sup>

## ABSTRACT

Here in we are reporting a 35-year-old pregnant, hypertensive woman with a strict descending aorta coarctation. She had two missing pregnancies which were complicated with hypertension, but which were not diagnosed for any pathologies before. We diagnosed coarctation of aorta, but however postponed her treatment after delivery of baby, because hypertension was under control with medical treatment and she had no complication. She had an uneventful delivery. MRI angiography revealed coarctation of aorta and it was successfully treated by using an endovascular covered stent during a single cardiac catheterization. Endovascular covered stent implantation is an easy, safe and effective method for treating coarctation of aorta in adults.

**Keywords:** Coarctation of aorta, Hypertension, Pregnancy

## CASE REPORT

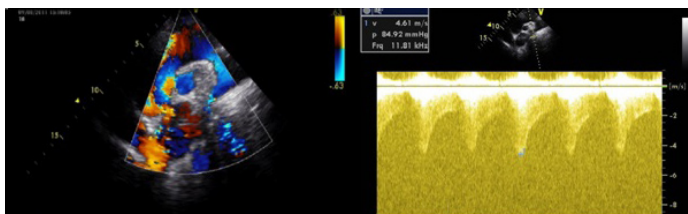
A 35-year-old, white, 6-months pregnant woman presented to our department for hypertension. She had hypertension since 17 years. She had leg pain on excursion since 5 years. She had given birth 4 times without complications and had 2 miscarriages. Her physical examination revealed weak femoral pulses and a brachiofemoral delay. Blood pressures of right and left arm and leg were 190/110 mmHg, 140/ 90 mmHg, and 80/50 mmHg, respectively. A grade 3/6 systolic murmur was heard over the precordial and interscapular areas. The electrocardiogram was normal. Standard and Doppler echocardiographic findings revealed a coarctation of descending aorta with a maximum 84 mmHg gradient across the coarctation, which was distal to the left subclavian artery [Table/Fig-1].

MRI angiography was planned, but as the patient was pregnant and did not have serious complications nor heart failure symptoms, it was postponed to after her delivery. The patient had an uneventful pregnancy and she gave birth successfully by caesarean section without any haemodynamic complications, and the newborn was

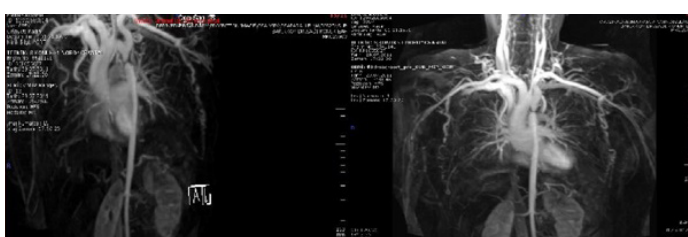
healthy. After baby's birth, the patient's blood pressure remained high. MRI angiography which was performed after birth; showed a strict coarctation of aorta (CoA) in the proximal part of the descending aorta [Table/Fig-2]. The length of the coarctation of aorta was 14 mm, isthmus was 19 mm, smallest diameter of aortic coarctation was 6 mm, and post-coarctation aortic diameter was 28 mm.

Cardiac catheterization was performed under local anaesthesia and left femoral artery and vein were cannulated. The coarctation segment could not be crossed with a 0.035 diagnostic guide wire. Therefore, a 0.014 hydrophilic guide wire was used for crossing the coarctation segment. Diagnostic multiple pores and a pigtail catheter were passed across the coarctation, over the hydrophilic guide wire. Measurements of aorta and coarctation segment were similar, as seen on MRI angiography. The maximal gradient across the coarctation was 64 mmHg. Distal part of the coarctation was minimally dilated (28 mm) [Table/Fig-3]. Pigtail catheter was changed to a 14F, 85 cm long Mullins sheath over the 0.035 exchange guide wire. A custom made, eight-zig, 4.5 mm long CP covered stent (NuMed, Hopkinton, NY) which was loaded on a balloon in balloon (BIB) (inner balloon 12 mm × 4.5 cm, outer balloon 24 mm × 5.5 cm) was used. After attachment, the excess covering material was folded around the stent. The graft stent and balloon assembly was passed through the sheath, after checking for correct positioning. Firstly, the inner balloon was inflated and its position was rechecked by angiography and then the outer balloon was fully inflated [Table/Fig-4].

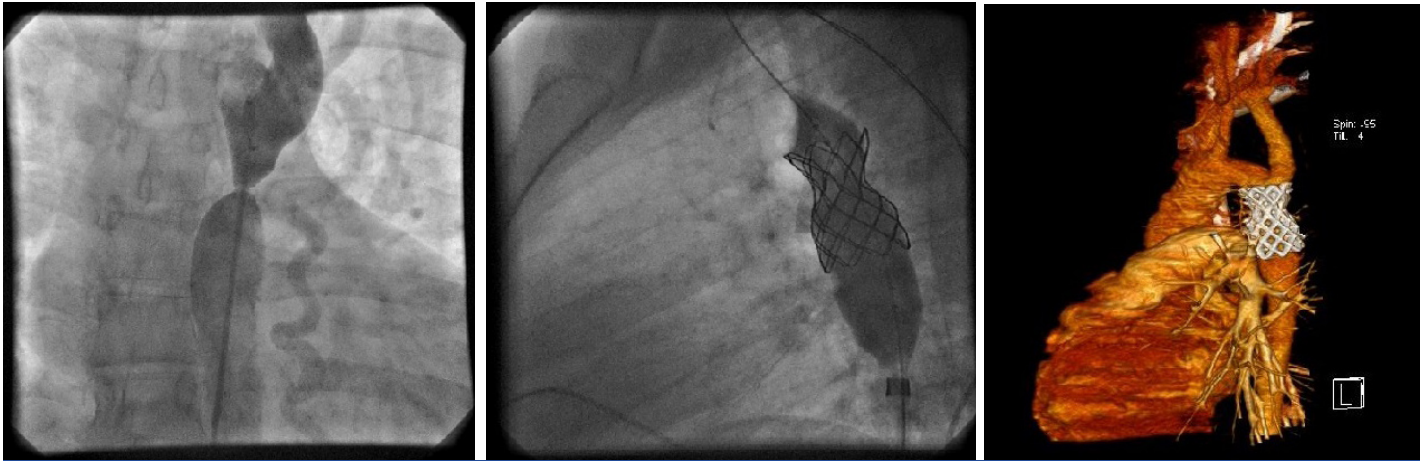
Both balloons were then deflated, with the inner one being deflated first before being withdrawn through the sheath. Control aortography revealed a stent-graft in position, which covered the coarcted segment. Maximum gradient across the coarctation was 11 mmHg. The coarcted segment's diameter was increased from 6 mm to 17 mm. The procedure was completed without complications. After the procedure, patient was monitored for 24 hours for possible complications and blood pressure control. Intravenous, unfractionated heparin infusion was started at a rate of 800 IU/h. Blood pressure remained high and therefore, anti-hypertensive medication was needed. Calcium channel blocker



**[Table/Fig-1]:** Coarctation of aorta and doppler study in transthoracic echocardiography



**[Table/Fig-2]:** Coarctation of aorta in proximal descending aorta in MRI angiography



**[Table/Fig-3]:** Coarctation of aorta in conventional angiography

**[Table/Fig-4]:** Coarctation of aorta covered and dilated with stent-graft

**[Table/Fig-5]:** Contrast tomography after the 1 year follow-up of the patient

therapy was started and the patient was discharged with 100 mg acetyl salicylate and 75 mg clopidogrel. After 1 year's follow-up, the clinical examination showed preserved lower-limb pulses. The patient was symptom free and normotensive on taking 5mg amlodipine daily. The contrast computerized tomography revealed that the stent was in normal position, without any narrowing [Table/Fig-5]. In the second year of follow up; the patient was examined clinically with echocardiography. The patient was symptom free, normotensive without any drugs and the echocardiographic examination showed no significant gradient (maximum 11 mmHg across the stented area).

## DISCUSSION

Coarctation of aorta is a common congenital heart defect which is divided into two types, based on the presence of other intracardiac abnormalities: Simple coarctation; the most common form which is detected in adults also, the type that our patient had; is the coarctation which is not associated with other cardiac abnormalities and complex coarctation is the coarctation which is associated with other cardiac abnormalities [1].

Coarctation of aorta in pregnancy affects the outcomes in both mother and child. Maternal and neonatal mortalities are reported to be 0-9% and 8-19% respectively in different series [2].

Increased risk of aortic dissection during pregnancy, which is caused by hormonal alterations, haemodynamic changes in the aortic wall and hypertension, is the most important and fatal complication of aortic coarctation [2]. There are several cases of aortic dissections which occurred in pregnant women with coarctation of aorta, which have been reported in the literature [2]. Although coarctation of aorta is not a common cause of hypertension during pregnancy, almost 60% of pregnant women with significant coarctation experience hypertension and it is related to the haemodynamic significance of the coarctation gradient [1,2]. Hypertension may lead to adverse neonatal and maternal outcomes like growth retardation, abruptio placentae, premature deliveries, renal failure and hypertensive crisis [2]. Although a vaginal delivery is suggested for women with congenital heart disease, there is an increased rate of caesarean deliveries in pregnant women with coarctation [2]. This may be due to the fact that it may be safer for the mother, especially if she has significant hypertension, dilated aorta that is at risk of dissection and/or significant coarctation [2]. Our Gynaecology and Obstetrics Department also decided to do caesarean section deliveries due to increased cardiovascular risk which could be caused to the mothers. Coarctation of aorta should be treated in all, but not the mildest forms whenever it is diagnosed [3]. However, there is not any consensus on how to treat aortic coarctation. There are different treatment strategies for coarctation in adults, including surgery,

percutaneous balloon angioplasty with or without stent implantation, and medical therapy for hypertension. Although surgical repair of coarctation which was first performed by Blalock and Park in 1944 is the most selected treatment strategy worldwide, endovascular treatment of coarctation of aorta has evolved since 1980s [3,4]. Various types of stents have been used successfully. Recently, however, it was found that aneurysm formation was still an issue of concern and therefore, covered stents have been introduced [5,6]. Although there is no data on the long-term outcomes following covered stent implantations of aortic coarctations, this method is rapidly becoming popular and case series seem promising [6]. Freund et al., recently reported a case which was similar to ours [7]. They successfully implanted a covered stent in a 37-year-old woman by using simultaneous radial and femoral approaches [7].

Our case is special, because the patient's significant coarctation was undiagnosed for many years, even after 2 miscarriages. We decided to wait until her delivery and then performed a transcatheter stent implantation; which is a more easier, effective and comfortable method for treating coarctation of aorta than surgery. Zeira and Zohar reported 2 pregnant women with coarctations who were also medically followed-up until their deliveries [8]. However, Assaidi et al., reported a case in which they had implanted a stent for coarctation of aorta during pregnancy, without complications [9]. Rest of the pregnancy of their patient was uneventful [9]. They pointed out a need for randomized trials for confirming the safety of stenting during pregnancy [9]. Our patient's blood pressure remained high after stenting and she even needed antihypertensives. However, Jurjut et al., reported immediate blood pressure normalization after stenting in a woman who was 45-year-old [4].

Optimal antiplatelet treatment after stenting remains unknown, due to lack of related studies. However, giving double antiplatelet therapy for at least 3 months is recommended [4].

## CONCLUSION

Covered stent implantation is safe and effective for treatment of coarctation of aorta in adults. Future randomized trials are needed to make a statement.

## REFERENCES

- [1] Batur MK, Koç M, Ozer I, Abalı G. Usefulness of endovascular stent-graft for combination with a strict aort coarctation and patent ductus arteriosus for an adult patient: a case report. *Cases Journal*. 2009;2:8477.
- [2] Beauchesne LB, Connolly HM, Ammash NM, Warnes CA. Coarctation of the Aorta: Outcome of Pregnancy. *JACC*. 2001;1728-33.
- [3] Mahadevan V, Mullen MJ. Endovascular management of aortic coarctation. *International Journal of Cardiology*. 2004;97;75-8.
- [4] Jurcut R, Daraban AM, Lorber A, Deleanu D, Amzulescu MS, Zara C, et al. Coarctation of the aorta in adults: what is the best treatment? Case report and literature review. *Journal of Medicine and Life*. 2011;4(2):189-95.

- [5] Kulkarni S, Vimala J, Parmar R. Single Therapeutic Catheterization for Treatment of Native Coarctation of Aorta and Large Patent Ductus Arteriosus Using a Covered Stent a safe strategy while dealing with an adolescent or an adult with this combination of lesions. *Indian Heart J.* 2005; 57: 713–6.
- [6] Sadiq M, Malick NH, Qureshi SA. Simultaneous Treatment of Native Coarctation of the Aorta Combined With Patent Ductus Arteriosus Using a Covered Stent. *Catheterization and Cardiovascular Interventions.* 2003: 59:387–90.
- [7] Freund MV, Vollebregt AM, Krings G, Vonken EPA, Agostoni P, Meijboom FJ. Native atretic coarctation of the aorta in a 37-year-old hypertensive woman, treated with a low-profile covered stent. *Neth Heart J.* 2013;21:206-7.
- [8] Zeira M, Zohar S. Pregnancy and delivery in women with coarctation of aorta. *Harefuah.* 1993;15:124:756-8.
- [9] Assaidi A, Sbragia P, Fraisse A. Transcatheter therapy for aortic coarctation with severe systemic hypertension during pregnancy. *Catheter Cardiovasc Interv.* 2013;1;82(4):556-9.

**PARTICULARS OF CONTRIBUTORS:**

1. Faculty, Department of Cardiology, Bakirkoy Education and Research Hospital, Istanbul, Turkey.
2. Faculty, Department of Cardiology, Bakirkoy Education and Research Hospital, Istanbul, Turkey.
3. Faculty, Department of Cardiology, Istanbul Education and Research Hospital, Istanbul, Turkey.
4. Faculty, Department of Cardiology, Bakirkoy Education and Research Hospital, Istanbul, Turkey.
5. Faculty, Department of Cardiology, Bakirkoy Education and Research Hospital, Istanbul, Turkey.

**NAME, ADDRESS, E-MAIL ID OF THE CORRESPONDING AUTHOR:**

Dr. Ilker Murat Caglar,  
Faculty, Department of Cardiology, Bakirkoy Education and Research Hospital, Istanbul, Turkey.  
Email: ilkermuratcaglar@gmail.com

Date of Submission: **Aug 30, 2013**  
Date of Peer Review: **Dec 17, 2013**  
Date of Acceptance: **Jan 22, 2014**  
Date of Publishing: **Mar 15, 2014**

**FINANCIAL OR OTHER COMPETING INTERESTS:** None.