

Adenoid Cystic Carcinoma of the Buccal Mucosa: A Case Report with Review of Literature

VIDYALAKSHMI S.¹, ARAVINDHAN R.²

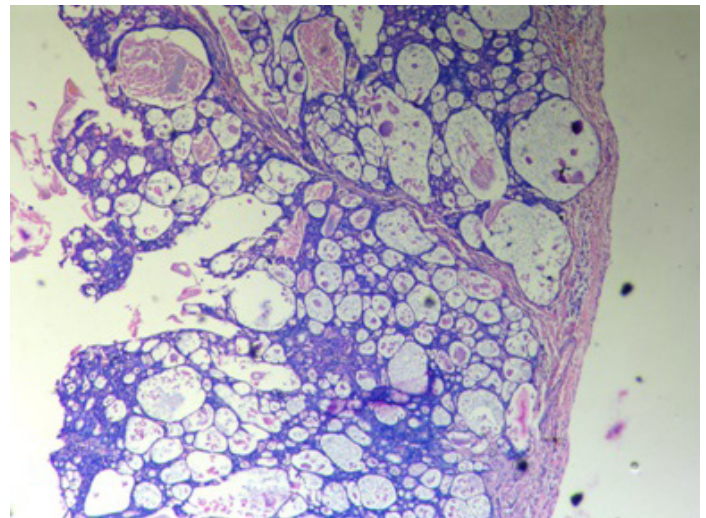
ABSTRACT

Minor salivary gland neoplasms of the buccal mucosa are relatively uncommon. Adenoid cystic carcinoma (ACC), a well-defined entity, occurs most of the times in the parotid, submandibular glands and palate, as far as the intraoral site is concerned. Adenoid cystic carcinoma tends to have an indolent, extended clinical course with wide local infiltration and late distant metastases. We are presenting a case of an adenoid cystic carcinoma of the buccal mucosa in a 48-year-old female patient.

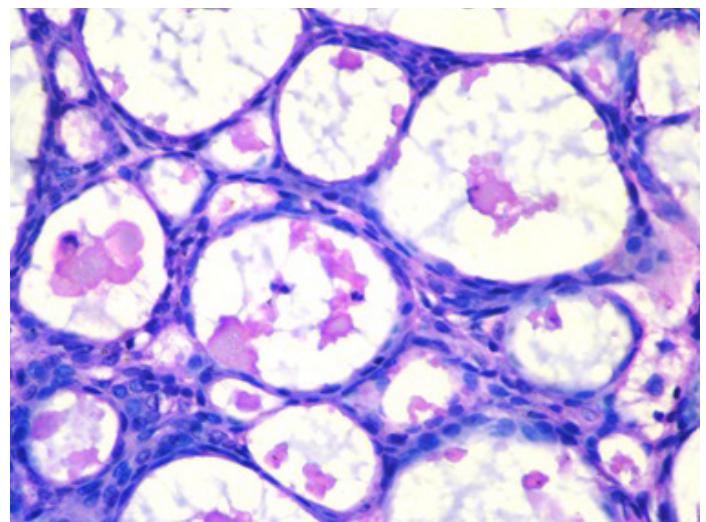
CASE REPORT

A 48-year-old female patient presented with complaint of a swelling in the left cheek, in relation to left upper back tooth region. The swelling was present since 1 year and it had arisen as a small one, after extraction of a decayed left upper back tooth. History revealed that the swelling had increased gradually to attain its present size and that it was not associated with pain. There was no relevant medical, surgical or personal history. On extra oral examination, there was no evidence of erythema, ulceration or ecchymosis. Single left submandibular lymph node that was mobile, firm, non-tender and of size 0.5x0.5 cm, was palpable. Intra oral examination revealed a single localized dome shaped swelling of size 2x3 cm in the left buccal mucosa, in relation to 27 region, which extended posteriorly till the faucial pillars of the tonsils [Table/Fig-1]. The mucosa which overlay the swelling was erythematous in nature and its surface was smooth. There was no surface discharge, the swelling was firm in consistency and it was nontender. The swelling was fixed to the underlying tissue and the area which surrounded the swelling, appeared to be normal. Clinical differential diagnosis included benign mesenchymal neoplasms, reactive or inflammatory conditions of minor salivary glands, benign or low grade malignant tumours of salivary gland origin, and metastatic tumour deposits of distant site. An orthopantomograph was taken and it revealed no bony changes in the maxilla or the mandible. Lesion was excised in toto, it was

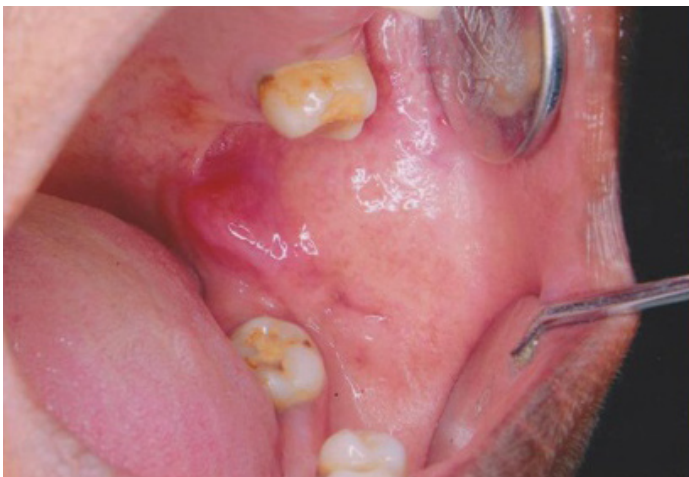Keywords: Salivary gland tumour, Perineural invasion, Cylindroma



[Table/Fig-2]: Photomicrograph demonstrating a neoplasm of glandular epithelial origin within the lamina propria with a focal cribriform pattern (H&E × 100)



[Table/Fig-3]: Photomicrograph illustrating cuboidal cells with hyperchromatic nuclei and visible accumulation of an eosinophilic hyalinized material within pseudocystic spaces (H&E × 400)



[Table/Fig-1]: Clinical picture depicting a mass of the buccal mucosa

preserved in 10% formalin and it was sent for a histopathological examination. The microscopic examination revealed numerous duct like structures that were lined by hyperchromatic, basophilic, isomorphic and cuboidal epithelium in a mature stroma [Table/Fig-2,3]. Histopathological differential diagnosis included polymorphous low grade adenocarcinoma, epithelial and myoepithelial carcinoma, basaloid squamous cell carcinoma and salivary duct carcinoma. The final diagnosis of Adenoid Cystic Carcinoma (ACC) with a cribriform pattern was established. The patient was referred to an oncologist for further management. She was followed up for 6 months, with no signs of recurrence.

DISCUSSION

Malignant neoplasms of the salivary glands in the head and neck are relatively rare, accounting for only less than 7% of all neoplasms, among which about 10% were adenoid cystic carcinomas [1]. Stell PM were the first to describe the cylindrical appearance of this tumour [2]. Theodor Billroth, in 1856, described ACC as "cylindroma" because of its long amorphous compartments which look like cylinders. Interestingly, Spies was the first to use the term, "adenoid cystic carcinoma" in 1930. In 1943, Mehta and Parikh emphasized the malignant nature of this tumour [3].

ACCs are mostly reported in the minor salivary glands, and less frequently in the major salivary glands. Furthermore, ACC is the second most common type of carcinoma which arises in the salivary glands, after mucoepidermoid carcinoma. It occurs in females most often and between 5th to 7th decades of life. The most characteristic clinical feature of this malignancy includes its slow growth rate, delayed onset of distant metastasis, increased local recurrences, and peri-neural invasion [4].

Most ACCs are submucosal and they appear as smooth, domed swellings without overlying ulcerations [4]. Very rarely, ACCs may arise intra-osseously, commonly in the posterior mandible of an adult [5]. Bone invasion or a perineural spread can sometimes cause pain or hypoesthesia.

Salivary gland malignancies shares similar imaging features, and these cannot be differentiated from each another by imaging alone. Imaging is mainly used to detect malignant features, demonstrate local and distant involvements, define nodal status and guide FNAC, if needed [6].

The incidence of regional lymph node metastasis is relatively rare [3]. Distant metastases occur in 25-50% of the individuals, particularly to the lungs and bone. Also, they are more common and unpredictable [7].

The role of fine-needle aspiration cytology (FNAC) in the diagnosis of salivary gland neoplasms requires paying attention to the smear pattern, cell type, chromatin, and nuclear features, such as grooves or pseudoinclusions [8]. FNAC of ACCs usually reveals closely packed, round to ovoid basaloid cells with hyperchromatic nuclei, which are arranged in branching patterns. Also evident in the aspirate, are globules of mucus.

Adenoid cystic carcinomas usually present as well-defined masses of the involved glands. On gross examination, the tumour mass is seen as either partially encapsulated or unencapsulated. Frequently, but not always, it invades the adjacent stroma. As is seen in other salivary gland tumours, it exhibits a varied microscopic pattern. ACCs are thought to arise from the pluripotent stem cells in the intercalated ducts, that can differentiate into epithelial and myoepithelial cells. They are composed of both ductal (luminal) and myoepithelial (abluminal) cells with varied compositions [4].

The World Health Organization (WHO), defined this as 'an infiltrative malignant tumour which had a very characteristic cribriform appearance [9].

Microscopically, the tumour cells are "isomorphic" in nature and they are arranged in various morphological patterns. Most commonly,

ACCs present in three patterns, cribriform, tubular and solid, that may occur separately or in combinations in the same tumour.

The most classic and the best recognized is the cribriform (glandular) appearance which is characterized by islands of basaloid epithelial cells (small and cuboidal, which exhibit deeply basophilic nuclei and little cytoplasm), that contain multiple, cylindrical, cyst-like spaces which resemble Swiss cheese, that often contain some kind of secretory material in it. Mitotic activity is rarely seen.

Tubular variant displays bilayered duct like structures with an inner layer of cuboidal to columnar ductal cells, with moderate amounts of eosinophilic cytoplasm and outer, smaller, darker staining cells. The solid variant, being the most aggressive one, is composed of uniform sized groups or sheets of small, darkly stained basal/myoepithelial tumour cells [5,10].

Grading of the tumour

Grading of ACC is thought to have prognostic significance and it is categorized as Grade I, which consists only of cribriform and tubular histomorphologies, Grade II has cribriform, tubular and solid growth patterns, with solid growth pattern being seen in only less than 30% of the tumour and Grade III where the tumours predominantly display solid features (>30% or more of the tumour) [10].

Immunohistochemically, ACCs can be divided into two groups

Ductal cells (luminal) show positivity for carcinoembryonic antigen (CEA), epithelial membrane antigen (EMA), cytokeratin (CK) of low and high molecular weights, S-100 and alpha1-ACT. Myoepithelial cells (abluminal) show positivity for smooth muscle actin (SMA), CK of low molecular weight, vimentin, p63. Expressions of S100 and glial fibrillary acidic protein (GFAP) in ACCs may possibly indicate that Schwann cell differentiation in modified myoepithelial cells correlates with perineural invasion in this salivary gland malignancy. ACCs also show positivity to beta-catenin, E-cadherin, C-kit, high expressions of p53 and bcl-2, and low Ki-67 [5,10].

Unlike squamous cell carcinomas of the head and neck, ACCs frequently get metastasized to distant sites and they are known for their distinctive biological and clinical behaviours. The mechanisms which underlie these remain poorly understood. Few molecular studies have been performed to unravel this. Recently, a recurrent t (6; 9) (q22-23; p23-24) translocation was found in ACCs, that ultimately results in the fusion of MYB and NFIB gene. This fusion leads to the deregulation of the expression of MYB, and it is likely to be a critical step in oncogenesis for ACC [11].

Treatment and prognosis

In a nutshell, Conley described ACC as one of the biologically unpredictable and aggressive tumours, which is difficult to treat.

The conventional method of treating ACC includes extensive local resection of the tumour with its associated lymph nodes. In a majority of cases, surgical resections are usually combined with postoperative radiation therapy, in order to eradicate the residual tumour cells. Radiotherapy has proved to provide a better locoregional control when it was given post-operatively. However, radiotherapy alone is not sufficient for treating this tumour per se. Post-operative radiation consists of daily treatments, 5 times per week, for a period of 6 weeks or so.

Neutron, proton or carbon ion radiations in different dosings and schedules may be more appropriate than the conventional photon radiations given for some unresectable or deep tumours. Neutron beam therapy was proven to be more efficient when it was compared with photon therapy, for avoiding local recurrence. Stereotactic body radiation therapy (SBRT), such as Cyber knife, Novalis, TomoTherapy etc., uses one or a few high doses of radiation for destroying tumour cells. Up to 100 Gys of radiation might be administered over the course in each "fraction".

Chemotherapeutic regimens for ACC are usually opted for in advanced disease statuses, as a single agent or in combinations. Commonly used single-agents are 5-Fluorouracil (5-FU), Gemcitabine, Doxorubicin, Vincristine, Cisplatin, Mitoxanthrone, Epirubicin, Paclitaxel. Combination Chemotherapy is rarely preferred, because of its increased toxicity, as compared to single agent treatments [12].

Molecular targeted therapy is a promising tool in cancer treatment. It uses certain drugs that target some specific pathways which play an important role in the proliferation, angiogenesis, metastasis, and/or apoptosis of cancer cells. Drugs such as imatinib (against c-kit or CD 117), lapatinib, gefitinib (against EGFR), cetuximab, and bortezomib have been used in treating ACCs. The roles of immunotherapy, gene therapy and other systemic therapy, such as hormonal treatment for ACC, are still undergoing clinical trials [13].

The nature of the primary tumour, location, histomorphology, and its tendency to metastasize to distant sites, positive margins at the surgical site, determine the survival rate [14].

CONCLUSION

Adenoid cystic carcinomas tend to have an indolent extended clinical course, with local infiltrations and late distant metastases. The true behaviour, whatever the type of lesion it may be, may be defined clearly upon grossing and microscopic examination of the resected tissue. Hence, pathologists should encourage surgeons and clinicians to plan the treatment based on the final diagnosis, to obtain a better prognosis.

REFERENCES

- [1] Mano T, Wada N, Uchida K, Muraki Y, Nagatsuka H, Ueyama Y. Central adenoid cystic carcinoma of the mandible with multiple bone metastases: case report. *J Oral Maxillofac Surg*. 2010; 68(2): 446-51.
- [2] Stell PM. Adenoid cystic carcinoma. *Clin Otolaryngol*. 1986; 11(4): 267-91.
- [3] Mehta DN, Parikh SJ. Adenoid cystic carcinoma of palate. *J Nat Sci Biol Med*. 2013; 4(1): 249-52.
- [4] Ellis GL, Auclair PL, Gnepp DR. Adenoid cystic carcinoma, Surgical Pathology of Salivary glands, Philadelphia, WB Saunders, 1991; 333-46.
- [5] Shamim T, Varghese VI, Shameena PM, Sudha S. Primary intraosseous adenoid cystic carcinoma of the mandible with lung metastases: a case report. *Journal of Oral Science*. 2008; 50(1):95-8.
- [6] Lee YYP, Wong KT, King AD, Ahuja AT. Imaging of salivary gland tumors. *European Journal of Radiology*. 2008; 66: 419-36.
- [7] Locati LD, Guzzo M, Bossi P, Massone PP, Conti B, Fumagalli E, et al. Lung metastasectomy in Adenoid cystic carcinoma of salivary gland. *Oral Oncol*. 2005; 41: 890-4.
- [8] Idowu MO, Reiter ER, Powers CN. Adenoid Cystic Carcinoma A Pitfall in Aspiration Cytology of the Thyroid. *Am J Clin Pathol*. 2004; 121: 551-6.
- [9] Thackray AC, Sobin LH. Histological typing of salivary gland tumors. International Histological Classification of Tumours, No.7. Geneva, *World Health Organisation*. 1972; 1-28.
- [10] Irving Dardick. Color Atlas / Text of Salivary Gland Tumor Pathology, 1st edition, Lippincott Williams and Wilkins, 1996.
- [11] West RB, Kong C, Clarke N, Gilks T, Lipsick JS, Cao H, et al. MYB expression and translocation in adenoid cystic carcinomas and other salivary gland tumors with clinicopathologic correlation. *Am J Surg Pathol*. 2011;35:92-9.
- [12] Papaspyrou G, Hoch S, Rinaldo A, Hominem A, Eundem A, Takes RP, Herpen CV, Werner JA, Ferlito A. Chemotherapy and targeted therapy in adenoid cystic carcinoma of the head and neck: A review. *Head Neck*. 2011; 33: 905-11.
- [13] Dodd RL, Slevin N. Salivary gland adenoid cystic carcinoma: A review of chemotherapy and molecular therapies. *Oral Oncology*. 2006; 42: 759- 69.
- [14] Huang MX, Ma DQ, Sun KH, Yu GY, Guo CB, Gao F. Factors influencing survival rate in adenoid cystic carcinoma of the salivary glands. *Int. J. Oral Maxillofac Surg*. 1997; 26: 435-9.

PARTICULARS OF CONTRIBUTORS:

1. Senior Lecturer, Department of Oral and Maxillofacial Pathology, Indira Gandhi Institute of Dental Sciences, Pillaiyarkuppam, Pondicherry, India.
2. Senior Lecturer, Department of Oral and Maxillofacial Pathology, SRM Kattankulathur Dental College & Hospital, Srm University, Potheri, Kanchipuram, India.

NAME, ADDRESS, E-MAIL ID OF THE CORRESPONDING AUTHOR:

Dr. Aravindhan R.,
Senior Lecturer, Department of Oral and Maxillofacial Pathology,
SRM Kattankulathur Dental College & Hospital, SRM University, Potheri, Kanchipuram, India.
Phone: +91-9442543907, Email: araviopath86@gmail.com

Date of Submission: **Aug 28, 2013**
Date of Peer Review: **Dec 26, 2013**
Date of Acceptance: **Jan 17, 2014**
Date of Publishing: **Mar 15, 2014**

FINANCIAL OR OTHER COMPETING INTERESTS: None.