

Morphometry of Suprascapular Notch and its Correlation with that of Scapula

MURALIDHAR REDDY SANGAM¹, SATTIRAJU SRI SARADA DEVI²

ABSTRACT

Suprascapular notch is the common site for the entrapment of the suprascapular nerve. Suprascapular nerve compression usually presents with vague pain across the scapula or dull shoulder ache. It is more common in over head athletes like volleyball players. Hence the study of morphology and morphometry of the notch is important clinically.

INTRODUCTION

Morphological variations of the suprascapular notch are important clinically. The size of the notch may play a role in the predisposition for the entrapment [1, 2]. Smaller the size of the notch, greater the chance of nerve entrapment. Abduction of the shoulder joint beyond 90° may exert traction on the suprascapular nerve, which leads to its compression against transverse scapular ligament. Narrow suprascapular notches have been reported in patients with the nerve entrapment. Suprascapular nerve compression may present with vague pain radiating across the scapula, dull shoulder ache, limitations of shoulder joint movements and wasting of supraspinatus and infraspinatus [2]. Incidence of suprascapular neuropathy is 7–10%. Most of the reported incidence is in overhead athletes like volleyball players accounting 12–33% of athletic population [3]. This work is in continuation of author's earlier work on scapulae [4].

MATERIALS AND METHODS

The present study was carried out in 104 dried human scapulae of unknown sex obtained from the Department of Anatomy, NRI Medical College and other near by Medical Colleges in Andhra Pradesh, India. Broken scapulae were excluded from the study. For studying the morphometry of suprascapular notches, the scapulae with discrete notches and scapulae with completely ossified superior transverse scapular ligament were not included, as it is not possible to record superior transverse diameter and maximum depth for comparative purposes. The suprascapular notch of each scapula was measured for the following details.

Superior transverse diameter (STD): The maximum horizontal distance between the superior corners of the notch [4].

Maximum depth (MD): The maximum vertical distance between the deepest point of the notch to the imaginary plane between the superior corners of the notch [4].

Each scapula was measured for the following details.

Morphological length (ML): Maximum length of the scapula [Table/Fig-1].

Morphological width (MW): Maximum width of the scapula [Table/Fig-1].

Measurements were taken using sliding vernier calipers (sensitivity 0.1mm) and recorded in millimeters. Data was analyzed statistically. Mean and standard deviations were calculated for ML, MW, STD and MD. The results were plotted on scattered diagram to understand the direction and strength of relation between the variables. Student t-test was done to test the significance of correlation coefficient.

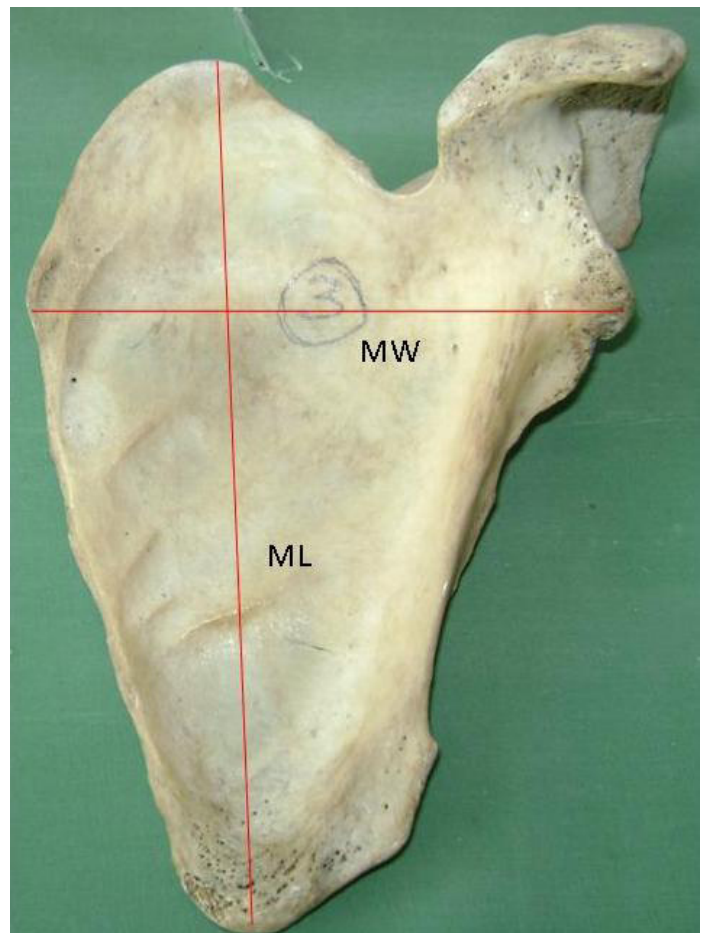
Keywords: Suprascapular notch, Scapula, Entrapment

RESULTS

[Table/Fig-2] shows the dimensions of suprascapular notch and of scapulae.

There is a low positive correlation between STD of suprascapular notch and MW of the scapula (correlation value is 0.390 and t-value is 36.34). The correlation value is highly statistically significant with p-value <0.001 [Table/Fig-3].

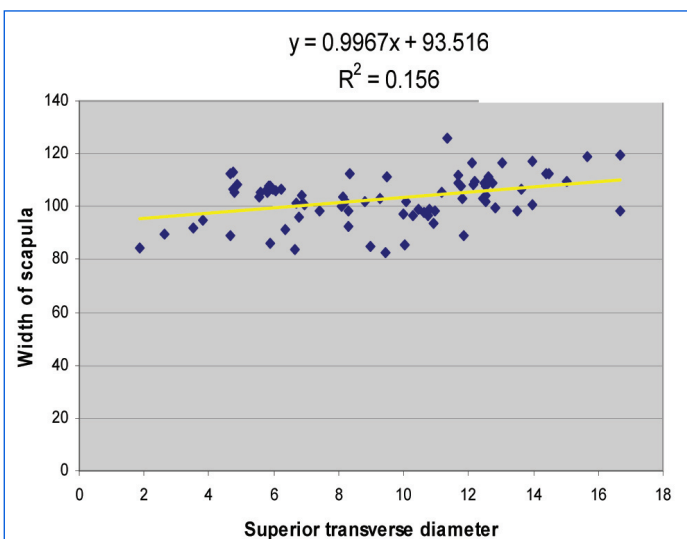
There is a low positive correlation between MD of suprascapular notch and ML of scapula (correlation value is 0.359901 and t value is 32.66301). The correlation value is highly statistically significant with p-value <0.001 [Table/Fig-4].



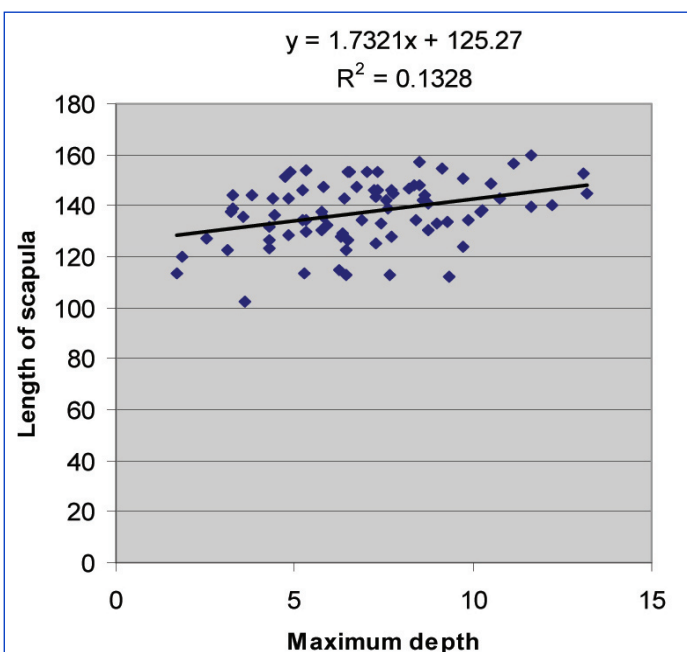
[Table/Fig-1]: Morphological length (ML) and Morphological width (MW) of scapula.

Dimension	STD > MD	MD > STD	STD = MD
Mean STD	10.65±3.18	6.77±2.06	5.81±3.6
Mean MD	6.52±2.52	9.28±2.36	5.81±3.6
Mean ML of scapula	135.92±2.74	141.88±9.82	140.27±12.5
Mean MW of scapula	103.29±9.19	102.56±7.37	101.44±11
Mean Scapular index	76.25±6.91	72.63±7.58	72.3±4.29

[Table/Fig-2]: Shows the dimensions of suprascapular notch and scapulae.



[Table/Fig-3]: Correlation between superior transverse diameter of the notch and width of the scapula.



[Table/Fig-4]: Correlation between maximum depth of the notch and length of the scapula.

DISCUSSION

In the present study, a low positive correlation is observed between MD of the notch and ML of the scapula, and between STD of the notch and MW of the scapula. It could be assumed that in long scapula, maximum depth of the notch may be more and in when the width of the scapula is more, the width of the notch may be more. A similar study was carried out by Polguy et al., [5] who reported that there is a positive correlation ($R = 0.265179$) between morphological length of the scapula and MD of the notch, but they described there was no correlation between morphological width of the scapula and the STD of the notch.

As there is a positive correlation between maximum depth of the suprascapular notch and morphological length of scapula, it may be described that long scapulae may have deeper suprascapular notches. Similarly as there is a positive correlation between superior transverse diameter of the notch and morphological width of the scapula, it may be described that wider scapulae may have wide suprascapular notch.

CONCLUSION

Study of morphometry of suprascapular notch is useful as the notch is the common site for nerve compression. We observed a low positive correlation between ML of scapula and MD of the notch, and between MW of the scapula and STD of the notch. This information may useful in estimating the dimensions of the notch by studying the morphological length and width of the scapula.

ACKNOWLEDGEMENTS

We thank Mrs. Kolli Naga Saritha, Lecturer in Statistics, NRI Medical College, Chinakakani, for helping in the data analysis. We sincerely thank the Department of Anatomy, Siddhartha Medical College, Vijayawada and the Department of Anatomy, Pinnamaneni Siddhartha Institute of Medical Sciences, Gannavaram for giving permission to carryout the study in their colleges.

REFERENCES

- [1] Rengachary SS, Burr D, Lucas S, Hassanein KM, Mohn MP, Matzke H. Suprascapular entrapment neuropathy: a clinical, anatomical, and comparative study. Part 1: Clinical study. *Neurosurgery*. 1979;5:441-446.
- [2] Rengachary SS, Burr D, Lucas S, Hassanein KM, Mohn MP, Matzke H. Suprascapular entrapment neuropathy: a clinical, anatomical, and comparative study. Part 2: Anatomical study. *Neurosurgery*. 1979;5:447-451.
- [3] Witvrouw E, Cools A, Lysens R, Cambier D, Vanderstraeten G, Victor J, Sneyers C, Walravens M. Suprascapular neuropathy in volleyball players. *Br J Sports Med*. 2000; 34 (3):174-80.
- [4] Muralidhar Reddy S, Sarada Devi SS, Krupadanam k, Anasuya k. A study on the morphology of the Suprascapular notch and its distance from the glenoid cavity. *J Clin Diagn Res*. 2013;7(2):189-92.
- [5] Polguy M, Jedrzejewski KS, Podgorski M, Topol M. Correlation between morphometry of the suprascapular notch and anthropometric measurements of the scapula. *Folia Morphol*. 2011;70(2):109-115.

PARTICULARS OF CONTRIBUTORS:

1. Associate Professor, Department of Anatomy, NRI Medical College, Chinakakani, Guntur, Andhra Pradesh, India.
2. Professor, Department of Anatomy, NRI Medical College, Chinakakani, Guntur, Andhra Pradesh, India.

NAME, ADDRESS, E-MAIL ID OF THE CORRESPONDING AUTHOR:

Dr. Muralidhar Reddy Sangam,
Associate Professor, Department of Anatomy, NRI Medical College, Chinakakani, Guntur – 522503, Andhra Pradesh, India.
Phone: 9440668501, E-mail: murali_sangam@yahoo.co.in

FINANCIAL OR OTHER COMPETING INTERESTS: None.

Date of Submission: Sep 09, 2013

Date of Peer Review: Nov 08, 2013

Date of Acceptance: Nov 25, 2013

Date of Publishing: Apr 15, 2014