

# An Unusually Long Survival of A Patient with Glioblastoma of Spinal Cord: A Case Report

SUNITHA SUSAN VARGHESE<sup>1</sup>, PATRICIA SEBASTIAN<sup>2</sup>, VIVEK JOSEPH<sup>3</sup>, GEETA CHACKO<sup>4</sup>, SELVAMANI BACKIANATHAN<sup>5</sup>

## ABSTRACT

Primary glioblastoma of spinal cord are rare and are associated with poor survival especially in adults. We report a case of glioblastoma of thoracic spinal cord (D3 to D6) in an adult treated with partial resection surgery and radiation therapy with a survival of six years with good quality of life. The patient had paraplegia at presentation but improved after surgery and radiation therapy to grade 4 in both lower limbs. After 5 years, he developed new lesion in a different location of the spine (L1, L2 & L5) along with multiple lesions over entire spine and was treated with radiation therapy and a year later developed a new lesion intracranially in the posterior fossa involving cerebellopontine angle region infiltrating brainstem. He was treated with palliative radiotherapy and is on chemotherapy with Temozolomide and is still alive with ability to do activities of daily living at the time of this report. Radiation therapy provided prolonged local control with effective palliation of symptoms and good quality of life in this patient enabling to do activities of daily living.

**Keywords:** Glioblastoma, Survival, Spinal cord

## CASE REPORT

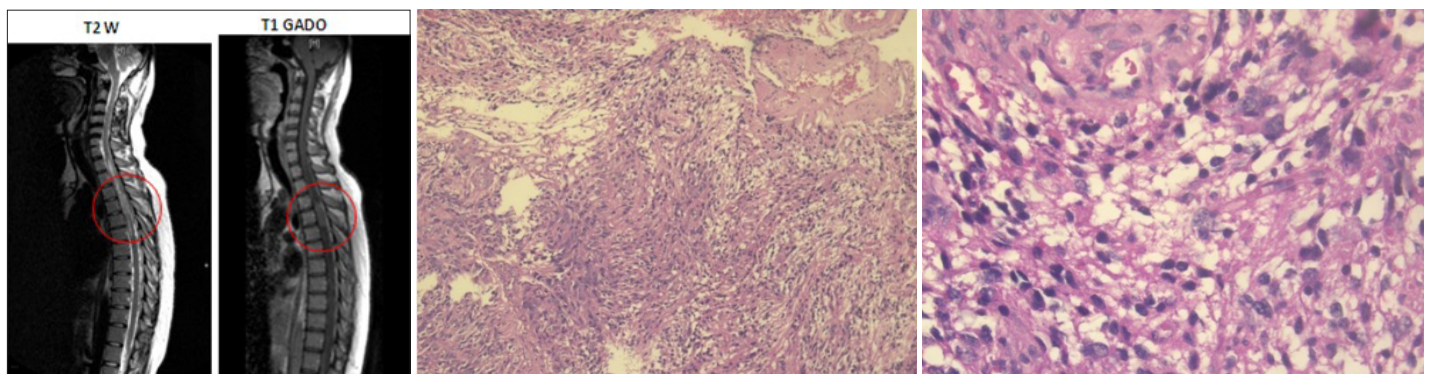
A 22-year-old gentleman presented in December 2006 with a short one-month history of progressive weakness of bilateral lower limbs, decreased sensation below the mid-chest level, urinary hesitancy with a sense of incomplete evacuation of the bladder. On examination, the tone was spastic in both lower limbs with power of grade 0 and absence of all modalities of sensation below T4 level bilaterally. MRI spine showed a diffuse contrast enhancing intramedullary mass from D3 to D6 level [Table/Fig-1]. Multiple small nodular lesions were seen extending along the spinal cord inferior to the lesion down to the conus. He underwent T3 – T6 laminectomy and partial excision of the mass in December 2006. The histopathology revealed a hypercellular tumour composed of compact fascicles of neoplastic glial cells that were mitotically active [Table/Fig-2]. There was evidence of microvascular proliferation [Table/Fig-3]. Necrosis, pseudorosettes and Rosenthal fibres were not present. On immunohistochemistry, the tumour cells were positive for glial fibrillary acidic protein (GFAP) [Table/Fig-4] and negative for epithelial membrane antigen (EMA) [Table/Fig-5a and 5b]. The MIB-1 labelling index was 10% [Table/Fig-6]. Despite the absence of necrosis, a diagnosis of Glioblastoma was considered owing to the presence of microvascular proliferation.

Postoperatively, he was treated with conventional radiation therapy, 5040 cGy in 28 fractions, five fractions per week. Physiotherapy

and occupational therapy were continued and he had neurological improvement with grade 4 power in right lower limb, left thigh and knee, and grade 2 powers in left ankle dorsiflexion. Sensation recovered completely. He was able to void normally at this time. [Table/Fig-7] shows the imaging at the follow up visit in May 2008.

In April 2012, he presented with increased low backache and tightness of left lower limb of one month duration with reduction in power in the left lower limb to grade 2. There was decreased sensation along the L3 to L5 dermatomes. MRI spine showed recurrent contrast enhancing lesions in multiple levels, largest lesion at L1/L2 levels and L5 levels [Table/Fig-8]. He received radiotherapy to the lumbar lesion - 50 Gy in 25 fractions by three dimensional conformal techniques. The power in left lower limb improved to grade 4, and he was able to carry out activities of daily living without support.

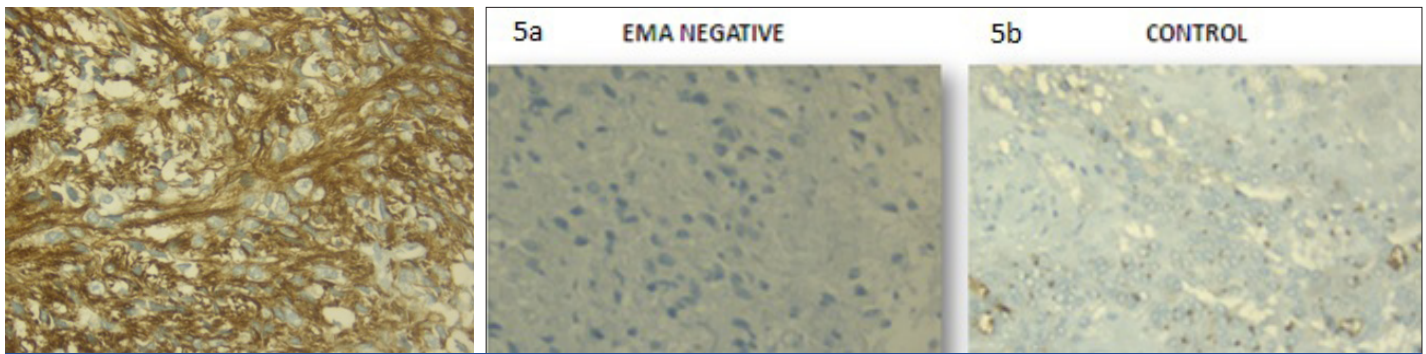
In July 2013, he developed giddiness and vomiting with postural imbalance of one month duration and was found to have a left cerebellopontine (CP) angle tumour with infiltration of the cerebellum, midbrain and pons [Table/Fig-9]. He received palliative radiotherapy to whole brain, 36 Gy in 12 fractions using conventional technique. He was also started on chemotherapy with Temozolomide (TMZ). He is alive continuing chemotherapy currently at the point of reporting this case with good quality of life and abilities to do activities of daily living but with residual minimal incoordination.



**[Table/Fig-1]:** T2 and Contrast T1 Sagittal MRI images showing an intramedullary contrast enhancing lesion from D3 – D6 level

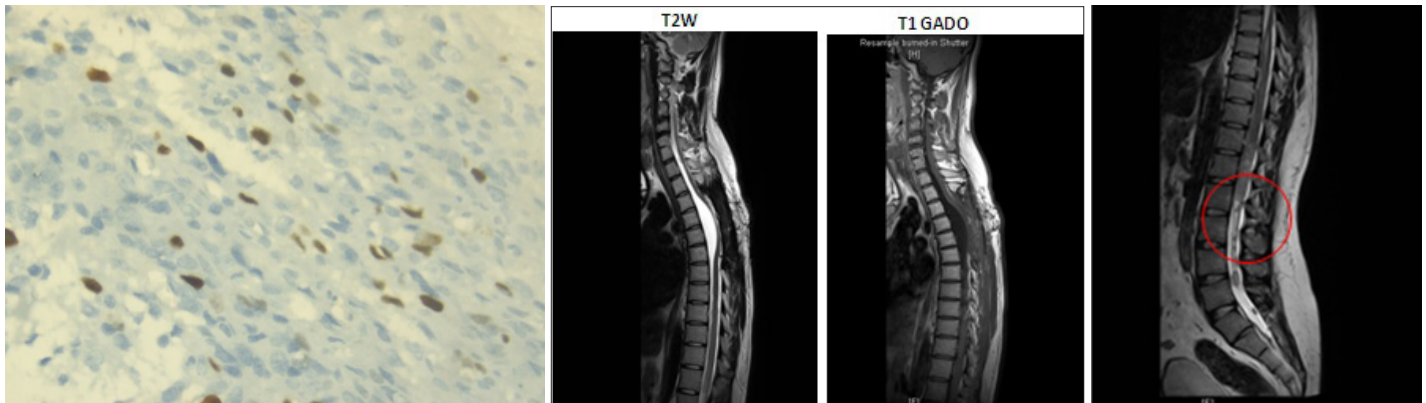
**[Table/Fig-2]:** Photomicrograph of tumour illustrating the arrangement of cells in compact fascicles. (Haematoxylin & Eosin x 90)

**[Table/Fig-3]:** Photomicrograph of tumour illustrating the cells with nuclear atypia, mitotic activity and vascular proliferation (Haematoxylin & Eosin x 400)



**[Table/Fig-4]:** Immuno-positivity for glial fibrillary acidic protein, GFAP (Streptavidin biotin peroxidase x 400)

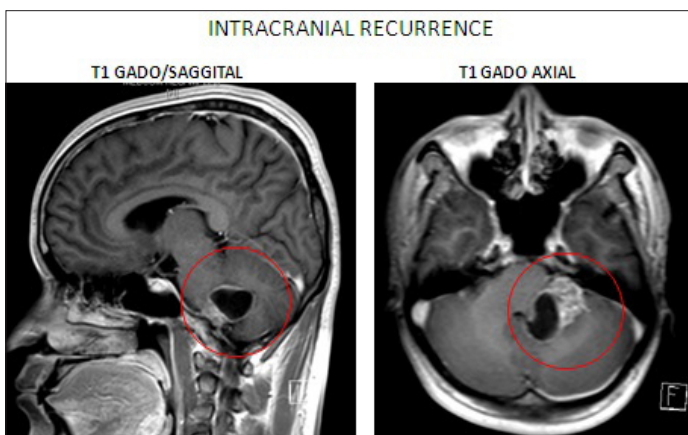
**[Table/Fig-5a and b]:** Anaplastic Ependymoma was excluded as immunostaining for Epithelial Membrane Antigen (EMA) was negative, as illustrated in Fig 5a. This is in contrast to the control depicted in Fig 5b of a known ependymoma with cytoplasmic dot-like immunoreactivity for EMA. (Streptavidin biotin peroxidase x 400)



**[Table/Fig-6]:** MIB 1 labelling index of 10% in the tumour (Streptavidin biotin peroxidase x400)

**[Table/Fig-7]:** Sagittal T2W and T1 Gadolinium enhanced MRI showing no residual disease at one year follow up, post RT

**[Table/Fig-8]:** T2W sagittal MR imaging showing recurrence in the L1 – L2 level in April 2012



**[Table/Fig-9]:** Gadolinium enhanced T1 Sagittal and axial Imaging showing tumour in the left cerebellar peduncle which is reaching the CP angle

## DISCUSSION

Primary spinal cord gliomas constitute 4 to 10% of all primary CNS tumours. Majority of them are low grade gliomas. Ependymomas are the most common intramedullary tumours followed by Astrocytomas [1]. Ependymomas are often surgically resectable. Astrocytomas are infiltrative in nature and complete resection is difficult. The clinical presentation of primary spinal cord tumours is determined by the location of the tumour. Common symptoms include pain, motor disturbance and sensory loss with or without bowel and bladder involvement. MRI of the spine with contrast is the imaging modality of choice.

The 5 year survival of low grade spinal cord gliomas is about 70% [1]. High grade spinal cord gliomas are less common and associated with a poor survival. The estimated median survival for primary spinal cord glioblastoma is 6–10 months [2]. Adams et

al., [2] reported that age at diagnosis less than 18 years, males, anaplastic astrocytoma, and a gross total resection of the tumour were associated with better survival. Rodrigues et al., [3] reported that patients with duration of symptoms more than 6 months prior to diagnosis had better survival. This goes with the fact that patients with prolonged duration of symptoms usually have a low grade tumour. Tumour grade, extent of resection, and functional status at the time of presentation are the most important prognostic factors identified by Chamberlain et al., [4]. Our patient had grade 0 power in bilateral lower limbs at presentation, his age was more than 18 years, and length of symptoms was less than 6 months - all these are poor prognostic features. However, he has done well for 6 years with a good quality of life without affecting his activities of daily living.

Adjuvant radiotherapy is indicated for patients with high grade histology, incomplete resection and those with progressive disease and has shown to improve survival [5,6]. Treatment of high grade glioma of spinal cord consists of maximal safe resection followed by external beam radiotherapy [1]. Low grade spinal cord astrocytomas may be treated upto a total tumour dose of 5040 cGy in 180 cGy per fraction. High grade gliomas require radiocordectomy dose of 5400 cGy in 180 cGy/fraction. Abdal-Wahab et al., [7] reported a median radiation dose of 50 Gy by conventional fractionation for malignant spinal cord gliomas. Involved fields (one vertebral body above and below the tumour mass) are used because survival is short and local failure is the dominant pattern of recurrence [8-10]. Our patient was given post-operative involved field radiation therapy up to 5040 cGy in 28 fractions in April 2007, and 5040 cGy in 28 fractions for the recurrence in lumbar region in April 2012 and palliative RT of 36 Gy in 12 fractions to whole brain in July 2013.

Chemotherapy is reserved for progression of disease following surgery and as an adjuvant in high grade gliomas though its role is still unclear. In a retrospective review of 8 patients with HGG of spinal cord treated with various TMZ schedules by Kaley et al., [8],



the median time to progression was 6.6 months and the median overall survival (OS) from the initiation of Temozolomide was 16.6 months. Other chemotherapeutic agents that have been used include Lomustine, Carboplatin, Vincristine or PCV (Procarbazine, CCNU, Vincristine). None of these chemotherapy agents appear to be highly effective, but may occasionally benefit an individual patient. Adjuvant alkylator based chemotherapy is used in spinal cord high grade gliomas based on data in treating intracranial high grade gliomas [4].

The utility of Bevacizumab for recurrent spinal cord glioblastomas was also reported by Kaley et al., in a small retrospective study [8]. Five of 6 patients had partial response on imaging. The median progression free survival (PFS) was 20.7 months and median overall survival (OS) was 22.8 months. Bevacizumab is thought to have a better effect on spinal cord gliomas due to its ability to decrease peritumoural oedema and mass effect. Chamberlain et al., [1] reported a median PFS of seven months and median OS of 9 months with Bevacizumab in recurrent high grade spinal cord gliomas. Bevacizumab was well tolerated in that cohort. Our patient was given chemotherapy with Temozolomide (Stupp regimen) at the time of intracranial recurrence. He did not receive Bevacizumab.

## CONCLUSION

Glioblastoma of the spinal cord with a survival of more than six years is unusual. Radiation therapy is effective in neurological recovery and

in providing good quality of life and ability to carry out activities of daily living without support in a poor prognostic illness such as this.

## REFERENCES

- [1] Chamberlain MC, Johnston SK. Recurrent spinal cord glioblastoma: salvage therapy with bevacizumab. *J Neurooncol*. 2011;102(3):427–32.
- [2] Adams H, Avendaño J, Raza SM, Gokaslan ZL, Jallo GI, Quiñones-Hinojosa A. Prognostic factors and survival in primary malignant astrocytomas of the spinal cord: a population-based analysis from 1973 to 2007. *Spine*. 2012;37(12):E727–35.
- [3] Rodrigues GB, Waldron JN, Wong CS, Laperriere NJ. A retrospective analysis of 52 cases of spinal cord glioma managed with radiation therapy. *Int J Radiat Oncol Biol Phys*. 2000;48(3):837–42.
- [4] Chamberlain MC, Tredway TL. Adult primary intradural spinal cord tumors: a review. *Curr Neurol Neurosci Rep*. 2011;11(3):320–28.
- [5] Shirato H, Kamada T, Hida K, Koyanagi I, Iwasaki Y, Miyasaka K, et al. The role of radiotherapy in the management of spinal cord glioma. *Int J Radiat Oncol Biol Phys*. 1995;33(2):323–28.
- [6] Minehan KJ, Brown PD, Scheithauer BW, Krauss WE, Wright MP. Prognosis and treatment of spinal cord astrocytoma. *Int J Radiat Oncol Biol Phys*. 2009;73(3):727–33.
- [7] Abdel-Wahab M, Etuk B, Palermo J, Shirato H, Kresl J, Yapicier O, et al. Spinal cord gliomas: A multi-institutional retrospective analysis. *Int J Radiat Oncol Biol Phys*. 2006;64(4):1060–71.
- [8] Kaley TJ, Mondesire-Crump I, Gavrilovic IT. Temozolomide or bevacizumab for spinal cord high-grade gliomas. *J Neurooncol*. 2012 Sep;109(2):385–89.
- [9] Isaacson SR. Radiation therapy and the management of intramedullary spinal cord tumors. *J Neurooncol*. 2000;47(3):231–38.
- [10] Linstadt DE, Wara WM, Leibel SA, Gutin PH, Wilson CB, Sheline GE. Postoperative radiotherapy of primary spinal cord tumors. *Int J Radiat Oncol Biol Phys*. 1989;16(6):1397–403.

### PARTICULARS OF CONTRIBUTORS:

1. Assistant Professor, Department of Radiation Oncology, Christian Medical College, Vellore, Tamil Nadu, India.
2. Assistant Professor, Department of Radiation Oncology, Christian Medical College, Vellore, Tamil Nadu, India.
3. Professor, Neurosurgery, Department of Neurological Sciences, Christian Medical College, Vellore, Tamil Nadu, India.
4. Professor, Neuropathology, Departments of Pathology and Neurological Sciences, Christian Medical College, Vellore, Tamil Nadu, India.
5. Professor, Department of Radiation Oncology, Christian Medical College, Vellore, India.

### NAME, ADDRESS, E-MAIL ID OF THE CORRESPONDING AUTHOR:

Dr. Patricia Sebastian,  
Assistant Professor, Department of Radiation Oncology, CMC, Vellore-632004, Tamil Nadu, India.  
Phone: +91-9443097564/+91-9367985410, E-mail: drpat@cmcvellore.ac.in

**FINANCIAL OR OTHER COMPETING INTERESTS:** None.

Date of Submission: **Jan 15, 2014**

Date of Peer Review: **Jan 30, 2014**

Date of Acceptance: **Feb 16, 2014**

Date of Publishing: **Apr 15, 2014**