

# Evaluation of Clinical Outcomes after Abdominal Rectopexy and Delorme's Procedure for Rectal Prolapse: A Prospective Study

HEMANTH MAKINENI<sup>1</sup>, POORNACHANDRA THEJESWI<sup>2</sup>, B.K. SHIVPRASAD RAI<sup>3</sup>

## ABSTRACT

**Background:** Complete rectal prolapse is characterized by protrusion of full thickness rectal wall through the anal orifice. Despite its rarity more than 100 surgical procedures have been described and there are no good evidence based recommendations for selection of a surgical procedure. This study was conducted to evaluate the clinical outcomes of commonly used procedures for rectal prolapse at our hospital.

**Materials and Methods:** Twenty seven patients presenting with complete rectal prolapse between May 2011 to May 2013 were included in this prospective study. Patients underwent either Abdominal rectopexy or Delorme's procedure after evaluation, based on clinical judgment of experienced surgeons. Patient characteristics, complications, post-operative length of hospitalization and clinical outcomes were assessed. Patients were followed up for a mean duration of 14 months.

**Results:** Seventeen patients underwent Abdominal rectopexy (Posterior mesh rectopexy), ten patients underwent Delorme's procedure. No postoperative mortalities or major complications

were noted. Post operative morbidity (minor) was 17% in Abdominal rectopexy group and 10% in Delormes group 0%. Incontinence improved in all six patients (100%) in rectopexy group, four patients (80%) in Delorme's procedure group. Two patients (11%) in rectopexy group reported increase in constipation post operatively. There was one recurrence in Delorme's procedure group with no recurrences in Abdominal rectopexy group.

**Conclusion:** The treatment of rectal prolapse should be individualized to achieve best results. Abdominal rectopexy can be safely applied in most of patients with minimal post operative increase in constipation and recurrence by using posterior mesh rectopexy technique. Delorme's procedure can be performed with minimal morbidity and shorter hospital stay and good functional results with acceptable recurrence rate. Delorme's can be considered as an alternative to rectopexy not only in patients unfit for laparotomy but also in individuals with a short prolapse, avoiding a laparotomy.

**Keywords:** Rectal prolapse, Rectopexy, Delorme's procedure

## INTRODUCTION

Rectal prolapse (proctientia) is the protrusion of full thickness rectal wall through the anal canal. It is a relatively rare condition. Although rectal prolapse was described in Ebers Papyrus in 1500 BC, the etio-pathogenesis remains an enigma [1]. Proposed etiologies include pregnancy, perineal nerve injury, chronic constipation straining, neurologic and psychiatric disorders, and other conditions resulting in increased intra-abdominal pressure [2,3].

Many theories were proposed to explain the pathogenesis of this disease. The most accepted theories include the one proposed by Moschcowits [4] in which he suggested that the anterior rectal wall herniates through the defect in the pelvic fascia. This theory was challenged by Broden and Snellman [5], who demonstrated with the aid of cinedefecography, that rectal prolapse is a circumferential intussusception of the rectum through the anus. This theory is widely accepted as 50% normal individuals have intussusceptions as demonstrated by Shorvon et al., [6] by cinedefecography.

Over a 100 surgical procedures have been described in literature. These procedures can be categorised into abdominal and perineal procedures[7]. In general, perineal surgical repairs cause less morbidity and mortality, but are attributed to have greater recurrences when compared with abdominal operations. They are considered especially in the elderly and/or high-risk patients as they can also be done under regional anaesthesia. Abdominal procedures are preferred for all patients fit for abdominal surgeries and is the most commonly performed procedure [8]. This study was conducted to

evaluate the clinical outcomes following Abdominal rectopexy and Delorme's procedure for rectal prolapse at our hospital.

## METHODS

This prospective, observational study was conducted after approval by Institutional Ethics Committee. Study was conducted between May 2011 to May 2013. Patients presenting with mass per rectum were evaluated and diagnosed clinically as having rectal prolapse were included in study.

### Inclusion criteria

- Full-thickness rectal prolapse, externally visible on straining.
- Patient has given written informed consent.
- Aged 18 years or older.

### Exclusion criteria

- Recurrence of full-thickness rectal prolapse.
- Patient who underwent resection with rectopexy.
- Patient with stoma.
- Patient with inflammatory bowel disease.
- Patient currently under chemotherapy.

History was noted including detailed history of bowel habits. Incontinence was graded using Browning and Park's grading. Constipation was defined using Rome III criteria.

Base line blood investigations and sigmoidoscopy were performed. Patients underwent Abdominal rectopexy or Delorme's procedure after evaluation, based on clinical judgment of experienced surgeons. Patients with longer prolapse (more than 10 cm) fit for general anaesthesia underwent abdominal rectopexy. Patients with high risk to tolerate major surgery, patients with short prolapse (less than 10 cm) underwent Delorme's procedure. Female patients with associated utero-vaginal prolapse underwent a simultaneous vaginal hysterectomy with pelvic floor repair and Delorme's. All procedures were performed by senior surgeons experienced in colorectal surgery.

Bowel was prepared the day before surgery using a balanced polyethyleneglycol solution, and antimicrobial prophylaxis was given just before surgery.

### Surgical Technique

**Posterior mesh rectopexy:** The patient was placed in the Lloyd-Davies position, and a urinary catheter inserted. The rectum is mobilised to the pelvic floor posteriorly, preserving nerves and ureters. Lateral ligaments were preserved in all patients. A monofilament knitted polypropylene mesh was placed in presacral space and was anchored to the sacral promontory with three 2-0 prolene sutures at three points, after mobilization of rectum. The mesh encircled three-fourth the circumference of the rectum and was fixed to rectum with sero-muscular sutures with 2-0 prolene.

**Delorme's Procedure:** Patient was placed in lithotomy position and catheterised. Prolapse was exteriorised and held with grasping forceps, solution of adrenaline saline (1 in 200,000 or 300,000) injected submucosally just beyond the dentate line. Diathermy dissection was used to strip mucosa from the underlying muscularis propria. This process was continued circumferentially to the apex of the prolapse and then inside as far as possible. The muscle wall was imbricated with a series of radial absorbable sutures. The two cut ends of mucosa were sutured together with interrupted absorbable sutures.

Clinical outcomes in form of primary and secondary outcomes were assessed.

### Outcome Measures

Primary outcome measure was recurrence of full thickness rectal prolapse which is clinically the most relevant measure.

Recurrence was defined as the circular protrusion of rectal mucosa through the anal canal and was evaluated by history, clinical examination including examination of patients while performing a straining manoeuvre in a sitting position.

Secondary outcomes are morbidity, mortality, length of initial hospital stay, constipation, and faecal incontinence.

Morbidity occurring during the primary hospital stay was further differentiated into surgical and non-surgical complications.

### Surgical complications

- Post-operative ileus
- Post-operative haemorrhage
- Intra-abdominal abscess
- Surgical site infection
- Urinary disturbances
- Erectile dysfunction

### Non-surgical complications

- Deep vein thrombosis
- Pulmonary embolism
- Post-operative pulmonary infection
- Renal failure

Cerebral insult Ischemic or non-ischemic cerebrovascular event with persistent paresis or paralysis

Myocardial infarction

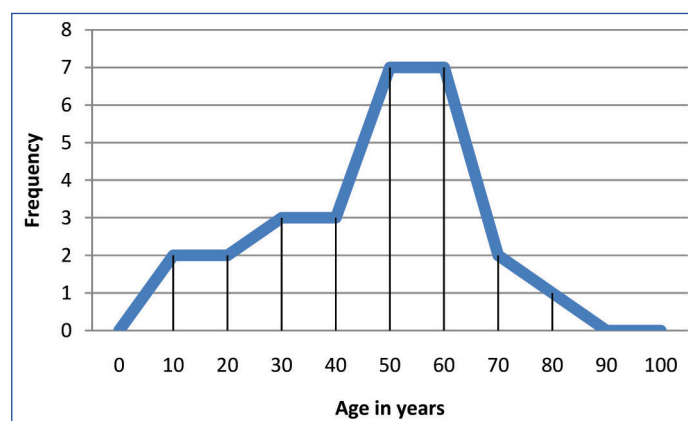
### Follow Up

Patients were followed up at 1,3,6,12,18,24 months and out comes were assessed. The mean duration of follow up was 14 months.

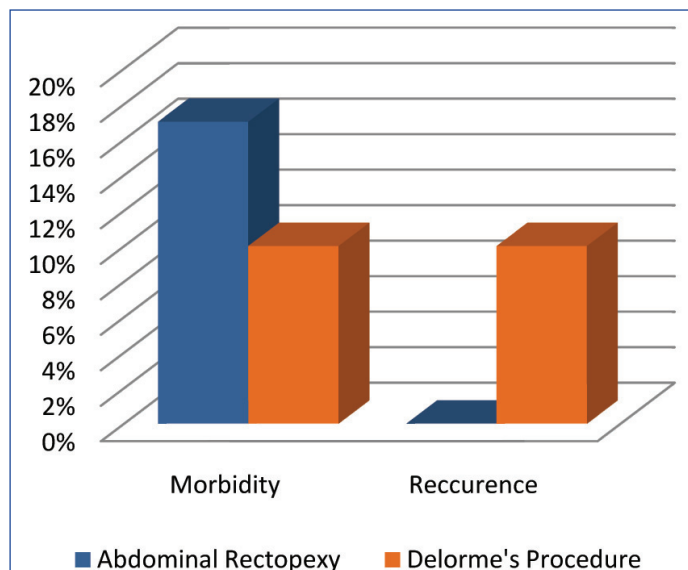
## RESULTS

Twenty seven patients were included in the study of which 15 were male and 12 were female. Male female ratio was 1.25. The average age of presentation for males is 46 years, less than for female for whom average age at presentation is 60 years [Table/Fig-1]. The symptoms at presentation include mass per rectum in 27(100%) patients, mucous discharge in 19 (70%), bleeding per rectum in 15 (56%), painful defecation in 12 (44%), incontinence in 9 (33%), constipation in 7 (26%) patients. 10 (37%) patients had solitary rectal ulcer at presentation.

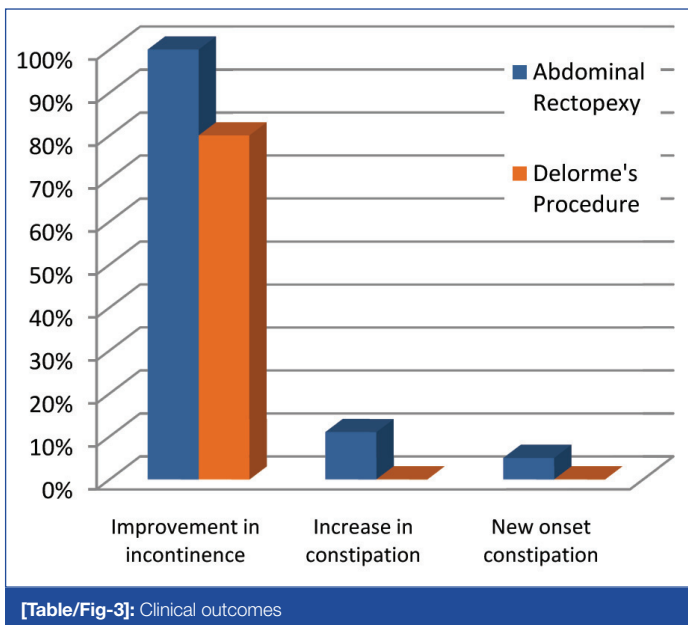
Seventeen patients underwent abdominal rectopexy, ten patients underwent Delorme's procedure. The average duration of hospital stay for rectopexy was 6.5 days and 4 days for Delorme's. There was no mortality in either group. Morbidity in abdominal rectopexy group was 17% (1 each of prolonged post-operative ileus, minor surgical site infection, faecal impaction) and in Delorme's was 10%(1 patient had minor surgical site bleeding) [Table/Fig-2]. Incontinence improved in all five patients(100%) in rectopexy group, three patients (80%) in Delorme's procedure group. Two patients (11%) in rectopexy group had increase in constipation post-operatively. One patient (5%) developed new onset constipation post-operatively in rectopexy



[Table/Fig-1]: Age Distribution



[Table/Fig-2]: Incidence of complications



[Table/Fig-3]. All patients with constipation could be managed with laxatives. There was 1 recurrence in Delorme's procedure group at 1-year of follow-up. Patient was a 67-year-old female presented with simultaneous utero-vaginal prolapse, underwent Delorme's procedure combined with vaginal hysterectomy and pelvic floor repair, and later underwent abdominal rectopexy. There were no recurrences in rectopexy group.

## DISCUSSION

Rectal prolapse is described as the disease of elderly females in western literature [9], but in our study there is slight predominance of male compared to females, with 60% (n=16) of patient below 60 years. This distribution is consistent with previous studies reported from India [10,11]. Posterior mesh rectopexy could be done with no recurrences and no mortality. Morbidity was 17% of which all were minor. Incontinence improved in all 5 patients who had pre-operative incontinence in the rectopexy group. The incidence of new onset constipation is 5% with only 11% of patients developing increase in constipation. These results may be due to the preservation of lateral ligaments preventing denervation of rectum [12] and technique of modified posterior mesh rectopexy in which the mesh encircles only a third of circumference which prevents obstructed defecation. There was no new onset constipation in Delorme's group and incontinence was cured in three out of four patients [13]. Incontinence persisted in an 86-year-old female who was suffering with rectal prolapse for 7 years likely due to pudendal nerve damage. There was one recurrence in Delorme's group.

General belief is that abdominal procedures have lower recurrence rates [14,15]. The recurrence rates abdominal procedures in various studies reported range between 0% to 12% [12]. The recurrence rates in Delorme's procedure are between 0% to 20% [8,12,16]. This wide variations in reported recurrence rates may be due to different duration of follow-up and patient selection.

The lesser recurrence rates of abdominal rectopexy comes with some complications like new onset constipation, the general hazards of laparatomies, risk of pelvic nerve damage, which may cause sexual dysfunction in men, and adhesion formation. In a study, retrograde ejaculation and impotence were seen in 17.2% of the patients after posterior rectopexy [17].

Delorme's operation is simple, fast and can be carried out under general or regional anaesthesia. The hospital stay is shorter as there is no need to wait for resolution of ileus. New onset constipation is rare as innervation to the rectum is not interfered [8]. Failed Delorme's operation does not compromise subsequent abdominal procedures as was with one of our patients. Rectal stenosis can be

a long term complication in patients whom extensive prolapse is repaired by Delorme's procedure.

Traditionally, recurrence rate was the most important factor in determining the procedure. It was believed that recurrence rate was high in patients undergoing Delorme's procedure. However recent trails have failed to demonstrate that one procedure is superior to the other when functional outcome, operational morbidities and overall costs have been considered [12,18].

Senapati et al., [18] conducted a study in which patients were randomized between abdominal and perineal surgeries. This study concluded that there were no significant differences in outcomes of various procedures. Further several prospective and retrospective studies suggest that Delorme's procedure which was earlier reserved for elderly patients can be used in young adults with satisfactory results [19,20]. Hence the role of Delorme's procedure in management of rectal prolapse should be reconsidered and it should be used in appropriate patients.

## CONCLUSION

Better outcomes can be achieved when treatment is individualized to each patient with rectal prolapse as demonstrated by our study. Posterior mesh rectopexy can be used in patients who can tolerate laparotomy with predominant symptom of incontinence. It improves incontinence with a minimal risk of increasing constipation.

Delorme's procedure should be considered as an alternative to abdominal rectopexy in young patients with shorter prolapse, as complications of abdominal rectopexy like erectile dysfunction and other morbidities of a laparotomy can be avoided with slightly higher risk of recurrence.

## LIMITATIONS

This is a small non randomized study. Further larger randomized studies with long duration of follow-up are required to get a conclusive evidence.

## REFERENCES

- [1] Ballantyne GH. The historical evolution of anatomic concepts of rectal prolapse. *Semin Colon Rectal Surg.* 1991;2:170-9.
- [2] Madoff RD, Mellgren A. One hundred years of rectal prolapse surgery. *Dis Colon Rectum.* 1999;42:441-50.
- [3] Marceau C, Parc Y, Debroux E, Tret E, Parc R. Complete rectal prolapse in young patients: psychiatric disease a risk factor of poor outcome. *Colorectal Dis.* 2005;7:360-5.
- [4] Moschowitz AV. The pathogenesis, anatomy and cure of prolapse of the rectum. *Surg Gynecol Obstet.* 1912;15:7-21.
- [5] Broden B, Snellman B. Proctodientia of the rectum studied with cine-radiography: a contribution to the discussion of causative mechanism. *Dis Colon Rectum.* 1968;11:330-47.
- [6] Shorvon PJ, McHugh S, Diamant NE, Somers S, Stevenson GW. Defecography in normal volunteers: results and implications. *Gut.* 1989;30:1737-49.
- [7] Uhlig BE, Sullivan ES. The modified Delorme operation: its place in surgical treatment for massive rectal prolapse. *Dis Colon Rectum.* 1979;22:513-21.
- [8] Tsunoda A, Yasuda N, Yokoyama N, Kamiyama G, Kusano M. Delorme's procedure for rectal prolapse: clinical and physiological analysis. *Dis Colon Rectum* 2003;46:1260-5.
- [9] Bashar S, Anthony MV. Abdominal Approaches for Rectal Prolapse. *Clin Colon Rectal Surg.* 2008;21:94-9.
- [10] Bakshi G, Ranka S, Agarwal S, Shetty S V. Modified mesh rectopexy: a study. *J Postgrad Med.* 2000;46:265.
- [11] Mehendale VG, Chaudhari NC, Shenoy SN, Shah SB. Devadhar's operation for complete rectal prolapse: 25 years' experience. *Indian J Gastroenterol.* 2005; 24(1):9-11.
- [12] Tou S, Brown SR, Malik AI, Nelson RL. Surgery for complete rectal prolapse in adults. *Cochrane Database of Systematic Reviews.* 2008; 4: Art. No.: CD001758. DOI: 10.1002/14651858.CD001758.pub2.
- [13] Speakman CT, Madden MV, Nicholls RJ, Kamm MA. Lateral ligament division during rectopexy causes constipation but prevents recurrence: results of a prospective randomized study. *Br J Surg.* 1991;78:1431-3.
- [14] Madiba TE, Baig MK, Wexner SD. Surgical management of rectal prolapse. *Arch Surg.* 2005;140:63-73.
- [15] Marchal F, Bresler L, Ayav A, Zarnegar R, Brunaud L, Duchamp C, et al. Long-term results of Delorme's procedure and Orr-Loygue rectopexy to treat complete rectal prolapse. *Dis Colon Rectum.* 2005;48:1785-9.

- [16] Senapati A, Nicholls RJ, Thomson JP, Phillips RK. Results of Delorme's procedure for rectal prolapse. *Dis Colon Rectum*. 1994;37: 456-60.
- [17] Yakut M, Kaymakcioglu N, Simsek A, Tan A, Sen D. Surgical treatment of rectal prolapse. A retrospective analysis of 94 cases. *Int Surg*. 1998;83:53-5.
- [18] Senapati A, Gray RG, Middleton LJ, Harding J, Hills RK, Armitage NC, et al. PROSPER Collaborative Group. *Colorectal Dis*. 2013 Jul;15(7):858-68.
- [19] Lieberth M, Kondylis LA, Reilly JC, Kondylis PD. The Delorme repair for full-thickness rectal prolapse: a retrospective review. *Am J Surg*. 2009;197:418-23.
- [20] Fazeli.M, Kazemeini.A, Keshvari.A, Keramati.M. Delorme's Procedure: An Effective Treatment for a Full-Thickness Rectal Prolapse in Young Patients. *Ann Coloproctol*. 2013; 29(2): 60-5.

**PARTICULARS OF CONTRIBUTORS:**

1. Junior Resident, Department of General Surgery, Kasturba Medical College, Manipal University, Mangalore, India.
2. Associate Professor, Department of General Surgery, Kasturba Medical College, Manipal University, Mangalore, India.
3. Professor, Department of General Surgery, Kasturba Medical College, Manipal university, Mangalore, India.

**NAME, ADDRESS, E-MAIL ID OF THE CORRESPONDING AUTHOR:**

Dr. Poomachandra Thejeswi,  
Shreyas, Pragathi Colony, Near Baliga Stores, Bejai, Managalore, India.  
Phone: +919986874910, E-mail: drpoornachandra@gmail.com

**FINANCIAL OR OTHER COMPETING INTERESTS:** None.

Date of Submission: **Sep 30, 2013**

Date of Peer Review: **Feb 18, 2014**

Date of Acceptance: **Mar 16, 2014**

Date of Publishing: **May 15, 2014**