

Anomalous Branching Pattern of the Popliteal Artery (PA): A Case Report

SUHANI SUMALATHA¹, VINODHINI PERIYASAMY², RAMACHANDRA BHATT³,
ANTONY SYLVAN DSOUZA⁴, MAMATHA HOSAPATNA⁵

ABSTRACT

The Popliteal Artery (PA), which is the continuation of the Femoral artery, crosses the popliteal fossa at the distal border of popliteus; it divides into the Anterior and Posterior Tibial arteries.

The Posterior Tibial Artery (PTA) divides into terminal branches proximal to popliteus, in which case the Anterior Tibial Artery (ATA) sometimes descends anterior to the muscle. Either the Anterior tibial or the PTA may be reduced or increased in size. The dorsalis pedis artery (DPA) is the continuation of the ATA, distal to the ankle. It passes to the proximal end of the first intermetatarsal space, to complete the plantar arch, and provides the first plantar metatarsal artery. In the present case the PA bifurcates into two terminal branches at a higher level than the normal. The ATA was hypo plastic and entered the anterior crural region in front of the popliteus muscle and finally terminated above the knee joint. Further the PTA was also hypo plastic giving off a hyperplastic PL which pierced the interosseous membrane and on entering the dorsum of the foot, it prolonged as the DPA. The rest of the PTA continued its course distally and divided into its usual branches, the medial and lateral planter arteries. Awareness of these variations in the vascular branching patterns of the lower limb, acts as a guide during femero distal bypass grafting procedures and surgical and percutaneous vascular reconstructions.

Keywords: Dorsalis pedis, Peroneal artery, Per cutaneous vascular surgeries

INTRODUCTION

Peroneal artery (PL), branch of the PTA arises about 2.5cm distal to the popliteus, pass obliquely to fibula, descend along its medial crest in a fibrous canal between Tibialis Posterior (TP) and Flexor Digitorum Longus (FDL) reaching the inferior tibiofibular syndesmosis, it is divided into calcaneal branches [1].

DPA is the continuation of the ATA distal to the ankle. It passes on the dorsum of the foot to the first metatarsal space and turns into the sole between the heads of the first dorsal interosseous muscle to complete the plantar arch [1].

Perforating branch of the PL traverses the interosseous membrane about 5cm proximal to the lateral malleolus to enter the extensor compartment, where it anastomose with anterior lateral malleolar artery and also anastomose with the lateral tarsal artery. This branch enlarge and may replace DPA [1].

CASE REPORT

A case report of an anomalous branching pattern of the PA was found, during the routine dissection of the flexor compartment of the lower limb in the Department of Anatomy, KMC, Manipal.

The artery and their branches were painted with red color and allowed to dry. Level of their origin, course, variations in its branching patterns, calibrity of the lumen and its termination were noted and photographed.

The ATR is the first arterial branch of the Left PA. It originates at or above the articular surface of the tibial plateau, proximal to the popliteus muscle, gives a branch as lateral inferior genicular artery and passes above the interosseous membrane as ATA, which was hypo plastic.

The PTA arises distal to the popliteus descends as the Tibio-peroneal artery and bifurcates into a hyperplastic Peroneal artery and a hypo plastic PTA [Table/Fig-1].

The hypo plastic PTA gives nutrient artery to tibia, circumflex fibular artery, muscular branches to the flexor compartment, perforating branches, communicating branches, hyperplastic tortuous Medial

MMA and calcaneal branches. The MMA passes through the flexor retinaculum under the abductor hallucis, terminating as Medial and Lateral Plantar arteries on the plantar surface [Table/Fig-2a,b].

The hyperplastic PL arises distal to the popliteus and descends on the soleus to reach the inferior tibiofibular syndesmosis giving off calcaneal branches on the posterior and lateral surface of the calcaneus. The hyperplastic perforating branch replaces the DPA.

The hypo plastic ATA passes medial to the fibular head that enters the extensor compartment. It descends on the anterior aspect of the interosseous membrane, it approaches tibia and distally lies anterior to tibia. It gives malleolar branches and terminates by giving a communicating branch to the DPA [Table/Fig-3a], [Table/Fig-3b].

The replaced DPA, which is the continuation of the perforating branch of the PL, appears on the dorsum of the foot lateral to Peroneus Brevis, crosses from lateral to the medial side. DPA lies deep to skin, superficial fascia, inferior extensor retinaculum, Extensor Hallucis brevis.

DPA lies between the tendons of EHL and EDL. DPA gives medial and lateral tarsal arteries, arcuate artery, and enters the first dorsal metatarsal space as first dorsal metatarsal artery.

DISCUSSION

The variations in the branching pattern of the PA have been reported in previous journals as the ATA arising proximal to popliteus belongs to the type i) A-2. Also it falls under the type ii) B or iii) C, [2].

It is similar to ATA arises at or above the knee joint; Hypo plastic ATA; DPA replaced to PR [3]. This review was stimulated by technical difficulties encountered during the performance of arterial reconstruction in patients who required femorodistal bypass graft procedures. The presence of gradual tapering of the hypo plastic artery, the lack of collateral reconstitution distally, and a straight, non-undulating appearance of the distal segment of the PR reaching the DPA or distal PTA favor against atherosclerosis [2].

Another radiological study of femoral angiograms on 495 lower extremities was performed to view the tibial artery anatomy, and found that 7.8%


of the cases revealed variations. The majority of those variations were components of high-origin ATA and trifurcation patterns [4].

It was reported the course of ATA from the ventral surface of the popliteus was 42%. The proximity with the tibial cortex makes it vulnerable during knee arthroplasty and high tibial osteotomy [5].

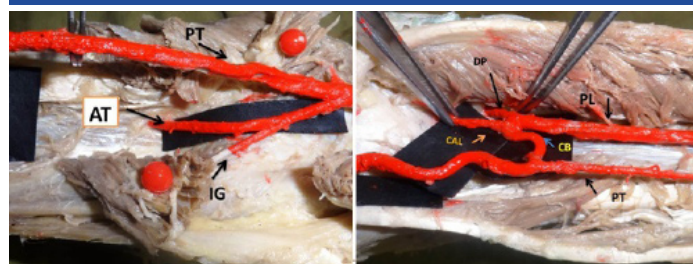
It was reported in previous studies that the course of ATA could either be from the ventral or dorsal surface of the popliteus muscle [5,6,7]. A ventral course was observed in 1-2.1% of the cases [2,3,6,7,8,9].

CONCLUSION

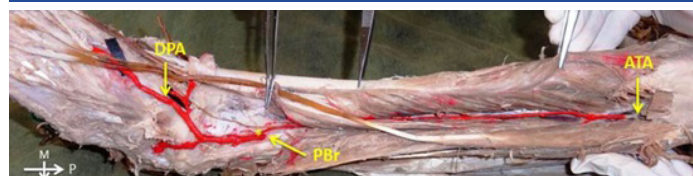
Embryonic development of arteries of the lower limb results from the union of dorsal and ventral systems, explaining many variations at different levels. Arthroscopic knee surgery is the recently upcoming surgical interventional field. Surgical neurovascular characteristics and anatomical variations have gained importance due to such surgical therapeutic needs in these regions.



[Table/Fig-1]: Showing the higher termination of the Left Popliteal Artery. (ATA-Anterior Tibial Artery, PTA-Posterior Tibial Artery, PrA-Peroneal Artery, PBf-Perforating Branch, *-Communicating Branch, >-Popliteus Muscle)

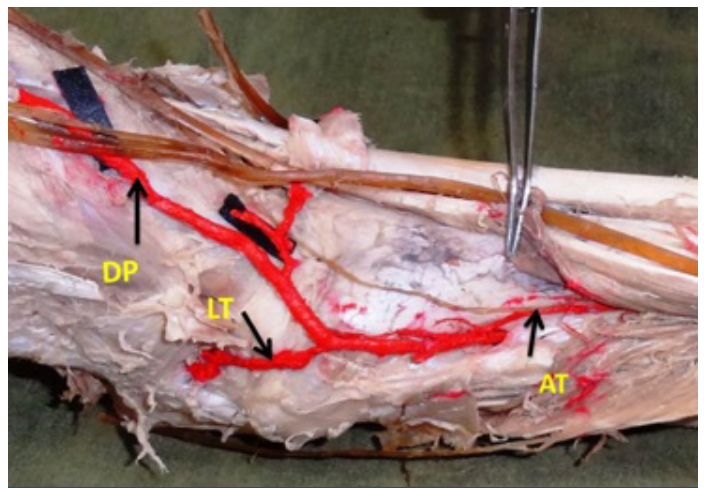


[Table/Fig-2a,b]: a) Shows the branching pattern in the popliteal fossa b) Shows the cross communications and hyperplastic Posterior Tibial artery.



[Table/Fig-3a]: Showing the anastomosis (*) between the ATA and the PBr of the PrA; PBr. Further continuing as DPA

Awareness of these variations is important for the evaluation of lower extremity arteriograms and has clinical implications for vascular surgeons and interventional radiologists regarding vascular grafting, direct surgical repair, transluminal angioplasty, embolectomy and diagnosis of arterial injury.



[Table/Fig-3b]: Shows the communication between hypoplastic ATA and DPA

ABBREVIATIONS

PA-Popliteal Artery, ATA-Anterior Tibial Artery, PTA-Posterior Tibial Artery, PL-Peroneal Artery, DPA-Dorsalis Pedis Artery.

REFERENCES

- [1] Standring S, Gray's Anatomy. 40th Ed., London, Churchill Livingstone. 2008; 1408, 1424.
- [2] Ducksookim MD, Dae Orron. M. Surgical significance of popliteal arterial variants (a unified angiographic classification). 1989; 776-81.
- [3] Kil SW, Jung GS. Anatomical variations of the popliteal artery and its tibial branches: analysis in 1242 extremities. *Cardiovascinterventradiol.* 2009; 32: 233-40.
- [4] Slaba S, Abi Khalil S, Younan T. Unusual variation of the popliteal artery branches. [5] Sadler WD. Lang man's Human embryology, 10th edition.
- [6] Adachi B. Das arteriensystem der japaner, band 2. Kyoto, kenkyusha. 1928; 198-201.
- [7] Trotter M. The level of termination of the popliteal artery in the white and the negro. *Am j physanthropol.* 1940; 27: 109-18.
- [8] Klecker RJ, Winalski CS. The aberrant anterior tibial artery: magnetic resonance appearance, prevalence, and surgical implications. *Am j sports med.* 2008; 36: 720-27.
- [9] Tindall AJ, Shetty AA, James KD. Prevalence and surgical significance of a high-origin anterior tibial artery. *J orthopsurg (hongkong).* 2006; 14: 13-16.

PARTICULARS OF CONTRIBUTORS:

1. Senior Grade Lecturer, Department of Anatomy, Kasturba Medical College, Manipal University, Manipal, Karnataka, India.
2. Lecturer, Department of Anatomy, Kasturba Medical College, Manipal University, Manipal, Karnataka, India.
3. Professor, Department of Anatomy, Kasturba Medical College, Manipal University, Manipal, Karnataka, India.
4. Professor and Head, Department of Anatomy, Kasturba Medical College, Manipal University, Manipal, Karnataka, India.
5. Assistant Professor, Department of Anatomy, Kasturba Medical College, Manipal University, Manipal, Karnataka, India.

NAME, ADDRESS, E-MAIL ID OF THE CORRESPONDING AUTHOR:

Dr. Mamatha Hosapatna,
Assistant Professor, Department of Anatomy, Kasturba Medical College, Manipal University, Manipal-576104, Karnataka, India.
Phone: 9535681514, E-mail: mamatha2010@yahoo.com

Date of Submission: Apr 14, 2013

Date of Peer Review: Jun 29, 2013

Date of Acceptance: Apr 05, 2014

Date of Publishing: Jun 20, 2013

FINANCIAL OR OTHER COMPETING INTERESTS: None.