

Malignant Melanoma of the External Auditory Canal

CHEBROLU GOWTHAMI¹, PRASANNA KUMAR², A RAVIKUMAR³,
LEENA DENNIS JOSEPH⁴, SWAMINATHAN RAJENDIRAN⁵

ABSTRACT

Primary malignant melanoma of the external auditory canal is rarely reported. Malignant melanoma of the ear is estimated to occur in 1-4% of all skin melanomas and about 7-20% of melanomas of the head and neck region. The pathophysiology of these tumours is different from other skin lesions because of their anatomical and functional characteristics. The case presented is of a 11 year old female child with malignant melanoma of the external auditory canal confined to the right side, who initially presented with right ear pain, bleeding, post auricular swelling and also a mass in the external auditory canal which was thought to be an aural polyp in the right ear. Excision of the tumour was accomplished by a radical mastoidectomy. It was confirmed to be malignant melanoma after histopathological examination and Immunohistochemistry. Despite all efforts, the patient succumbed to the disease after receiving three cycles of chemotherapy. Even though this malignancy is rarely found in the external auditory canal, it should be expanded into the differential diagnosis of an aural polyp and a post aural abscess. The incidence, symptoms, investigations, treatment and prognosis of malignant melanoma of the external auditory canal is discussed in this article.

Keywords: External auditory canal, HMB 45, IHC, Malignant, Melanoma

CASE REPORT

A 11-year-old female presented with a history of pain and swelling behind the right ear for the past 2 weeks. A diagnosis of right side mastoid abscess with aural polyp was given by a local physician who put her on antibiotics and recommended incision and drainage of the post aural swelling. She also developed intermittent bleeding from the right ear and the post auricular region for which she was referred to our hospital.

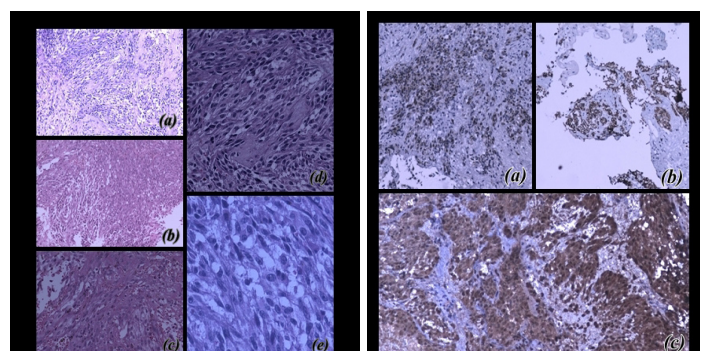
At presentation, the patient was in severe pain, afebrile and her vitals were stable. There was a 3x3cm spherical swelling in the right post auricular region. The swelling was variable in consistency and very tender. The skin over the swelling was stretched, shiny and smooth except for a small 0.5x0.5cm irregular ulcer, with indurated margins in the inferior part of the swelling which was bleeding. A provisional diagnosis of acute mastoiditis with subperiosteal abscess with aural polyp was made with a differential diagnosis of tubercular otitis media or a fungal granuloma. The patient was taken up for an incisional biopsy and cauterization of the bleeding mass was done under general anesthesia. During surgery, this mass was found to be firm in consistency, highly vascular and friable. The mass in the External Auditory Canal (EAC) was found to be an extension of the post auricular mass. Histopathological study was suggestive of spindle cell tumor. However the decision for complete resection of the tumor was taken by the treating physicians and hence immunohistochemistry was decided to be done on the rest of the tissue after complete excision. The patient was then re-evaluated with a chest X-ray, ultrasound abdomen and whole body scan with no evidence of metastasis. CT scan of the right temporal bone demonstrated a large ill defined homogenous, moderately enhancing infiltrative soft tissue lesion occupying the entire EAC causing widening and erosion of anterior, posterior and inferior walls of the bony part of the EAC. Scutum, long process and the lenticular process of incus appeared irregular and eroded. The patient was planned for a complete excision of the mass with radical mastoidectomy. The tissue was sent for histopathological examination which was reported as malignant melanoma with the margins free of disease [Table/Fig-1a-e]. The tumor cells were spindle

out with prominent eosinophilic nucleoli suggesting a melanoma. However the lesion was amelanotic. Hence immunohistochemistry was done. Tumor cells were strongly positive for Vimentin, S100 and HMB 45 which suggests of melanocytic origin [Table/Fig-2a-c]. Also, a bone scan showed increased tracer concentration in the right temporal bone-possibility of a neoplastic lesion.

The patient had an uneventful recovery post-operatively. An opinion from medical and radiation oncologist was taken post-operatively. The patient was prescribed *T.Cloxacillin* and *T.Bevon*. The patient was then lost to follow up. After six months, a small mass in the deep anterior canal wall was noted. An oncologist opinion was sought and chemotherapy was started with Dacarbazine 600mg. The patient underwent 3 cycles of chemotherapy and later succumbed to the disease after a further 3 months.

DISCUSSION

Carcinoma of the external auditory canal is a rare head and neck malignancy. Squamous cell carcinoma and adenoid cystic carcinomas are the most common type of external auditory canal cancers, though many other tumor types may also be seen occasionally. The early identification of these tumours is essential to limit tumour extension [1,2].



[Table/Fig-1]: H & E images showing the spindle cell tumour (a & b) H & E X100; (c & d) H & E X200; (e) H & E X400

[Table/Fig-2]: By Immunohistochemistry, the tumour cells were strongly positive for (a & b) HMB 45 x 100; (c) S100 X 100

Malignant Melanoma is a malignant tumour of the melanocytes. Malignant melanoma of the pinna comprises approximately 7% to 14% of all melanomas of the head and neck. Malignant melanoma of the ear other than the pinna, arising in other subsites of the ear is however uncommon. Melanoma of the ear is labeled as a high risk lesion because of its propensity to present as a thicker lesion than other head and neck melanomas; any cutaneous melanoma thicker than 4mm is considered to have a poor prognosis [3]. Thickness of the lesion is the most sensitive indicator for development of metastasis and disease free survival. Poor prognostic factors for malignant melanoma in the EAC include delayed diagnosis because of its deep location, a greater tendency for metastasis due to the thin epithelium and a short distance between the tumour and the dermal lymphatics. Additionally, the tumour can arise as a primary lesion or may present as a metastatic deposit in this site. The mean age at diagnosis is reported to be around 50 years even though all age groups are affected [4].

Approximately 10% of all patients with melanoma have a family history of melanoma.

Patients often present with long standing otalgia, otorrhoea, bloody discharge and loss of hearing. These symptoms are quite non-specific and can be associated with chronic infections of the EAC. Another presentation of the lesion is in the form of an aural polyp. Besides, high index of suspicion is raised when a pigmented lesion changes colour, enlarges rapidly or ulcerates with poor healing. All the suspected lesions should be biopsied and the exact histopathology should be established for an accurate diagnosis to rule out the other tumours put across in the differential diagnosis [4].

The histopathological examination demonstrates sheets and nests of atypical melanocytes. The cells have large pleomorphic nuclei with prominent nucleoli. The cytoplasm contains considerable amounts of melanin pigment [3]. But the pigment may or may not be present. Even in our case the tumour was amelanotic. The melanocytes are predominantly epithelioid with few elongated spindle shaped cells. The tumour can also display areas of necrosis and frequent mitosis. The skin adjacent to the invasive portion of the tumour happens to display marked melanocytic proliferation along the dermo-epidermal junction. The melanocytes in this region would be haphazardly arranged and many of them will be spindle shaped.

By immunohistochemistry, the tumour cells are positive for HMB45 and S100. Melanin pigments can be confirmed by Fontana-Masson

stain. Radiological investigations like the CT scan exhibit soft tissue mass filling the external auditory canal [4].

Surgery currently offers the best probability for cure of malignant melanoma of the head and neck. The surgical management of the head and neck melanomas is often limited by the surrounding anatomical structures. Extension of the tumour into the mastoid cavity and EAC may necessitate concomitant subtotal temporal bone resection, mastoidectomy, and a parotidectomy. The optimal management of malignant melanoma of the ear is total surgical excision with atleast a 1-2 cm safety margin in consideration of possible satellite lesions. At times, it is difficult to excise malignant melanomas inside the EAC because of the limited space between the lesion and the neighbouring delicate structure of the middle and inner ear. The recurrence and mortality rates are very high in this tumour. Presently, not only the complete resection but also the reconstruction of the auditory canal done is essential for better quality of life post-operatively. Several methods using free flaps have been reported. These methods prevent stenosis, chronic infection and wound healing. However, skin grafting is preferred because of technical simplicity [5,2].

CONCLUSION

The differential diagnosis of a polypoidal lesion and abscess should include malignant melanoma. With heightened awareness, earlier biopsy of atypical growths on any cutaneous surface will result in rapid diagnosis of melanoma. This highlights malignant melanoma as a grave disease with a systemic predisposition and poor prognosis where long-term follow up is necessary in spite of good locoregional control.

REFERENCES

- [1] Sewon Kang, Raymond LB, Fiona GC, Greg R, Joseph BN, Arthur J. S. Primary Malignant Melanoma Of The External Auditory Canal: A Case Report With Presentation As An Aural Polyp. *The Am J Of Otolaryngology*. 1992;13:94-196.
- [2] Hiroshi Hoshikawa, Takenori Miyashita, Nozomu Mori. Surgical Procedures for External Auditory Canal Carcinoma and the Preservation of Postoperative Hearing. *Case Reports in Surgery*. 2012;doi:10.1155/2012/841372.
- [3] Milbrath MM, Campbell B H, Madio G, Janjan N A. Malignant Melanoma of the External Auditory Canal. *Am J Clin Oncol*. 1998;21:28-30.
- [4] Chiu-Hung Lin, Tzong-Yang Tu, Pen Yuan Chu, Yi-Wei Chen, Wing-Yin Li. Malignant Melanoma of The External Auditory Canal. *Tzu Chi Med Journal*. 2009;21:244-47.
- [5] Ozmen OZTURK, Tekin BAGLAM, Cuyne UNERI, Sevgi KULLU. Primary malignant melanoma of the middle ear mucosa: a case report. *Kulak Burun Bogaz Ihtis Derg* 2006;16:83-86.

PARTICULARS OF CONTRIBUTORS:

1. MBBS Student, Sri Ramachandra University, Porur, Chennai, India.
2. Associate Professor, Department of ENT, Porur, Chennai, India.
3. Professor and Head of the Department, Department of ENT, Porur, Chennai, India.
4. Professor, Department of Pathology, Sri Ramachandra University, Porur, Chennai, India.
5. Professor, Department of Pathology, Sri Ramachandra University, Porur, Chennai, India.

NAME, ADDRESS, E-MAIL ID OF THE CORRESPONDING AUTHOR:

Dr. Leena Dennis Joseph,
Professor, Department of Pathology, Sri Ramachandra University, Porur, Chennai, India.
Phone : 09840273620, E-mail : leenadj@gmail.com

FINANCIAL OR OTHER COMPETING INTERESTS: None.

Date of Submission: **Feb 02, 2014**
Date of Peer Review: **May 14, 2014**
Date of Acceptance: **Jun 17, 2014**
Date of Publishing: **Aug 20, 2014**