

Two Rare Presentations of Epidermal Cyst

ARUN RAO¹, BHARATHI RAO², MARIA JOSEPH KURIAN³, RADHA R. PAI⁴

ABSTRACT

Epidermal cysts are very rare. It is more common in males than in females and the most common site of presentation are the hairy sites. We came across two rare cases of epidermal cysts.

In one case, a parous lady presented with an adnexal mass and D/D of broad ligament fibroid or ovarian mass was considered which turned out to be a cyst containing cheesy pultaceous material. In the other case, a parous lady presented with a mass arising from the posterior fourchette that contained cheesy pultaceous material on excision. In both cases histopathology confirmed it to be epidermal cysts.

Epidermal cysts known for its rare incidence by itself is now found to be presenting at rare sites which emphasizes on the need for further research into the etiopathogenesis of these cysts and its development at the various sites of the body.

Keywords: Adnexal cyst, Epidermal cyst, Vulval cyst

CASE REPORT

Case 1

A 45-year-old parous lady came with history of excessive bleeding per vagina for 7 days following a four month period of amenorrhoea. She had no history of pain abdomen, mass per abdomen, fever, weight loss or loss of appetite and no bowel or bladder complaints. Her previous menstrual cycles were regular and she had no history of intake of any hormonal medications. She had no significant past medical or surgical history. On per vaginal examination in cervix was deviated to the right side, uterus felt 12 weeks size, anteverted, and an 8 x 6 cm mass was felt in the left fornix separately from the uterus with no tenderness and no transmitted mobility.

An ultrasound of abdomen and pelvis revealed a bulky uterus with 2.5 x 3.1 cm myoma in posterior wall and a 10.5 x 7.8 cm large heterogenous mass lesion in left adnexa with minimal vascularity. Right ovary was normal. CA-125 was done and was normal. A differential diagnosis of broad ligament fibroid or ovarian mass was considered.

She was posted for total abdominal hysterectomy and bilateral salpingo-oophorectomy. Intra-operatively a bulky uterus with bilateral normal fallopian tubes and ovaries was found and a 10 x 10 cm cyst arising from the left posterior aspect of lateral pelvis with the base originating from the hollow of the sacrum was found separate from the uterus. Cyst wall opened spontaneously and cheesy pultaceous material was evacuated. Cyst wall was traced down and dissected as close to its origin. Uterus with cervix on the right and the cheesy material from the cyst on the left [Table/Fig-1].

Post-operative period was uneventful and she was discharged on 7th post-operative day. After 3 weeks she had come back with high grade fever with chills and rigors. On examination she was found to have a tender 6 x 6 cm mass again in the left fornix. An ultrasound showed features of an abscess. She was started on broad spectrum antibiotics and managed conservatively. She had recovered and was discharged.

Case 2

A 38-year-old parous lady had come with a mass protruding in vulval region which was initially small in size and progressed to present

size in 4 years. She had no history of trauma, pain in the mass, mass per abdomen, fever or any bowel or bladder complaints. She had no menstrual irregularities and no significant past medical or surgical history. On local examination a 5 x 6 cm mass was found at the vulva arising from the posterior fourchette which was mobile, firm in consistency, with smooth and normal skin surface [Table/Fig-2]. An ultrasound abdomen and pelvis was done which showed no significant abnormalities.

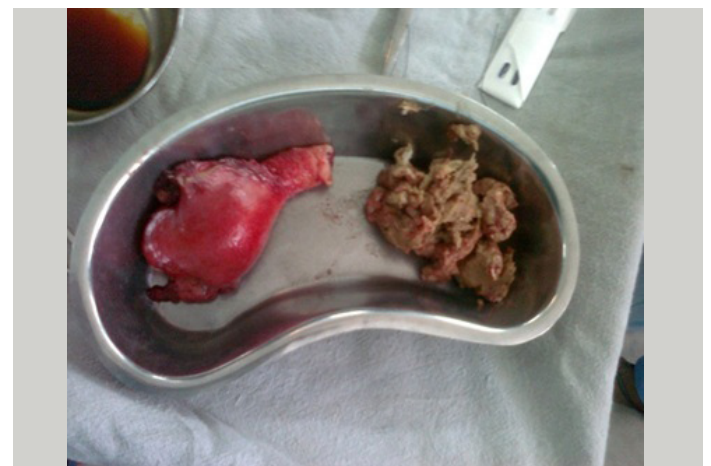A cyst excision was done and it contained cheesy pultaceous material. Post-operative period was uneventful and she was discharged on 4th post-operative day. On follow-up she had no complaints or recurrence.

The histopathological report of both the specimens confirmed the diagnosis of epidermal cyst.

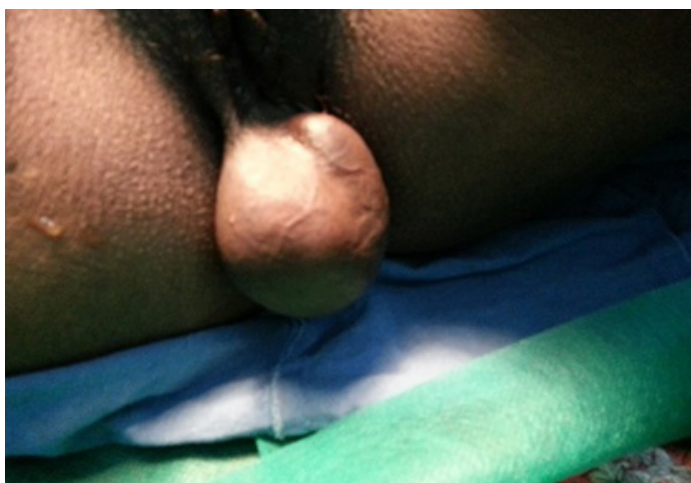In both there was skin with underlying cyst wall lined by granular layer, exfoliative squamous epithelium and keratin flakes [Table/Fig-3,4].

DISCUSSION

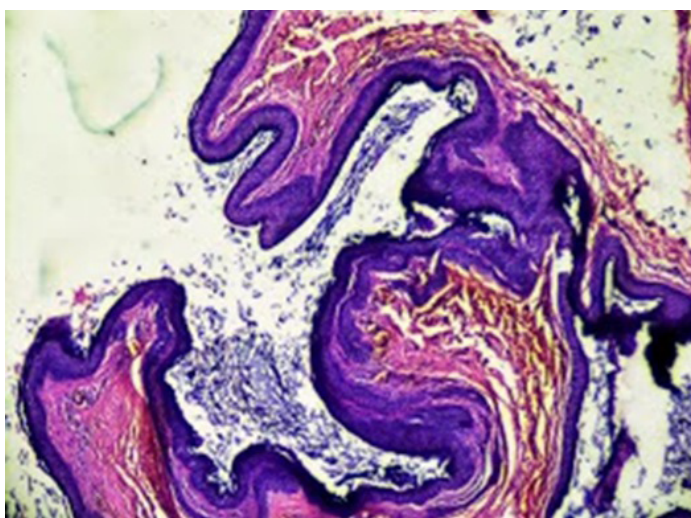
Epidermoid cysts are benign slow growing lesions which arise due to implantation of epidermis into the dermal layer of skin. They are more



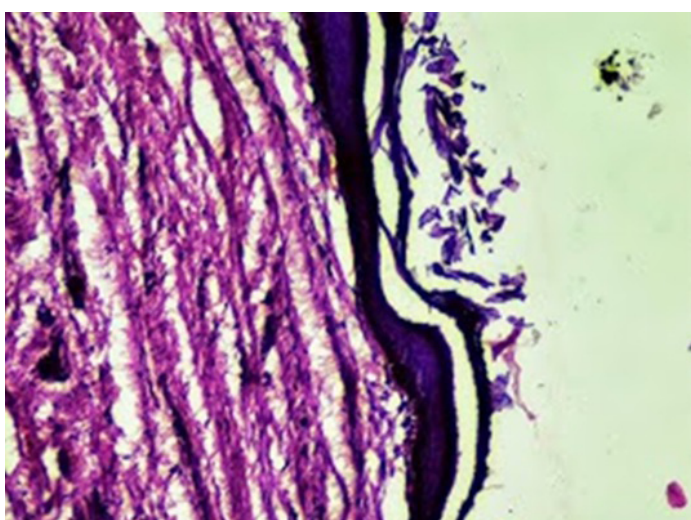
[Table/Fig-1]: Uterus with cervix on the right and the cheesy material from the cyst on the left



[Table/Fig-2]: Vulval mass arising from the posterior fourchette



[Table/Fig-3]: Skin with underlying cyst wall lined by granular layer, exfoliative squamous epithelium and keratin flakes that confirmed the diagnosis of epidermal cyst



[Table/Fig-4]: Features suggestive of epidermal cyst

common in men as compared to women and commonly present in the third or fourth decade of life. The common sites of presentation are the hairy areas. Scalp-90% and the other sites that include face, trunk, neck extremities and genital region in descending order.

Genital cysts are less common and in women it usually appear as a mass in vulva/clitoris/perineum [1,2].

Large cysts can displace anus, vagina and may extend into pelvic space adjacent to the rectum [3].

The various theories in literature stating the etiopathogenesis of epidermal cysts:

- Aberrant embryogenesis, with ectodermal cells misplaced during cellular differentiation.
- Trauma, injury or pressure to an area especially extremities transplants epidermal cells into the dermis.
- The inflammation and cystic changes of pilosebaceous structures in the dermis would probably explain the presence of cysts on the face, neck, trunk and genital region.
- Infection of eccrine ducts with Human Papilloma Virus would probably be the causative factor of cysts on palms and soles [4].

In patients with multiple epidermal inclusion cysts, the physician should be keen to exclude a gastrointestinal neoplasm, due to the association with Gardner syndrome [5]. Differential diagnosis include lipoma and neurofibroma.

Complications: Infection is most common complication leading to an abscess and patient becomes symptomatic. In a study by Bauer, there was a 2.2% rate of malignant degeneration of epidermal inclusion cysts into squamous-cell carcinoma, with a majority of the carcinomas being well differentiated [6].

Investigations: Includes USG, FNAC, CT, MRI where CT/MRI is required to know the extent of the mass when planning for a surgical excision.

Treatment: Cyst excision is the treatment of choice. Careful and meticulous dissection is required to avoid injury to nearby vital structures and spillage of contents which would otherwise lead to wound infection and probably recurrence. There is a 3% recurrence rate noted and reported. Hence the entire cyst wall must be removed [5].

In the two cases, we could not find any contributory factors for the formation of the cyst. In the first case clinically and sonologically we were in the impression of the cyst being ovarian in origin and to our surprise it was a cyst of an entirely different entity. In both the cases ultrasound was done.

Histopathology later confirmed the diagnosis of epidermal cyst and showed skin with underlying cyst was lined by granular layer, exfoliative squamous epithelium and keratin flakes.

Though epidermal cysts are commonly seen in the face and scalp it can present at unusual sites as seen in the two cases. The other rare presentations of an epidermal cyst in women as documented in literature are the gastrointestinal tract (Caecum) and retroperitoneum which presented as an adnexal mass, as a recurrent perianal sinus and a cyst in the clitoris [7-10]. The largest cyst reported so far similar to Case 2 is 17.8 × 13.18 cms in 2010 [11] and second largest cyst 15 × 10 cms in 2012 [12].

CONCLUSION

Epidermal cysts are known for its rare incidence is now found to be presenting at rare sites which emphasizes on the need for further research into the etiopathogenesis of these cysts and its development at the various sites of the body.

REFERENCES

- [1] Bailey and Love's Short practice of Surgery 25th edition. Skin and subcutaneous tissue; 39: 602.
- [2] B.N Datta Text book of Pathology, 2nd edition. Skin and skin tumours dermatopathology.
- [3] Fujimoto T, Murakami K, Kashimada A. Large epidermoid cyst involving the ischiorectal fossa: MR Demonstration. *ClinImaging*. 1993; 17: 146-48.
- [4] Weedon D. Weedon's skin pathology. 3rd Edition. Elsevier; 2010: 442-46.
- [5] Pandya KA, Radke F. Benign skin lesions: Lipomas, epidermal inclusion cysts, muscle and nerve biopsies. *SurgClin North Am*. 2009; 89: 677-87.
- [6] Bauer BS, Lewis VL Jr. Carcinoma arising in sebaceous and epidermoid cysts. *Ann PlastSurg*. 1980; 5: 222-26.

- [7] Kryspin Mitura, Romanczuk Mikolaj, Mitura Alicja. An atypical site of retroperitoneal epidermoid cyst in middle age woman. *International Journal of Surgery Case Reports*. 2013; 4(1): 85-87.
- [8] V Jain, S Misra, S Tiwari, K Rahul, and H Jain. Recurrent Perianal Sinus in Young Girl Due To Pre-sacral Epidermoid Cyst. *Ann Med Health Sci Res*. 2013; 3(3): 458-60.
- [9] Hale DEMIR, Begüm AYDOGAN, Hayrettin SAHIN, Pelin ÖCAL, Sennur ILVAN. Epidermoid cyst of the cecum: A case report. *Turk J Gastroenterol*. 2012; 23 (4): 406-09.
- [10] Schmidt A, Lang U, Kiess W. Epidermal cyst of the clitoris: a rare cause of clitorimegaly. *Eur J Obstet Gynecol Reprod Biol*. 1999 Dec; 87(2): 163-65.
- [11] Houdek Mt, Warneke JA, Pollard CM, Lindgren EA, taljanovic MS. Giant epidermal cyst of the gluteal region. *Radiology Case Reports*. (online) 2010;5:476.
- [12] Bharati VH, Bharathi Raja, Nitin Rao. Giant Epidermoid Inclusion Cyst in the Ischiorectal Fossa: A Case Report. *Journal of Clinical and Diagnostic Research*. 2012; 6(1): 103-05.

PARTICULARS OF CONTRIBUTORS:

1. Professor and Head, Department of Obstetrics and Gynaecology, Kasturba Medical College, Mangalore, Manipal University, India.
2. Associate Professor, Department of Obstetrics and Gynaecology, Kasturba Medical College, Mangalore, Manipal University, India.
3. Junieur Resident, Department of Obstetrics and Gynaecology, Kasturba Medical College, Mangalore, Manipal University, India.
4. Professor and Head, Department of Pathology, Kasturba Medical College, India.

NAME, ADDRESS, E-MAIL ID OF THE CORRESPONDING AUTHOR:

Dr. Maria Joseph Kurian,
Valliacherril House, Cheruvally Lane, Gandhipuram, Sreekaryam P.O., Thiruvananthapuram-695017, India.
Phone: 9538118153, E-mail: mjk1085@gmail.com

Date of Submission: **Dec 18, 2013**
Date of Peer Review: **Jan 17, 2014**
Date of Acceptance: **Mar 03, 2014**
Date of Publishing: **Oct 20, 2014**

FINANCIAL OR OTHER COMPETING INTERESTS: None.