

# Skin to Serosa: Scar Endometrioma

MAYA MENON<sup>1</sup>, SRIDEVI. T.A.<sup>2</sup>, CHANDRIKA.P.N.<sup>3</sup>, SATHISH SELVAKUMAR.A.<sup>4</sup>

## ABSTRACT

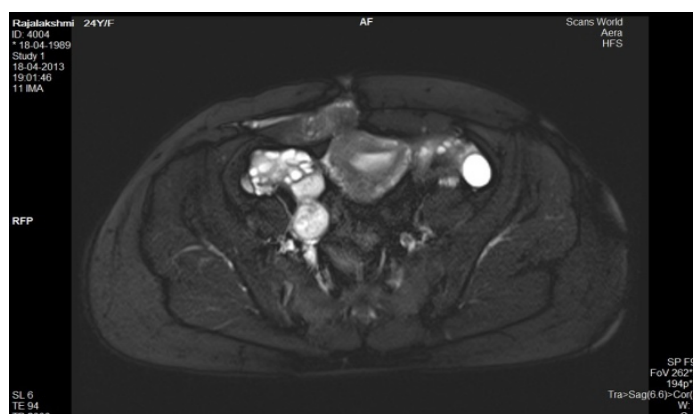
Extra pelvic endometriosis, an underappreciated and misdiagnosed gynaecological problem has been reported here for its rare location. Patient presented with swelling and cyclical pain over vertical scar (caesarean). Diagnosis was made on high index of clinical suspicion which was complimented by Magnetic Resonance Imaging (MRI). Scar endometrioma extended from the skin upto the uterine serosa which is extremely rare. Wide excision of endometrioma followed by mesh repair was done. Histopathology confirmed the diagnosis.

**Keywords:** Endometriosis, Scar endometrioma, Uterine wall

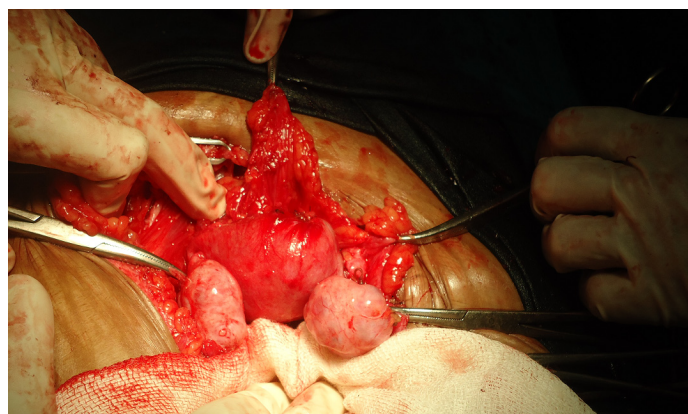
## CASE REPORT

A 27 year old para 1, live 1, previous caesarean section, last child birth 7 years back came with complaints of pain & swelling at the incision site since 4 years. No history of discharge from mass. Patient had been a frequent visitor to primary healthcare for same complaint on and off. Examination showed a 5x4cms oblong mass close to right paramedian scar, tender on palpation. Ultrasound abdomen showed hypoechoic lesion in abdominal wall to the right of midline. Differential diagnosis of paraumbilical hernia / Endometrioma was made clinically. The diagnosis was complimented by MRI which showed 52 mm x 17mm size ill-defined hypointense lesion in anterior abdominal wall tethering fundus of uterus with minimal free fluid in the pelvis [Table/Fig-1]. This helped us in our plan for laparotomy in order to conserve her uterus.

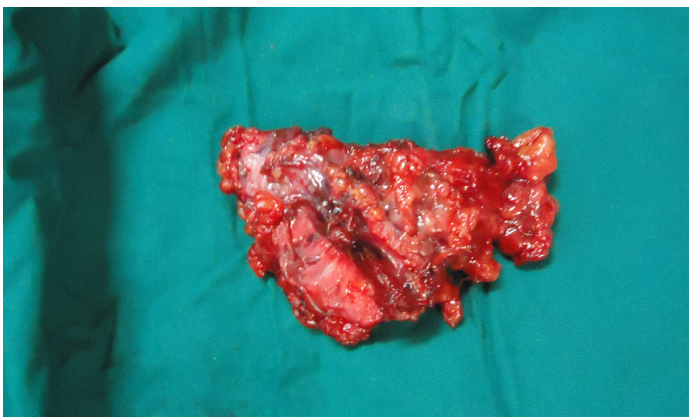
Patient was posted for wide excision of lump. During laparotomy a hard indurated mass of 5x4 cms closely adherent to rectus sheath was found [Table/Fig-2]. During dissection bluish brown spots were identified more in favour of endometrioma. The peritoneum of anterior abdominal wall was opened with difficulty. On further dissection omentum, right tube, left ovary and uterine serosa were found adherent to anterior abdominal wall at the scar site. Uterus was released from the scar tissue followed by enmasse excision of lump [Table/Fig-3]. Uterine serosa was closed intermittently with 3-0 vicryl. Irrigation done and Interceed was kept to prevent adhesions. Rectus sheath defect was closed with prolene mesh and suction drain kept. Postoperative recovery was uneventful. Specimen sent for histopathological examination which confirmed the diagnosis [Table/Fig-4].



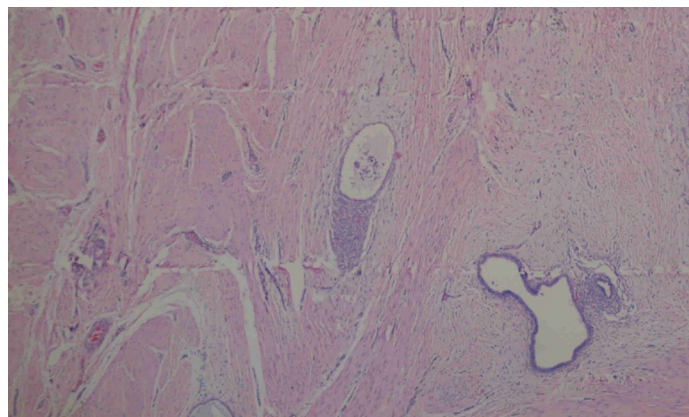
[Table/Fig-1]: MRI Axial T2 weighted images



[Table/Fig-2]: Encapsulated endometrioma adherent to uterine wall



**[Table/Fig-3]:** Macroscopy; greyish yellow areas appearing fibrosed & congested with thin blood vessels identified



**[Table/Fig-4]:** Microscopy; multiple sections show fibro collagenous tissue with dilated endometrial glands surrounded by the stromal cells.(H&E, 400X)

occur in ectopic endometriosis and thus histologic confirmation is essential. Regular follow up is required to detect any recurrence.

## CONCLUSION

Thus in the era of increasing caesarean section even rare conditions like scar endometrioma are becoming increasingly common. A high degree of clinical suspicion and proper knowledge of the area of involvement with the expertise of imaging will guide the surgeon for adequate clearance. Although recurrences can occur, surgical excision can highly improve the patient's quality of life. For prevention of occurrence of scar endometriosis abdominal wall should be

cleaned thoroughly and irrigated vigorously with high jet solution before closure. This article is reported as scar endometrioma extending upto the uterine wall, which is extremely rare.

## REFERENCES

- [1] Wasfie T, Gomez E, Seon S, Zado B. Abdominal wall endometrioma after caesarean section: a preventable complication. *Int Surg.* 2002, 87: 175-77.
- [2] Bazot M, Darai E, Hourani R, Thomassin I, Cortez A, Uzan S, Buy JN. Deep pelvic endometriosis: *MR imaging for diagnosis and prediction of extension of disease Radiology.* 2004 Aug; 232(2):379-89.
- [3] Goel P, Sood S S, Romilla, Dalal A. Cesarean scar endometriosis - Report of two cases. *Indian J Med Sci.* 2005;59:495-98.

### PARTICULARS OF CONTRIBUTORS:

1. Associate Professor, Department of Obstetrics and Gynaecology, ESIC Medical College & PGIMSR K.K.Nagar, Chennai, India.
2. Professor, Department of Obstetrics and Gynaecology, ESIC Medical College & PGIMSR K.K.Nagar, Chennai, India.
3. Post Graduate, Department of Obstetrics and Gynaecology, ESIC Medical College & PGIMSR K.K.Nagar, Chennai, India.
4. Assistant Professor, Department of Pathology, ESIC Medical College & PGIMSR K.K.Nagar, Chennai, India.

### NAME, ADDRESS, E-MAIL ID OF THE CORRESPONDING AUTHOR:

Dr. Maya Menon,  
144 K, Vaigai Railway Quarters, Sterling Road, Nungambakkam, Chennai-600034, India.  
Phone : 9444477791, E-mail : mayasree@gmail.com

**FINANCIAL OR OTHER COMPETING INTERESTS:** None.

Date of Submission: **Feb 02, 2014**  
Date of Peer Review: **Jun 03, 2014**  
Date of Acceptance: **Jun 17, 2014**  
Date of Publishing: **Oct 20, 2014**