

# Drug Induced Gingival Overgrowth: A Rare Case Report

SETU MATHUR<sup>1</sup>, ROHIT KUMAR KHATRI<sup>2</sup>, RANJAN MATHUR<sup>3</sup>, RASHI SRIVASTAVA<sup>4</sup>, B.P. NAG<sup>5</sup>

## ABSTRACT

Gingival overgrowth is well documented side effect associated with three major classes of drugs viz, anticonvulsants, calcium channel blockers, and immunosuppressants. Despite our greater understanding of pathogenesis of Drug induced Gingival Overgrowth (DIGO), its treatment still remains a challenge for the periodontists and treatment is still largely limited to maintenance of improved level of oral hygiene and surgical removal of overgrown tissue. Dental Surgeons need to discuss this issue with their medical colleagues and to practice care while prescribing the drugs associated with gingival overgrowth. The aim of present article is to report a rare case where even after extraction of all teeth; the enlargement did not subsided for one month.

**Keywords:** Calcium channel blockers, Drug-induced gingival overgrowth, Gingivectomy

## CASE REPORT

A 50-year-old, female Muslim patient reported to Department of Periodontics KLES Institute of Dental Sciences, Belgaum, with the chief complaint of enlargement of gums since last one year. On intraoral examination, both the maxillary and mandibular arches were edentulous with overgrowth of overlying soft tissue [Table/Fig-1] was present. The soft tissue overlying edentulous arches was nodular and erythematous in appearance and showed spontaneous bleeding on touch and was painful. On taking detail case history, patient reported that she got all her teeth extracted, 20-30 days back due to generalized severe mobility associated with them by local dentist in her village. Medical and drug history of the patient revealed that patient was known hypertensive and was on medication since last five years (Amlodipine 10 mg twice daily).

Orthopantomograph [Table/Fig-2] showed unhealed extraction sockets. Routine blood investigation values were in normal range including bleeding time and clotting time. Based on Patients history, clinical evaluation and radiographic assessment a provisional diagnosis of amlodipine induced drug enlargement superimposed with inflammation was established.

### Treatment Done

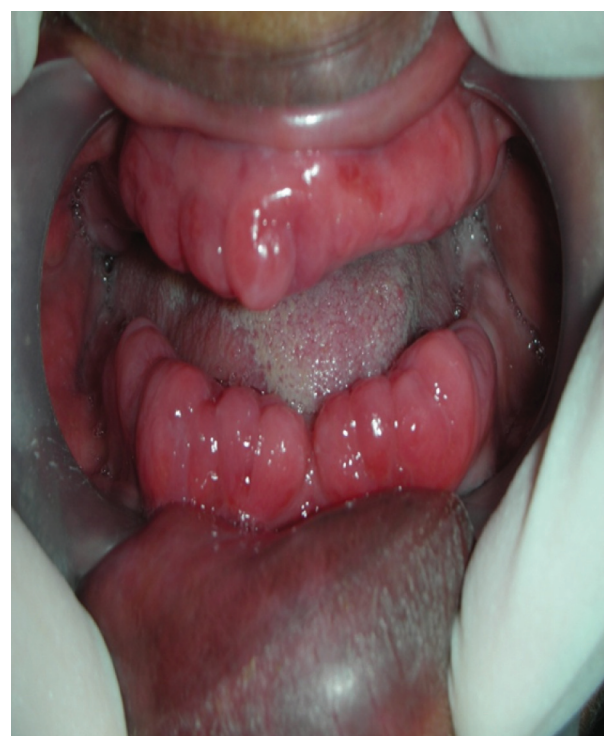Patient was referred to physician for his consent and consideration for substitution of drug (amlodipine) with other antihypertensive drug, for which the physician agreed and substituted amlodipine with combination of  $\beta$ -blockers and ACE inhibitors.

Patient was asked to rinse with 10 ml of 0.2% chlorhexidine mouthwash twice daily for one minute and to maintain strict oral hygiene. She was asked to report back after two weeks. The tissue in the mean time had become fibrous [Table/Fig-3] and inflammation had subsided.

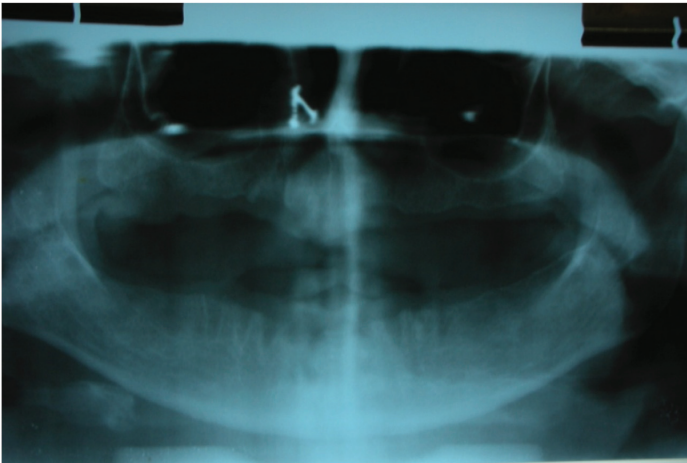
Gingivectomy was performed under local anaesthesia with respect to mandibular left quadrant [Table/Fig-4] to remove the fibrous tissue surgically. Patient was asked to report back after one week for check up. Patient was advised to use topical anaesthetic and analgesic gel for local application over the surgically treated area 4-5 times per day especially before meals. She was also prescribed anti-inflammatory analgesic drug for management of postoperative pain for five days. Patient reported pain and discomfort in the surgically

treated area, as the treated area was open and raw wound surface. Hence, no treatment was given on that visit but patient was asked to come for check-up once every week and to maintain meticulous oral hygiene. It was also observed that tissue was showing gradual regression in size on its own at each visit. Hence, no further surgical treatment was planned but patient was asked to maintain strict oral hygiene using 0.2% chlorhexidine mouthwash .Patient was observed weekly once for a period of next two months.

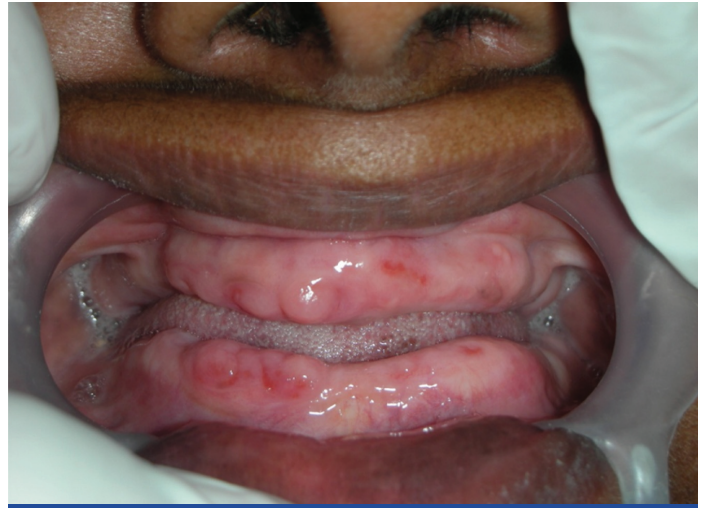On examination after two months [Table/Fig-5], the overgrowth had subsided almost completely except for minor fibrous nodules remaining in mandibular and maxillary right anterior edentulous region. Hence patient was referred to Department of Prosthodontics for complete denture rehabilitation.



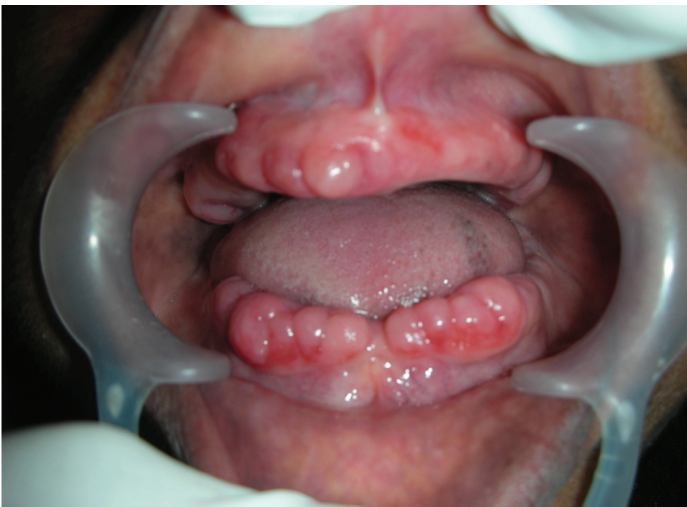**[Table/Fig-1]:** First visit of patient with DIGO



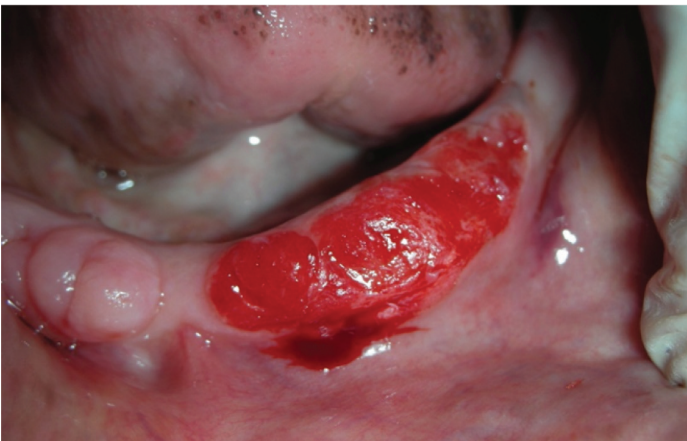[Table/Fig-2]: Orthopantomograph



[Table/Fig-5]: Two months postoperation



[Table/Fig-3]: Two weeks after initial visit showing fibrotic overgrowth



[Table/Fig-4]: Surgical excision of overgrown tissue

### Biopsy Report

The tissues excised were duly sent for histo-pathological assessment which revealed the presence of parakeratinized epithelium with acanthosis and elongated rete-pegs, mixture of dense and loose fibrous connective tissue with inflammatory cell infiltration in connective tissue, few scattered giant cells and capillaries indicating a superimposed inflammation. This confirmed our diagnosis of drug associated gingival enlargement.

### DISCUSSION

Currently, more than 20 drugs have been identified as possible causative agents for gingival overgrowth, including oral contraceptives [1]. However, gingival overgrowth is well documented unwanted effect

associated with three major classes of drugs viz, anticonvulsants, calcium channel blockers, and immunosuppressants. Although the pharmacological effect of each of these drugs is different and directed towards various primary target tissues, all of them seem to act similarly on a secondary target tissue, i.e. gingival tissue.

Here, we report a case of amlodipine-induced gingival enlargement in a 50-year-old hypertensive patient taking amlodipine at a dose of 10mg twice daily.

The incidence of gingival enlargement with amlodipine was reported to be much lesser than nifedipine [1], however; recently large numbers of cases are being highlighted. Among calcium channel blockers, nifedipine, a first generation calcium channel blocker causes gingival overgrowth in about 20% of patients, whereas the incidence of amlodipine-, a third generation calcium channel blocker, induced gingival hyperplasia is very limited. The prevalence of amlodipine-induced gingival hypertrophy has been shown to be between 1.7% and 3.3% [2,3].

Gingival overgrowth, regardless of its aetiology, may be problematic and contribute to an increased risk for dental decay and periodontal disease. It also produces aesthetic changes and clinical symptoms including pain, tenderness, bleeding, speech disturbances, abnormal tooth movement, and dental occlusion problems [1].

The changes in gingival contour seen in DIGO may at least be exacerbated by plaque induced inflammation leading to edematous and hyperemic gingiva. When this occurs, plaque removal is made more difficult by distorted contour of gingiva, perpetuating the cycle. In the present case, these inflammatory gingival changes may have enhanced periodontal disease progression, leading to tooth mortality.

The findings of present case suggest that gingival overgrowth can occur even in edentulous ridges that could be due to persistence of gingival overgrowth, which may not resolve completely following tooth extraction or occurs because of incorporation of specific subpopulation of gingival fibroblasts in alveolar ridge mucosa [4].

Primary aim of non-surgical approach is to reduce the inflammatory component in gingival tissue & thereby avoid the need for surgery. Controlling the inflammatory component of DIGO is important in itself and it also aids in determining if surgical intervention is required and additionally allows for a less hemorrhagic field in surgical intervention.

Alike present case, it is worth asking physician for substitution of the drug in question (Amlodipine in present case), but it should be remembered that these drugs are being given for debilitating systemic condition which are difficult to control otherwise and may present challenge to patient's life, so it should be best left for physician's decision to substitute or not to substitute the drug.

A 3-month interval for periodontal maintenance therapy has been recommended for patients taking drugs associated with gingival enlargement [2]. A programme of intense oral hygiene helped to reduce the gingival inflammation in the present case. Chlorhexidine (0.12%) mouthrinse has been reported to recurrent cyclosporin induced overgrowth following gingivectomy [5]. In the present case also patient was kept on Chlorhexidine mouthwash for maintaining oral hygiene.

The surgical treatment of DIGO was advocated by Thompson and Gillespie 1941. Factors which governs the type of surgical technique either gingivectomy or periodontal flap surgical procedure are extent and grade of gingival enlargement, amount of keratinised tissue present, location of base of pockets in relation to mucogingival junction, presence of bony defects and esthetic considerations [6].

With surgical approach the increased bulk of tissue can be removed. Gingivectomy (Scalpel) procedure is an effective form of treatment when indicated as the procedure is technically simple, accurate and causes less damage to adjacent tissue [7,8]. Perioperative hemorrhage is the main disadvantage of Scalpel excision. An alternative to blade gingivectomy is the use of argon, carbon dioxide or diode lasers. In the present case, surgical excision of overgrown tissue was done in relation to third quadrant but patient experienced pain and discomfort hence it was decided that no further surgical treatment to be done and patient was asked to maintain meticulous oral hygiene.

While non-surgical therapy typically requires between 2 and 3 months for the effects to be clinically apparent, a surgical approach allows for more rapid results, with immediate patient satisfaction [9]. As evident from the clinical picture [Table/Fig-5], postoperative area (i.e. third quadrant), after two months, shows comparatively better results when compared to other areas with previously enlarged soft tissue over edentulous area.

The recurrence rate of severe gingival enlargement in CsA- or nifedipine-treated patients after surgical periodontal therapy was found to be about 40% within 18 months after active treatment [10]. There may be recurrence of gingival hyperplasia if medication is continued and also persistence of other risk factors [11].

Clinically, the enlargement is usually seen 1-3 months following the initiation of the drug in question [1]. The present case is interesting as patient was taking amlodipine 10 mg twice daily from last five years but the enlargement was present from last one year only. Hence, the possibility of amlodipine induced gingival overgrowth should be considered for a late presentation too.

No further treatment was required as the overgrowth had almost subsided. This may be attributed to substitution of amlodipine with combination of  $\beta$ -blockers and ACE inhibitors and meticulous oral hygiene maintenance. Hence, the patient was referred to Department of Prosthodontics for complete denture rehabilitation.

## CONCLUSION

Gingival Overgrowth (GO) is frequently observed adverse effect associated with the use of three major classes of drugs namely anticonvulsants, calcium channel blockers, and immunosuppressants. The complexities of the events that contribute to gingival overgrowth have yet to be fully realized. When all the evidence are considered, there appears to be three significant factors which are important for the expression of these gingival changes, notably drug variables, plaque induced inflammatory changes in gingival tissue and genetic factors which determine the heterogeneity of the fibroblast. Dental Surgeons need to discuss this issue with their medical colleagues and to practice care while prescribing the drugs associated with gingival overgrowth.

## REFERENCES

- [1] Dongari-Baqtzoglou A, Research, Science and therapy committee, American Academy of Periodontology, Academy Report. Drug-Associated Gingival Enlargement. *J Periodontol.* 2004; 75:1424-31.
- [2] Ellis JS, Seymour RA, Steele JG, Robertson P, Butler TJ, Thomason JM. Prevalence of gingival overgrowth induced by calcium channel blockers: a community based study. *J Periodontol.* 1999;70(1):63-67.
- [3] Jorgensen MG. Prevalence of amlodipine-related gingival hyperplasia. *J Periodontol.* 1997;68:676-78.
- [4] Dhingra K, Prakash S. Gingival overgrowth in partially edentulous ridges in an elderly female patient with epilepsy: a case report. *Gerodontology.* 2012;29(2):e1201-06.
- [5] Ciancio S, Bartz N, Lauciello F. Cyclosporine- induced gingival hyperplasia and chlorhexidine: a Case report. *Int J Periodontics Restorative Dent.* 1991; 11:241-45.
- [6] PM Camargo and F. A. Carranza, "Treatment of Gingival Enlargement" In Newman MG, Takei HH, Carranza, FA.: Carranza's Clinical Periodontology, pp. 754-761, Philadelphia: W.B. Saunders Company, 9<sup>th</sup> Edition, 2003.
- [7] FA Carranza, "The Gingivectomy Technique". In Newman MG, Takei HH, Carranza FA. : Carranza's Clinical Periodontology, pp. 749-753, Philadelphia: W.B. Saunders Company, 9<sup>th</sup> Edition, 2003.
- [8] N Manivannan, RS Ahathya, PC Rajaram. Scalpel versus electrosurgery: Comparison of gingival perfusion status using ultrasound Doppler flowmetry. *J Pharm Bioallied Sci.* 2013; 5(Suppl 2): S154-S59.
- [9] Moffitt M, Bencivenni D, Cohen R. Treatment modalities for drug induced gingival enlargement. *J Dent Hyg.* 2012;86:272-75.
- [10] Ilgenli T, Atilla G, Baylas H. Effectiveness of periodontal therapy in patients with drug-induced gingival overgrowth. Long-term results. *J Periodontol.* 1999;70: 967- 72.
- [11] Mavrogiannis M, Ellis JS, Thomason JM, Seymour RA. The management of drug-induced gingival overgrowth. *J Clin Periodontol.* 2006;33:434-39.

### PARTICULARS OF CONTRIBUTORS:

1. Assistant Professor, Department of Periodontics, RUHS College of Dental Sciences Jaipur, India.
2. Assistant Professor, Department of Conservativ Dentistry & Endodontics, RUHS College of Dental Sciences, Jaipur, India.
3. Senior Professor and Head, Department of Dentistry, S. P. Medical College & Hospital, Bikaner, India.
4. Senior Lecturer, Department of Oral Pathology, Rajasthan Dental College & Hospital, Jaipur, India.
5. Professor, Department of Pathology, M.G. Medical College & Hospital, Jaipur, India.

### NAME, ADDRESS, E-MAIL ID OF THE CORRESPONDING AUTHOR:

Dr. Setu Mathur,  
11, Shanti Path, Gopalpura Gaon, Near Triveni Crossing, Gopalpura bypass Road, Jaipur (Rajasthan)-302018, India.  
E-mail: drsetumathur@gmail.com

FINANCIAL OR OTHER COMPETING INTERESTS: None.

Date of Submission: **Sep 25, 2014**

Date of Peer Review: **Nov 22, 2014**

Date of Acceptance: **Nov 25, 2014**

Date of Publishing: **Jan 01, 2015**