

# Endodontic Management of Maxillary First Molar with Type I Canal Configuration— A Rare Case Report

NIRANJAN DESAI<sup>1</sup>, GANESH RANGANATH JADHAV<sup>2</sup>, SRINIDHI SURYA RAGHAVENDRA<sup>3</sup>, PRIYA MITTAL<sup>4</sup>, GURURAJ PATIL<sup>5</sup>

## ABSTRACT

Thorough knowledge about the root canal variations is essential for the predictable endodontic treatment outcome. The root and root canal anatomy of maxillary first molar varies greatly. A Pub-med literature search about single rooted single canalled maxillary first molar was done to know its details such as incidence, diagnostic method used, age, sex and ethnic background of patient. This article presented report of a single rooted single canalled maxillary first molar in a 27-year-old healthy Asian female.

**Keywords:** Asian population, Hertwig's epithelial root sheath, Maxillary molar

## CASE REPORT

A 27-year-old healthy Asian female referred to the endodontic clinic by a general dentist. The patient presented to her dentist with a continuous severe pain in the upper left posterior region seven days ago. The dentist initiated the root canal treatment in the left maxillary first molar (tooth #26), but couldn't understand the internal coronal and radicular tooth morphology. Hence the case was opted for the referral. Clinical examination revealed a temporary restoration in the left maxillary first molar. Tooth was tender to percussion without any evidence of swelling or sinus tract. Careful pre-operative radiographic examination revealed maxillary first molar with single root [Table/Fig-1a]. The patient was explained regarding unusual corono-radicular morphology and its treatment plan. Written informed consent was taken. Under rubber dam isolation, tooth #26 was re-accessed. Dentinal map clearly indicated the presence of only one root canal orifice [Table/Fig-1b]. Working length determination was done using apex locator and working length radiograph [Table/Fig-1c]. After thorough chemo-mechanical preparation, obturation was completed by sectional gutta-percha and back-filling with thermoplasticized gutta-percha technique [Table/Fig-1d]. Post-obturation restoration with silver amalgam was completed in the same appointment [Table/Fig-1e].

## DISCUSSION

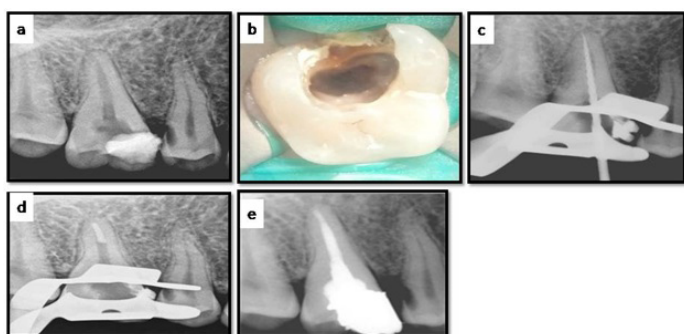
Root and root canal morphological variations in multi-rooted teeth are a treatment challenge for accurate diagnosis and successful endodontic treatment [1]. Complete knowledge of the root canal anatomy is obligatory because non-treatment of any of the unexplored canals can lead to treatment failure. Commonly reported

morphologic variations are the presence of additional roots [2], additional root canals, fused roots or "C"- shaped canals. However, the most common morphology of maxillary first molar shows three roots and four canals. With increasing reports of aberrant canal morphology, the clinician should be aware of the varied root and root canal anatomy [3]. The occurrence of a single root with single canal in the permanent maxillary first molar is very rare [4]. Chhabra et al., reported endodontic management of type I maxillary first molar diagnosed using spiral computed tomography [4].

This article presented endodontic management of an unusual case of maxillary first molar with Vertucci's type I canal configuration. The root and root canal anatomy of maxillary first molar varies greatly. Thorough knowledge about the root canal variations is essential for the predictable endodontic treatment outcome. In single rooted maxillary molars, roots can be termed as pyramidal, fused or conical depending upon its morphological expression. In the pyramidal type, roots are completely fused with a solitary enlarged root canal [5]. The failure of invagination of Hertwig's epithelial root sheath is responsible for this anomaly [6].

Intraoral periapical radiographs taken at varying horizontal angulations are essential prior to any endodontic intervention. However, radiographs have certain limitations like it is a two-dimensional image of a three-dimensional object and there are possibilities of superimposition of multiple anatomic structures. Hence, recently introduced three-dimensional imaging tools like spiral computed tomography, cone beam computed tomography can be used due to its accuracy and reliability. In the presented case; however, cone beam computed tomography was not used because intraoral radiograph was clearly indicative of exact tooth anatomy. It also avoided the extra radiation exposure and extra cost to the patient.

Asian population shows higher prevalence for single rooted maxillary molars. Kim Y et al., reported the incidence of such single rooted maxillary molars in Korean population to be 0.25% [7]. It is inherited as an autosomal dominant condition [8]. Hence, if multiple single rooted maxillary molars are present in the same patient, the siblings of the patient should be checked for the same defect [8]. In the presented case, all maxillary molars had normal anatomy (three roots) and hence any possibility of presence of such defect in siblings was eliminated. In single rooted maxillary molars the root surface area for periodontal attachment is reduced. Such teeth are at higher risk for periodontal disease progression and it can lose its stability easily [5]. Hence, during endodontic intervention, periodontal health is given due consideration.



**[Table/Fig-1]:** Pre-operative radiographic examination revealed maxillary first molar with single root (a). Dentinal map clearly indicated the presence of only one root canal orifice (b), working length radiograph was taken(c). Obturation was completed by sectional gutta-percha (d) and back-filling with thermoplasticized gutta-percha technique. Post-obturation restoration with silver amalgam was completed in the same appointment (e)

## CONCLUSION

This case report presented an endodontic management of an unusual case of a maxillary first molar with a single root and a single canal. It is not always necessary to use advance three dimensional imaging techniques like CBCT to ascertain root canal morphology and it ultimately avoids the radiation exposure of the patient.

## REFERENCES

- [1] Al-Qudah AA, Awawdeh LA. Root canal morphology of mandibular incisors in a Jordanian population. *Int Endod J.* 2006;39:873-77.
- [2] Shah DY, Jadhav GR. Endodontic management of a maxillary molar with formation supradentals: A case report. *J Conserv Dent.* 2014;17:481-82.
- [3] Jadhav GR. Endodontic management of a two rooted, three canaled mandibular canine with a fractured instrument. *J Conserv Dent.* 2014;17:192-95.
- [4] Chhabra N, Singbal KP, Chhabra TM. Type I canal configuration in a single rooted maxillary first molar diagnosed with an aid of cone beam computed tomographic technique: A rare case report. *J Conserv Dent.* 2013;16:385.
- [5] Metgud S, Metgud R, Rani K. Management of a patient with a taurodont, single-rooted molars associated with multiple dental anomalies: A spiral computerized tomography evaluation. *Oral Surg Oral Med Oral Pathol Oral Radiol Endod.* 2009;108:e81-86.
- [6] Ten Cate RT. Development of the tooth and its supporting tissues. *Oral histology.* 5<sup>th</sup> ed. Mosby; 1998.78-79.
- [7] Kim Y, DDS, MSD, Lee SJ, Woo J Morphology of Maxillary First and Second Molars Analyzed by Cone-Beam Computed Tomography in a Korean Population: Variations in the Number of Roots and Canals and the Incidence of Fusion. *J Endod.* 2012;38:1063–68.
- [8] Holan G, Chosack A. Single-rooted molars in the primary and permanent dentition in two siblings: case report. *Pediatr Dent.* 1991;13:367-69.

### PARTICULARS OF CONTRIBUTORS:

1. Reader, Department of Conservative Dentistry and Endodontics, Sinhgad Dental College and Hospital, Pune, India.
2. Lecturer, Department of Conservative Dentistry and Endodontics, Sinhgad Dental College and Hospital, Pune, India.
3. Professor and Head, Department of Conservative Dentistry and Endodontics, Sinhgad Dental College and Hospital, Pune, India.
4. Senior Resident, Department of Conservative Dentistry and Endodontics, CDER, New Delhi, India.
5. Associate Professor, Department Oral Pathology, Priyaram Dental College, Kanur, Kerala, India.

### NAME, ADDRESS, E-MAIL ID OF THE CORRESPONDING AUTHOR:

Dr. Ganesh Ranganath Jadhav,  
Lecturer, Department of Conservative Dentistry and Endodontics, Sinhgad Dental College and Hospital, Pune, India.  
E-mail : drganesh2009.aiims@gmail.com

Date of Submission: **Dec 22, 2014**

Date of Peer Review: **Feb 24, 2015**

Date of Acceptance: **Feb 26, 2015**

Date of Publishing: **Apr 01, 2015**

FINANCIAL OR OTHER COMPETING INTERESTS: None.