

A Rare Case Report of Neurofibromatosis I in HIV Positive Individual

ASHISH M. WARHEKAR¹, PANJAB V. WANJARI², ARATI CHAUDHARY³, DIPTI SINGH HADA⁴, RADHIKA GUPTA⁵

ABSTRACT

Neurofibroma is an uncommon benign tumour of neural tissue origin rarely presenting in the mouth and jaws and thereby attracting the attention of oral physicians. A 22-year-old male patient reported with a complaint of swelling in left middle one third region of face since 8-10 y which was slowly progressive in size. He had history of multiple dark brown pigmentation on skin associated with progressively enlarging multiple small nodular growths over the body and single firm nodular growth in left side of maxilla intraorally. He had history of tuberculosis at the age of one year which was treated completely and since last 2-3 y he was suffering from recurrent episodes of sore throat, fever, diarrhea, abdominal pain with vomiting and excessive weight loss. Radiographic findings showed irregular osteolytic lesions involving ramus and angle of mandible, zygomatic bone and posterior part of maxilla with displacement of teeth with abnormal soft tissue enhancement observed by advance imaging. On serological investigation he was HIV positive and histopathologically, diagnosed with Neurofibromatosis-1.

Oral manifestations of neurofibromatosis have been reported in only 4% to 7% of affected persons. This article presents a rarest of rare case report of neurofibromatosis-I in HIV positive individual also involving maxilla, mandible as well as zygomatic arch.

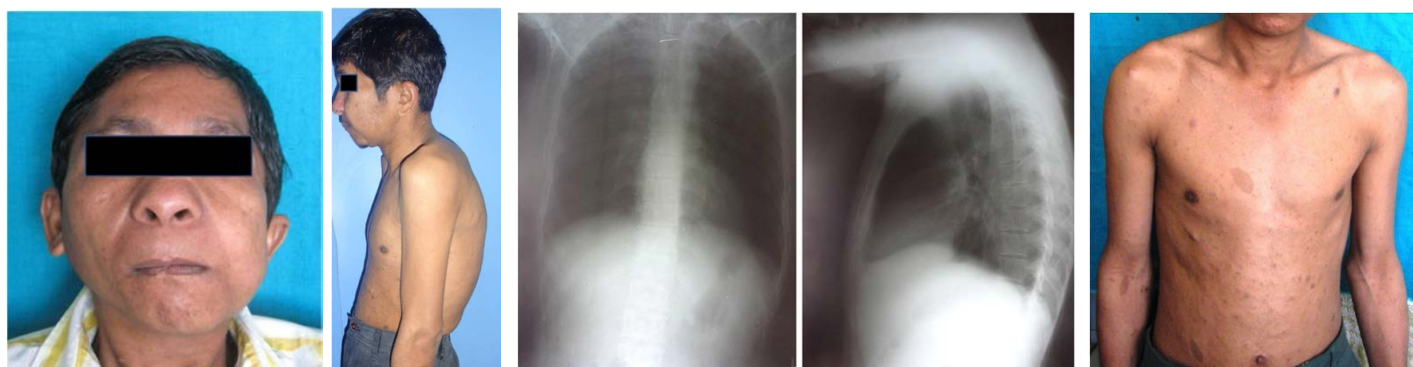Keywords: AIDS, Neurofibroma, Panoramic radiograph

CASE REPORT

A 22-year-old young male patient reported to Department of Oral Medicine & Maxillofacial Radiology, Modern Dental College & Research Centre, Indore, India with a chief complaint of swelling in left middle one third region of face since 8-10 y and pain since 8-10 days [Table/Fig-1]. The swelling was initially small in size and had gradually increased to the present size. Associated with this he had hearing defect with left ear, slurred speech & difficulty in swallowing since 8-10 y. His medical history revealed that he had multiple dark brown pigmentations on skin associated with progressively enlarging multiple small nodular growths which initially were less in number but as age advanced the number and size of nodules increased. He suffered from tuberculosis at the age of 1 year which was treated by antitubercular drugs. But, since last 2-3 y, he experienced anorexia, lethargy, excessive weight loss associated with history of recurrent episodes of sore throat, fever, diarrhoea and abdominal pain with emesis; for the same he took only symptomatic treatment. He never received blood transfusion. His family history revealed that he was unmarried, residing with his mother and siblings. Father was separated from the family. None of the family members suffered from any major illnesses. On general physical examination, he was short stature of 4 feet 8 inches with weight of 46 kg, mild kyphoscoliosis

was observed but radiographically spine was normal [Table/Fig-2,3], bilaterally asymmetrical face, left ear placed more inferiorly as compared to right side, multiple dark brown café au lait spots were seen on thorax, abdomen, bicep, extensor surface of forearm and lower back portion. The greatest measured about 5 cm in diameter and asymptomatic multiple subcutaneous nodules of size 1-2 cm, mostly on the trunk lower back region and forearm [Table/Fig-4]. Submandibular, abdominal and inguinal lymphadenopathy and hepatomegaly was present.

Extraoral examination showed a single diffuse, roughly oval shaped swelling on middle 1/3rd of the face approximately 5 x 4.5 cm in size extending anteriorposteriorly from left nasolabial fold to preauricular region and superiorinferiorly from left malar region to body of mandible, which was non tender, firm in consistency, non pulsatile with no signs of hyperesthesia / paresthesia. On opening of mouth mandible deviated towards left side with reduced translation of condyle. On intra-oral examination, a single firm nodular growth was observed in upper left back teeth region in relation with 24, 25, 26 of approximately 4 x 3 cm which was firm in consistency, mildly tender and did not bleed on palpation. Obliteration of buccal vestibule was noticed from premolar to retromolar region [Table/Fig-5]. In left mandibular region missing



[Table/Fig-1]: Swelling and asymmetry in left side of face **[Table/Fig-2]:** Kyphosis **[Table/Fig-3]:** Radiographs of spine (AP and lateral view)
[Table/Fig-4]: Multiple subcutaneous nodules & Café au lait spots on thorax, abdomen, bicep & extensor surface of forearm

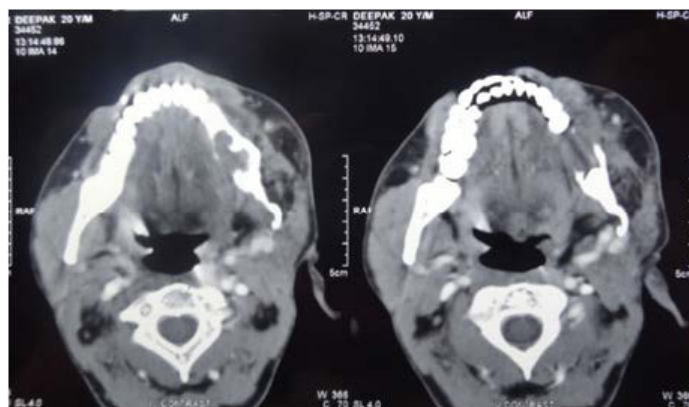
36 & 37 was observed with swelling on anterior border of ramus of mandible. As the patient's history and clinical findings correlating with clinical diagnostic criteria of NF-I; a provisional diagnosis of neurofibromatosis- type I and differential diagnosis of hemifacial hypertrophy and fibro osseous lesion was made. Patient was advised for HIV screening, hematological, advance radiological and histopathological investigations.

Panoramic radiograph showed deformed and elongated condylar process/coronoid process, along with deepening of mandibular notch, missing gonial angle and hypoplasia of the ascending ramus with perforation defects. Irregular osteolytic lesions was seen involving left ascending ramus, angle of mandible, zygomatic bone and posterior part of maxilla with displacement of left maxillary and mandibular posterior teeth. Inferior alveolar nerve canal was indistinct and not traceable on the left side [Table/Fig-6].

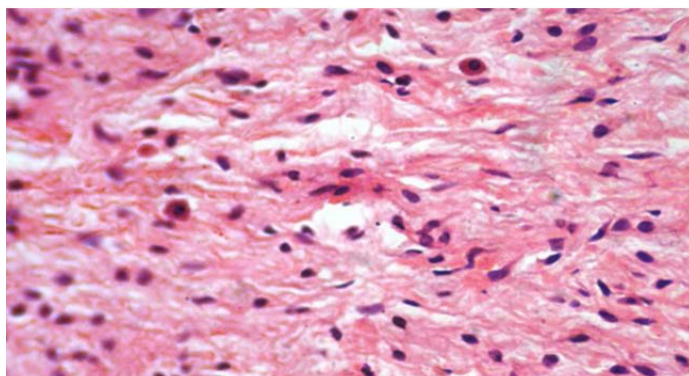
CT scan showed abnormal soft tissue with ill defined margins & erosion of inferior & posterolateral walls of the hypoplastic left maxillary sinus with soft tissue extending into the retromaxillary space [Table/Fig-7]. Eroded posterior maxilla left side surrounded by abnormal soft tissue [Table/Fig-8]. Left body, angle, ramus, coronoid process and condylar head of mandible showed erosion with soft tissue encasing. The masticatory muscles were atrophied along with thinning of the left mandibular ramus [Table/Fig-9].

The HIV status was confirmed with ELISA. Incisional biopsy was done which showed parakeratinized stratified squamous epithelium of variable thickness with nerve fibres bundles, muscle fibres and

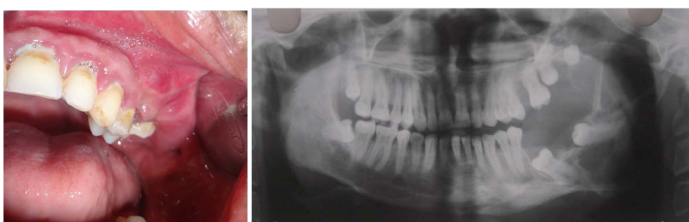adipose tissue which confirmed the diagnosis [Table/Fig-10]. Final diagnosis of neurofibromatosis-I with AIDS was made. Patient was referred for counseling of HIV to Integrated Counseling and Testing Center (ICTC) and is presently under Anti Retroviral Therapy (ART), Tab. Zidolam-N (Zidovudine 300 mg, Lamivudine 150 mg, Nevirapine 200 mg) two times daily.



[Table/Fig-9]: CT scan images of mandible reveal erosion of the body, angle and ramus of mandible with abnormal soft tissue extensions. Atrophied masticatory muscles seen with thinning of the left mandibular ramus

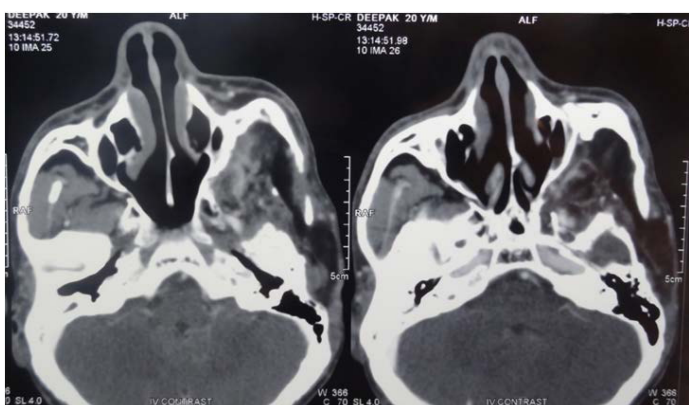


[Table/Fig-10]: Photomicrograph showing parakeratinized stratified squamous epithelium of variable thickness with nerve fibres bundle, muscle fibres and adipose tissue

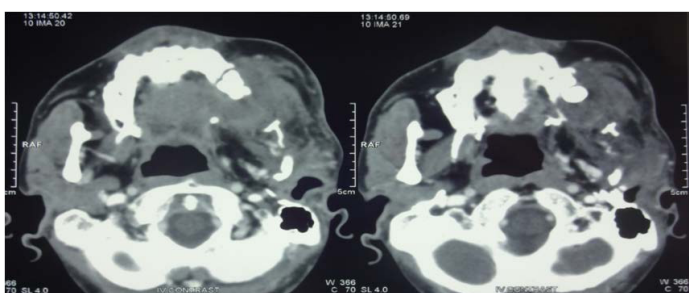


[Table/Fig-5]: Post biopsy intraoral photograph showing extension of lesion from left premolar to retromolar region in buccal vestibule

[Table/Fig-6]: Panoramic reveals irregular large radiolucent osteolytic area involving left mandible and maxilla with displacement of teeth



[Table/Fig-7]: CT scan images of zygomatic region reveals abnormal soft tissue extensions with ill defined margins & erosion of left retromaxillary space, inferior & posterolateral walls of the maxillary sinus and zygomatic bone and arch



[Table/Fig-8]: CT scan images of maxilla reveal abnormal soft tissue extensions into eroded left posterior maxilla

DISCUSSION

Neurofibromatosis (NF) is not a single entity, but a group of heterogeneous multisystem neurocutaneous disorder involving both neuroectodermal and mesenchymal derivatives [1,2]. It is one of the most common hereditary disease occurring in 1 of every 3000 births [3,4]. VM Riccardi, recognizes at least seven types of NF [5], but of many proposed classifications of the disease, two distinct forms are generally accepted namely, a peripheral form known as NF-I, and a central form known as NF-II [6].

Many HIV-associated tumours affect sites that are in contact with the outside environment, including the skin. The increased density of immune cells and coincident elevated concentration of HIV-1 at these sites could lead to local compromised immune defences and the subsequent development of neoplasms. Although HIV-1 is not a direct agent but it may contribute to development of neoplasm though several mechanisms like predisposition to infection by oncogenic viruses, impaired immune surveillance, dysregulation of cytokine pathways and growth factor production, chronic B cell stimulation with imbalance between cellular proliferation and differentiation. Hence, there is possibility of increased risk for neoplasm with more profound natural course of diseases in individuals with concurrent HIV-1 infection and NF-I [7]. We report this case to draw attention to rarely reported occurrence of HIV infection in a patient with NF-I which showed involvement of maxilla, mandible as well as zygomatic arch.

Though proportion of people with NF-I gene penetration showed clinical presentation of disorder close to 100% but mutation rate

is so high that half of newly diagnosed cases represent with new mutations. The gene has been isolated to the proximal long arm of chromosome 17 (17, 11.2) [8,9].

The major defining features of the peripheral form (NF-I) include neurofibromas, cutaneous café-au lait macules and lisch nodules (pigmented iris hamartomas). The café au lait spots and lisch nodules usually develop early in childhood, where as the cutaneous neurofibromas begin to appear the onset of puberty and increase in number and size throughout life as seen in our case.

In addition to the diagnostic criteria laid down by National Institutes of Health Consensus Development Conference (NIHCDC), 1987 on neurofibromatosis; skeletal findings which include scoliosis-like spinal curvature, short stature, tibial pseudarthrosis and dysplastic lesions of the skeleton was also considered [10]. In our patient, clinically mild kyphoscoliosis is observed but radiographically spine appears normal.

These lesions are generally assumed to represent abnormal development of mesodermal elements and hence are considered primary osseous dysplasia. Direct erosion of bone is less commonly observed in neurofibroma [10], as erosion or extensive osteolytic lesion seen in the present case.

Oral manifestations of neurofibromatosis have been reported in only 4% to 7% of affected persons. Although all oral hard and soft tissues can be affected in neurofibromatosis, fungi form papillae of tongue is most common site [11,12]. However, in the indexed case the tongue was unaffected. Oral lesions occur as discrete, pedunculated or sessile non ulcerated slow growing painless nodule and usually have same color as the normal mucosa. Common oral sites include buccal mucosa, labial mucosa, palate, alveolar mucosa, vestibule and tongue. Intraoral lesions are usually painless but pain may occur due to nerve compression as seen in this case also [13].

According to HM Worth, the long bones are affected much more commonly than jaws [14]. About 30-70% of NF-I patients have associated osseous changes with the jaws involved very infrequently [15]. In the jaws both maxilla and mandible have been the sites of enlargement together and more commonly with only one jaw affected [14]. But in the present case there was involvement of maxilla, mandible as well as zygomatic arch making our case rarest of rare entity.

Skeletal lesions specific to the jaws include enlarged mandibular foramen and canals, branched mandibular canal, widening of the coronoid notch, deformity of the condylar head, lengthening of the condyle neck, irregularity of the inferior mandibular cortex, intrabony cyst like lesion, hypoplasia and lateral bowing of ramus are observed [12]. The pattern of jaw malformation can be caused by tumour invasion or destruction [15], as seen in the present case also.

Also reported on computed tomography (CT) analysis, is the presence of an increased amount of fat like soft tissue immediately adjacent to affected ramus. Neurofibromas are typically of homogenous low attenuation than compared with adjacent muscle on CT images [12,16], as reported in present case.

The typical MR images of neurofibroma shows homogenous iso-intensity or mild hyperintensities compared with muscle on T1 weighted images, homogenous enhancement of the solid component of the tumour after the contrast medium administration and heterogeneous high signal intensity on T2 weighted images [16].

Total or partial resection of neurofibromatosis lesions is the treatment of choice to solve esthetic or functional problems. Total resection with 1 cm margins whenever feasible is treatment of choice for accessible and small tumours. Radiation therapy or chemotherapy is not recommended for treatment of neurofibroma [12].

In a case of neurofibromatosis with a rapidly growing mass, the possibility of a malignant transformation should be considered. The risk of malignant transformation is about 3-14% with a latency period of about 10-20 y [17].

CONCLUSION

As in the indexed case, the patient was HIV positive with multisystemic involvements secondary to neurofibromatosis and was showing progressive clinical manifestation with age. Hence, it is important to keep such patients under observation for any new manifestations, and to prevent any further complications.

REFERENCES

- [1] Cawson RA, Binnie WH, Speight PM, Barrett AW, Wright JM. Lucas' *Pathology of tumours of the oral tissues*. 5th ed. London: Churchill Livingstone; 1998:280-81.
- [2] Thammaiah S, Manjunath M, Rao K, Uma DH. Intraoral plexiform neurofibroma involving the maxilla – pathognomonic of neurofibromatosis type I. *J Pediatr Neurosci*. 2011;6(1):65-68.
- [3] Neville BW, Hann J, Narang R, Garen P. Oral neurofibrosarcoma associated with neurofibromatosis type I. *Oral Surg Oral Med Oral Pathol*. 1991;72(4):456-61.
- [4] Yazdizadeh M, Tapia JL, Baharvand M, Radfar L. A case of neurofibromatosis-Noonan syndrome with a central giant cell granuloma. *Oral Surg Oral Med Oral Pathol Oral Radiol Endod*. 2004;98(3):316-20.
- [5] Riccardi VM. Neurofibromatosis update. *Neurofibromatosis*. 1989;2(5-6):284-91.
- [6] Behbehani EM, Al-Ramzi AH, Mohamed EA. Oral manifestations of neurofibromatosis: case report. *Dental News*. 1997;4(3):17-21.
- [7] Isa SE, Silas A, Daniyam C, et al. An HIV-1 Infected Patient with Neurofibromatosis Type 1: A Case Report. *The Nigerian Health Journal*. 2012;12:52-54.
- [8] Dimitrova V, Yordanova I, Pavlova V, Valtchev V, Gospodinov D, Parashkevova B, et al. A case of neurofibromatosis type 1. *J IMAB*. 2008;14(1):63-67.
- [9] García de Marcos JA, Dean Ferrer A, Alamillos Granados F, Ruiz Masera JJ, García de Marcos MJ, Vidal Jiménez A, et al. Gingival neurofibroma in a neurofibromatosis type 1 patient. *Med Oral Patol Oral Cir Bucal*. 2007;12(4):E287-91.
- [10] Neurofibromatosis. *NIH Consens Statement Online*. 1987;6(12):1-19.
- [11] Shapiro SD, Abramovitch K, Van Dis ML, Skoczylas LJ, Langlais RP, Jorgenson RJ, et al. Neurofibromatosis: oral and radiographic manifestations. *Oral Surg Oral Med Oral Pathol*. 1984;58(4):493-98.
- [12] Edwards PC, Fantasia JE, Saini T, Rosenberg TJ, Sachs SA, Ruggiero S. Clinically aggressive central giant cell granulomas in two patients with neurofibromatosis 1. *Oral Surg Oral Med Oral Pathol Oral Radiol Endod*. 2006;102(6):765-72.
- [13] Bhargava S, Motwani MB, Patni VM. Recurring neurofibroma involving orofacial structures-Report of a rare case. *IJDCR*. 2011;1(3):68-74.
- [14] Worth HM. Principles and practice of oral radiologic interpretation. Year Book Medical Publisher. Chicago. 1963; 356,612,627-29.
- [15] Sun ZJ, Zhao YF, Wang SP, He SG. Giant facial haematoma in neurofibromatosis type 1. *Dentomaxillofac Radiol*. 2008;37(1):52-57.
- [16] Hisatomi M, Asaumi J, Konouchi H, Yanagi Y, Kishi K. Bone deformity showing a deep coronoid notch of the mandible in a patient with neurofibromatosis type 1. *Dentomaxillofac Radiol*. 2005;34(6):380-83.
- [17] Korf BR. Malignancy in neurofibromatosis type 1. *Oncologist*. 2000;5:477-85.

PARTICULARS OF CONTRIBUTORS:

1. Reader, Department of Oral Medicine and Maxillofacial Radiology, Modern Dental College & Research Centre, Indore, Madhya Pradesh, India.
2. Professor & Head, Department of Oral Medicine and Maxillofacial Radiology, Modern Dental College & Research Centre, Indore, Madhya Pradesh, India.
3. Professor, Department of Oral Medicine and Maxillofacial Radiology, Modern Dental College & Research Centre, Indore, Madhya Pradesh, India.
4. Senior Lecturer, Department of Oral Medicine and Maxillofacial Radiology, Sardar Patel Post Graduate Institute of Dental and Medical Sciences, Lucknow, Uttar Pradesh, India.
5. PG Student, Department of Oral Medicine and Maxillofacial Radiology, Modern Dental College & Research Centre, Indore, Madhya Pradesh, India.

NAME, ADDRESS, E-MAIL ID OF THE CORRESPONDING AUTHOR:

Dr. Ashish M. Warhekar,
Reader, Department of Oral Medicine and Maxillofacial Radiology, Modern Dental College & Research Centre,
Gandhi Nagar, Indore, Madhya Pradesh-453112, India.
E-mail: drashishwarhekar@gmail.com; drashishwarhekar@yahoo.co.in

FINANCIAL OR OTHER COMPETING INTERESTS: None.

Date of Submission: **Nov 14, 2014**
Date of Peer Review: **Jan 27, 2015**
Date of Acceptance: **Mar 16, 2015**
Date of Publishing: **Apr 01, 2015**