

## JOURNAL OF CLINICAL AND DIAGNOSTIC RESEARCH

**How to cite this article:**

SIDIROPOULOU Z , SOUSA A C, GAMEIRO P, MADUREIRA R. Spontaneous Abdominal Wall Endometriosis, A Case Report And A Literature Review. .Journal of Clinical and Diagnostic Research [serial online] 2009 December [cited: 2009 December 7]; 3:1931-1934.

Available from

[http://www.jcdr.net/back\\_issues.asp?issn=0973-709x&year=2009&month=December &volume=3&issue=6&page=1931-1934 &id=478](http://www.jcdr.net/back_issues.asp?issn=0973-709x&year=2009&month=December &volume=3&issue=6&page=1931-1934 &id=478)

## CASE REPORT

# Spontaneous Abdominal Wall Endometriosis, A Case Report And A Literature Review

SIDIROPOULOU Z \*, SOUSA A C \*\*, GAMEIRO P\*\*\*, MADUREIRA R\*\*\*\*

### ABSTRACT

Endometriosis is a well defined but not such well understood benign gynaecological condition that consists on the presence of endometrial gland and stroma outside the uterus and that affects 10- 15 % of reproductive age woman (Kovacs P. Conference Report 2002). The abdominal wall is the commonest extra pelvic implantation site, usually on previous laparotomic or laparoscopic scars. In this paper we report an uncommon case of spontaneous endometriosis of the abdominal wall with no previous surgery or delivery.

- Introduction Abdominal wall endometriosis is a relatively rare condition, usually presented in a previously performed abdominal incision.
- Case presentation We present a case of a young female patient with an abdominal mass, with no previous surgery, that the histopathology report revealed to be an endometriotic lesion.
- Conclusion Abdominal endometriosis can develop spontaneously supporting the coelomatic metaplasia theory, developed by Metzger by 1991.

**Word count:** 1404

### Synopsis

Scar less abdominal wall, is it a rare localization of endometriosis or an unreported one?

---

\*General Surgery Resident

\*\*General Surgery Assistant

\*\*\*General Surgery Graduated Assistant

\*\*\*\* Pathology Chief

\* , \*\* , \*\*\* , \*\*\*\*Serviço Cirurgia Geral, Hospital Nossa Sr<sup>a</sup>

Rosário, Barreiro, (Portugal)

Corresponding Author:

Zacharoula Sidiropoulou

Email: zasidiropoulou@sapo.pt

### Introduction

Endometriosis is a well defined but not such well understood benign gynaecological condition that consists on the presence of endometrial gland and stroma outside the uterus. The endometriotic implants, like the uterus itself, obey to all the hormonal changes present during the menstrual cycle.

Those ectopic implants are most commonly found in the peritoneal cavity, isolated or spread, localized mainly on the pelvic organs but they can also be found

on the pleural cavity, diaphragm, liver, kidneys, muscles and abdominal surgery scars.

The typical extra pelvic abdominal endometriosis consists of the presence of a lump or nodule, localized on abdominal surgery scars, usually caesarean sections, with an incidence of 0.03 to 1 %[1]. Whereas surgical scar endometriosis is well defined, even if poorly understood, spontaneous presentation of the disease has been only accidentally reported.

### Case Presentation

A 28 years old, Caucasian, female patient of Portuguese nationality, G0P0, presented in the general surgery department with complaints of a dysaesthetic abdominal lump, localized in the left iliac fossa, with vague cyclic pain, related to the menses, with 2 years of evolution.

On the objective exam, she presented an ill defined painless subcutaneous nodule, fixed on the aponeurotic plane and no abdominal incision has been identified. The patient denied any relevant anamnestic data.

She was proposed to have an excisional biopsy under local anaesthesia, with no other radiological or histological investigation.

After skin infiltration with Lidocaine 2%, a 3 cm skin incision was made and during the tissue dissection there a bluish nodule was identified fixed on the rectus sheath aponeurosis.

An en-bloc excision of 4 cm tissue, including rectus aponeurotic sheath was performed and a prolene mesh was applied on the aponeurotic plane, in order to correct the surgical provoked defect respecting the no-tension principle.

The skin stitches were removed on the seventh day.

The histopathology report revealed macroscopically a hard bluish nodule and microscopically the presence of endometrial gland with intraglandular haemorrhage and stroma [Table/Fig 4] and [Table/Fig 5], typical features of endometriosis that confirmed the clinical suspicion.

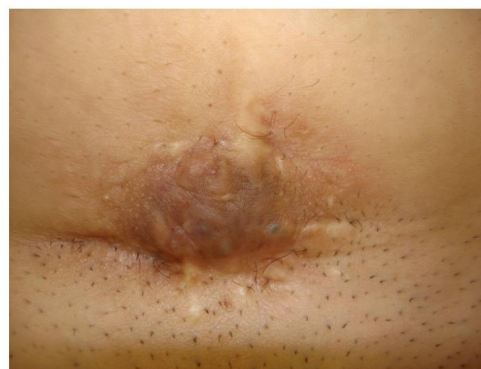A diagnostic laparoscopy was proposed for the patient in order to determine the existence of intra-abdominal disease, since MRI was negative, but the patient denied. Actually she remains asymptomatic.

### Discussion

In the international literature, after a *pub-med* search under the abdominal wall endometriosis search key, 15 reports of spontaneous abdominal wall endometriosis [2],[3],[4],[5],[6],[7],[8],[9],[10],[11],[12],[13],[14],[15],[16] were identified. The most common site was the umbilical scar, with 14 cases, followed by 1 supra pubic , 1 rectus abdominis, 1 thoracic wall and 4 abdominal wall endometriotic foci.

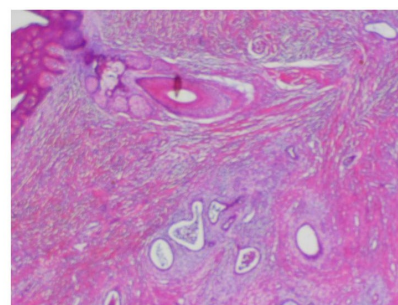
Are we dealing with a miss-diagnosis or with a non reported fact?

In the team's personal experience of 6 years there have been counted 3 cases of abdominal wall endometriosis leaning on previous caesarean section scars [Table/Fig 1] and 1 case of scar less subcutaneous endometriosis.

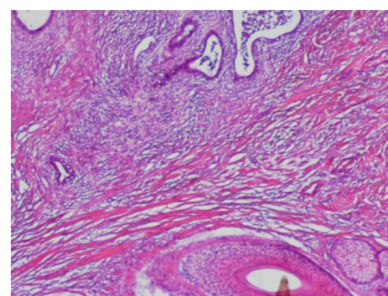


(Table/Fig 1) Caesarean Section endometriosis

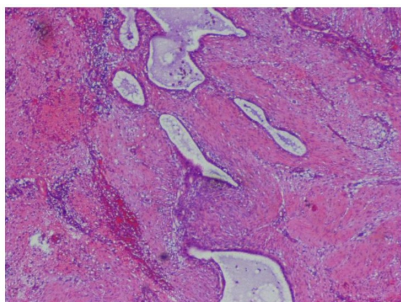
The microscopic features of scar endometriosis are shown on the [Table/Fig 2] and [Table/Fig 3], while [Table/Fig 4] and [Table/Fig 5] show the microscopic features of the spontaneous abdominal wall lesion (intraglandular haemorrhage).



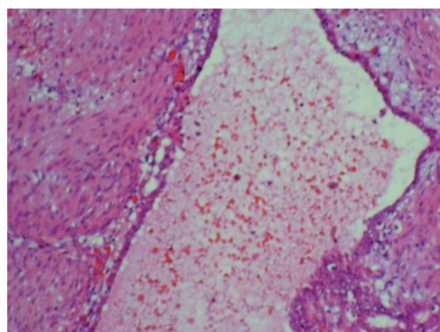
(Table/Fig 2) Microscopic features of scar endometriosis (glands and stroma infiltrating the skin)



(Table/Fig 3) Microscopic features of scar endometriosis (glands and stroma)



(Table/Fig 4) Spontaneous abdominal wall endometriosis, microscopic features (endometrial gland and stroma)



(Table/Fig 5) Detail of intraglandular haemorrhage

Surgical resection provides the healing, but the underlying physiopathology has to be defined.

The current theories on endometriosis aetiology [17] are the following:

- a) Sampson's theory of retrograde transplantation of endometrial tissue during menstrual flux through the fallopian tubes
- b) Meyer's theory of coelomic epithelium metaplasia, according to which there is a "transformation" of the epithelium susceptible to the hormonal influence.
- c) Halban's theory of lymphatic and haematogenous spread of endometrial cells.
- d) Surgical

The authors believe that this rare case supports the coelomatic metaplasia theory which evokes the transformation of coelomatic epithelium that lines the surface of the body wall and abdominal organs, present in various organs and tissues, into endometrial tissue under the influence of estrogens

## Conclusion.

Extra-pelvic endometriosis, especially the ones that arise on surgical scars; need to be reported, as we believe to be an often but not reported condition.

## Abbreviations

G0P0, gesta 0, para 0

MRI, magnetic resonance

## Consent

"Written informed consent was obtained from the patient for publication of this case report and accompanying images. A copy of the written consent is available for review by the Editor-in-Chief of this journal."

## Competing Interests

"The author(s) declare that they have no competing interests".

## Authors' Contributions

ZS performed the surgery and the literature review

AC and PG, oriented the management of the patients and supervised the case

RM is responsible for the pathology examination of the samples.

## References

- [1] Vélez SE, Piccinni DJ, Caminos S, Spitale LS, Ferrari JC. Abdominal wall endometriosis: case report *Revista de la Facultad de Ciencias Médicas (Córdoba, Argentina)*. 01/02/2004; 61(1):44-7.
- Ideyi SC, Schein M, Niazi M, Gerst PH. Spontaneous endometriosis of the abdominal wall. *Dig Surg*. 2003; 20(3):246-8
- [2] Parra PA, Caro J, Torres G, Malagón FJ, Tomás F Primary endometriosis of the abdominal wall: an entity to be included in the differential diagnosis of abdominal wall masses. *Cir Esp*. 2006 Jan; 79(1):64-6

- Victory R, Diamond MP, Johns DA.** Villar's nodule: a case report and systematic literature review of endometriosis externa of the umbilicus. *J Minim Invasive Gynecol.* 2007 Jan-Feb; 14(1):23-32
- [3] Agarwal A, Fong YF. Cutaneous endometriosis. *Singapore Med J.* 2008 Sep; 49(9):704-9.
- Zollner U, Girschick G, Steck T, Dietl J.** Umbilical endometriosis without previous pelvic surgery: a case report. *Arch Gynecol Obstet.* 2003 Feb; 267(4):258-60.
- Frischknecht F, Raio L, Fleischmann A, Dreher E, Lüscher KP, Mueller MD.** Umbilical endometriosis. *Surg Endosc.* 2004 Feb;18(2):347
- Rosina P, Pugliarello S, Colato C, Girolomoni G.** Endometriosis of umbilical cicatrix: case report and review of the literature. *Acta Dermatovenerol Croat.* 2008; 16(4):218-21
- [4] Calò PG, Piludu M, Catani G, Piga G, Mallocci A, Nicolosi A [Umbilical endometriosis. A case report] *Chir Ital.* 2005 Jul-Aug; 57(4):535-7.
- [5] Okunlola MA, Adekunle AO, Arowojolu AO, Oluwasola AO Isolated umbilical endometriosis--a rare finding *Afr J Med Med Sci.* 2002 Sep; 31(3):281-2.
- [6] Hussain M, Noorani K Primary umbilical endometriosis--a rare variant of cutaneous endometriosis *J Coll Physicians Surg Pak.* 2003 Mar;13(3):164-5
- Lee A, Tran HT, Walters RF, Yee H, Rosenman K, Sanchez MR** Cutaneous umbilical endometriosis. *Dermatol Online J.* 2008 Oct 15; 14(10):23.
- Elm MK, Twede JV, Turiansky GW** Primary cutaneous endometriosis of the umbilicus: a case report. *Cutis.* 2008 Feb; 81(2):124-6
- Bordel Gómez MT, Román Curto C, Cardeñoso Alvarez E, Santos Durán JC, Sánchez Estella J, Corral de la Calle M.** [Spontaneous cutaneous umbilical endometriosis] *Actas Dermosifiliogr.* 2006 Dec; 97(10):666-8
- Ledda S, Licheri S, Casu B, Martinasco L, Pulix N, Ambu R, Pisano G, Pomata M, Daniele GM.** [Endometriosis of umbilical cicatrix: a case report and review of the literature] *Chir Ital.* 2002 May-Jun;54(3):405-8
- Ferrara G, Giordano G, Longo M, Magri M.** Primary cutaneous endometriosis of thoracic skin with ovarian granulosa cell tumour. *Acta Obstet Gynecol Scand.* 1993 Apr; 72(3):225-7
- [7] Pritts E, Taylor R. Endometriosis. Chapter 9 on Endotext.com