

A Wildfire in the Abdomen: Asymptomatically Flourishing Extensive Inferior Vena Caval Thrombus

JAGADESH MADIREDDI¹, ROHITH REDDY², RANJAN SHETTY³, ANANTHAKRISHNA SHASTRY⁴

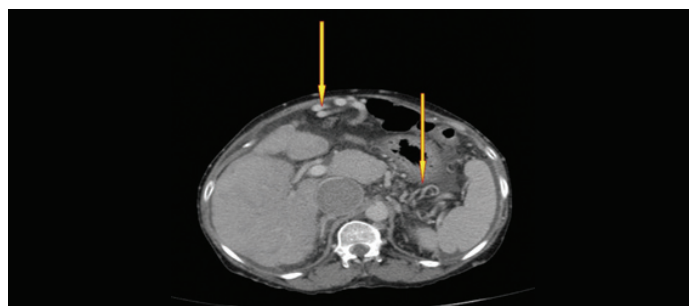
Keywords: Budd-Chiari Syndrome, Cirrhosis, IVC thrombus

Inferior vena caval thrombosis is uncommon and under recognized condition with varied clinical presentation. Clinical presentation of the disease depends primarily on the extent and location of the thrombus in the inferior vena cava (IVC). As a rule proximal and extensive lesions are the ones that are symptomatic and present early.

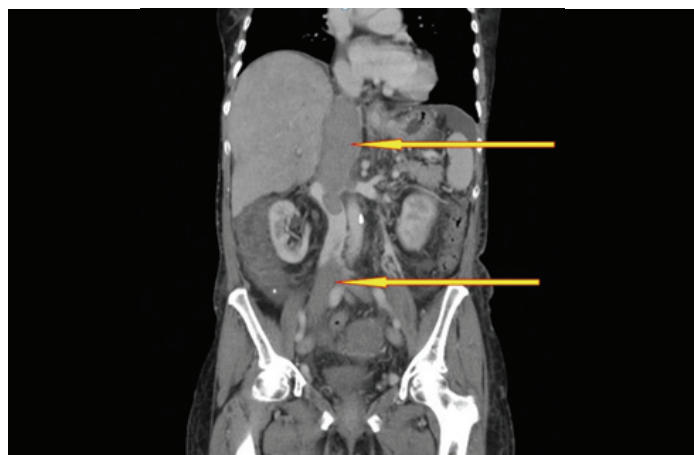We report about a 61-year-old Indian female, with no significant past medical and family history, presented to the outpatient department with vague abdominal discomfort and pedal oedema. Examination revealed non distended abdomen with dilated veins with flow upwards. There was tender hepatomegaly, minimal free fluid and an absent hepato-jugular reflex. Clinical diagnosis of Budd-Chiari Syndrome was considered. Abdominal ultrasonogram showed caudate lobe hypertrophy with coarse echotexture of liver with a thrombus in the inferior vena cava (IVC).

CECT abdomen demonstrated a very extensive thrombus in IVC involving the proximal and intrahepatic IVC along with left, right and middle hepatic veins. There was complete thrombotic occlusion of left proximal renal vein and bilateral common iliac, external iliac, proximal internal iliac, common femoral veins [Table/Fig-1]. An extensive collateral network of veins [Table/Fig-2], explains its

asymptomatic presentation. CECT did not reveal any intraabdominal mass [1]. Coagulation work up was done to rule out common diseases presenting with venous thrombosis. Serum homocysteine levels were normal. Tests for antinuclear and anti phospholipid antibodies were negative. CD 55 and CD 59 were positive ruling out the possibility of paroxysmal nocturnal haemoglobinuria. There was no history of medications known to cause thrombophilia.



[Table/Fig-2]: CECT abdomen; axial section at the level of caudate lobe of liver showing extensive collaterals



[Table/Fig-1]: CECT abdomen; coronal section at the level of IVC, showing thrombus involving the proximal and intrahepatic IVC along with left, right and middle hepatic veins. There was complete thrombotic occlusion of left proximal renal vein and bilateral common iliac, external iliac, proximal internal iliac, common femoral veins

A 2D echocardiogram showed a cruciate shaped thrombus in the IVC and there was no pulmonary artery hypertension. There was no normal IVC segment for filter deployment [2]. She was anti-coagulated with sub-cutaneous enoxaparin sodium and later changed over to oral warfarin [3]. She showed good clinical improvement on follow up, her pedal oedema has decreased and abdominal veins were less prominent. Follow up Ultrasound showed no further increase in size of thrombus.

This case is interesting for its extensive but still asymptomatic presentation of inferior vena caval thrombus. IVC thrombus masquerades as hepatic and/ or cardiac cirrhosis but a simple bed side hepato-jugular reflex is often helpful.

REFERENCES

- [1] Dilawari JB, Bamberg P, Chawla Y, Kaur U, Bhusnurmath SR, Malhotra HS, et al. Hepatic outflow obstruction (budd-chiari Syndrome). Experience with 177 patients and a review of the literature. *Medicine (baltimore)*. 1994;73(1):21-36.
- [2] Molvar C. Inferior Vena Cava Filtration in the Management of Venous Thromboembolism: Filtering the Data. *Semin Intervent Radiol*. 2012;29(3): 204-17.
- [3] Weinberg I, Kaufman J, Jaff MR. Inferior vena cava filters. *JACC Cardiovasc Interv*. 2013;6(6):539-47.

PARTICULARS OF CONTRIBUTORS:

1. Post Graduate, Department of Medicine, Kasturba Hospital, Manipal University, Karnataka, India.
2. Post Graduate, Department of Cardiology, Kasturba Hospital, Manipal University, Karnataka, India.
3. Professor and Head of Unit, Department of Cardiology, Kasturba Hospital, Manipal University, Karnataka, India.
4. Head of Unit, Department of Medicine, Kasturba hospital, Manipal University, Karnataka, India.

NAME, ADDRESS, E-MAIL ID OF THE CORRESPONDING AUTHOR:

Dr. Jagadesh Madireddi,
Flat No 605, Mandavi Pearl City, Manipal, Karnataka-576104, India.
Email: jagadesh.madireddi21@gmail.com

FINANCIAL OR OTHER COMPETING INTERESTS: None.

Date of Submission: **Feb 01, 2015**

Date of Peer Review: **Apr 30, 2015**

Date of Acceptance: **Apr 30, 2015**

Date of Publishing: **Jul 01, 2015**