

Blue Rubber Bleb Nevus Syndrome in a Child

SAHANA M SRINIVAS¹, R. PREMALATHA²

ABSTRACT

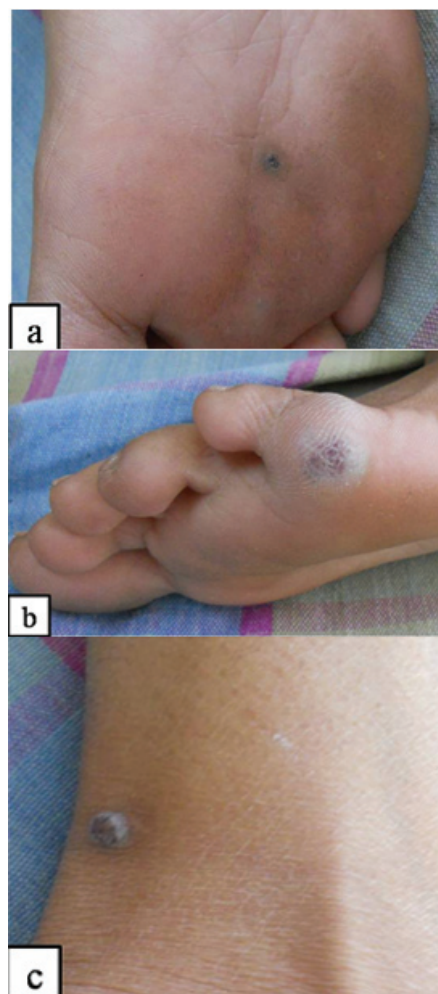
Blue rubber bleb nevus syndrome (BRBNS) is a rare vascular disorder with multiple haemangiomas in the skin, gastrointestinal tract and other visceral organs often associated with fatal bleeding and anaemia. We report a 13-year-old female child with multiple haemangiomas on skin and gastrointestinal tract with refractory anaemia. Awareness of this entity is necessary to prevent complications.

Keywords: Anaemia, Gastrointestinal malformation, Haemangiomas

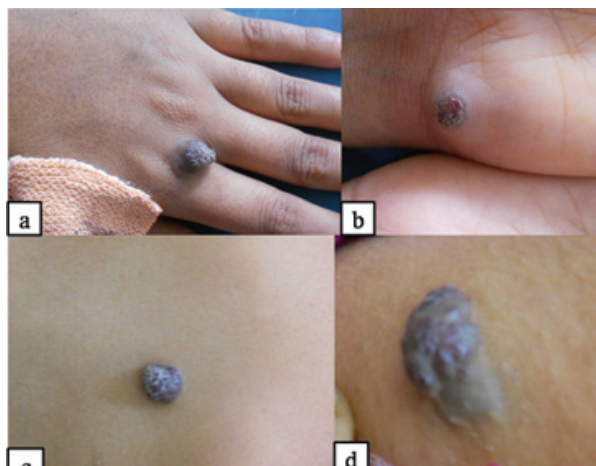
CASE REPORT

A 13-year-old female, child born of non consanguineous marriage was referred to Department of Pediatric Dermatology for multiple nevi on trunk and extremities from birth. It was slowly progressive with occasional bleeding from these lesions. She had generalized weakness, fatigue and anaemia from past three years. She was evaluated at various hospitals for anaemia but the cause was not known. There was no history of fever, nausea, vomiting, pain abdomen, melena, haematemesis, epistaxis or recurrent infections. She had received multiple blood transfusions but had recurrent anaemia. Her developmental milestones were normal. Family history was non contributory.

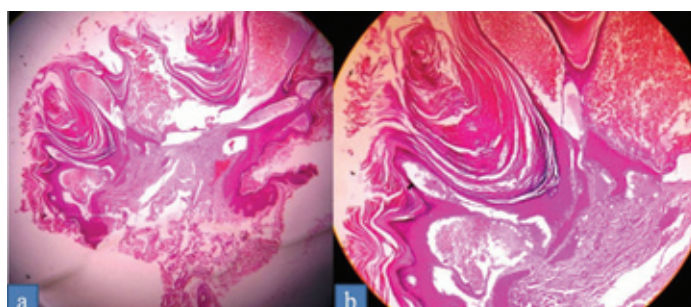
On examination, the child had pallor. Vital parameters were normal. Cutaneous examination showed multiple well defined soft compressible bluish-black, verrucous, protuberant bleb like nevi on the dorsum of left hand, left palm, chest, thighs, both soles and medial aspect of left lower leg [Table/Fig-1,2]. Oral mucosa was normal. Laboratory investigations revealed severe anaemia (haemoglobin-3.7gm/dl), thrombocytopenia (platelet count - 89000/mm³), peripheral smear showed microcytic hypochromic anaemia, with anisopikilocytosis and few target cells. Serum ferritin levels were very low (2.22ng/ml). Stool for occult blood was negative. Ultrasound showed mild hepatosplenomegaly with no focal lesions. Upper GI endoscopy was normal. Colonoscopy showed multiple nodular bluish nevi measuring 3x2 cm in the sigmoid colon. Other investigations like chest X-ray, liver functions test, haemoglobin electrophoresis and bone marrow examination was normal. Skin biopsy revealed epidermis with papillomatosis and orthohyperkeratosis, papillary dermis and reticular dermis showed large ectatic spaces lined by endothelial cells filled with blood [Table/



[Table/Fig-2]: Bluish-black, verrucous nevi present on both soles (a,b) and medial aspect of left lower leg©



[Table/Fig-1]: Multiple well defined soft bluish-black, verrucous, protuberant bleb like nevi on the dorsum of left hand (a), left palm (b), chest (c) and back (d)



[Table/Fig-3]: (a) Epidermis shows papillomatosis and hyperkeratosis, papillary and reticular dermis shows large ectatic spaces lined by endothelial cells filled with blood (H and E x 40). (b) Papillary dermis showing large vascular spaces filled with blood (H and E x 40)

Fig-3a,b]. Based on clinical examination and investigation diagnosis of blue rubber bleb nevus syndrome (BRBNS) was considered. The child was given blood transfusion with long term iron supplements. The child could be followed up for three months and after that did not turn up.

DISCUSSION

BRBNS or Bean syndrome is a rare congenital disorder characterized by multiple venous malformations in skin, gastrointestinal tract and other organs. BRBNS has the potential for fatal bleeding [1]. Although sporadic, autosomal dominant inheritance has been reported. Recently it has been linked to mutation in chromosome 9p responsible for venous malformation [2]. Most cases reported from India are sporadic in nature [3,4]. The pathogenesis of the condition is still not clear.

Around 200 cases have been reported in literature. Majority of the cases reported have cutaneous and gastrointestinal involvement [5,6]. Cutaneous lesions are present from birth, but may increase in number with age. They are characterized by soft compressible bluish-black, verrucous, protuberant blebs of varying size [4]. They are often non tender, but occasionally painful. Three types of skin lesions have been described, large disfiguring lesions obstructing vital tissues, purple-black compressible rubbery nipple like angiomas and irregular blue black macules [7]. They are discrete, multifocal mainly distributed on trunk, extremities, palms and soles but can be seen anywhere in the body. Rarely these nevi can be situated in subcutaneous fat not appearing as blue blebs. Recently unilateral linearly distributed, along the lines of Blaschko has been reported [8]. Oral lesions occur in 59-64% cases, most common sites being buccal mucosa, retromolar trigone and ventrolateral tongue [9].

Visceral malformation mainly affects the gastrointestinal tract. They may occur anywhere from oral to anal mucosa but more commonly occur in the small bowel. They are sessile or polypoid and visualized by endoscopy. Gastrointestinal lesions frequently bleed as compared to skin lesions which rarely bleed. Chronic bleeding may lead to iron deficiency anaemia, bloody stool and thrombocytopenia. Rarely massive haemorrhage, bowel infarction, intussusceptions and volvulus may occur [10]. The lesions may also occur in nasal cavity, nasopharynx, eyes, thyroid, parotids, central nervous system, skeletal muscles, pleura, peritoneum, pericardium, mesentery, synovium, lungs, kidneys, liver, spleen, penis, vulva and bladder [9,10]. Other complications include skeletal bowing, pathological fracture, bony overgrowth, articular derangement and pain due to phleboliths. Rarely it is been associated with ventricular hypertrophy and atrial septal defect [7,9].

As compared to the cases reported in literature our case also had similar features of cutaneous and gastrointestinal nevi. In 30-40% cases the onset of disease is from birth [5]. Our case also presented with symptoms from birth. Rare complications reported in literature include thrombocytopenia which was seen in our case [5]. The cause of this complication is not clearly understood.

Differential diagnosis includes Maffucci syndrome, venous lakes, Osler

Weber Rendu syndrome (hereditary haemorrhagic telangiectasia), Klippel-Trenaunay/Parker-Weber syndrome, and disseminated haemangiomas and Kaposi sarcoma [11]. Histopathological examination of skin and gastrointestinal lesions shows vascular tissues with tortuous, blood filled ectatic vessels, lined by a single layer of endothelium, with surrounding thin connective tissue [2]. Gastrointestinal tract lesions can be evaluated by endoscopy, barium studies and nuclear imaging. Capsule endoscopy can detect lesions in small intestine. Sonography, MRI and doppler can confirm the nature of lesions [9,10].

Several modalities of therapy have been tried. Blood transfusion and iron tablets are given for iron deficiency anaemia. Cryotherapy, sclerotherapy, excision and long pulsed Nd: YAG 1064nm laser has been used for cutaneous lesions. Gastrointestinal lesions can be treated with excision, cauterization, endoscopic laser photocoagulation, sclerosis, band ligation or polypectomy [12]. If there is a life threatening haemorrhage, segmental resection of the involved gastrointestinal tract can be performed.

CONCLUSION

BRBNS is a rare but important condition as it can give rise to fatal bleeding and complications. Child presenting with anaemia of unknown origin with multiple haemangiomas of skin poses a great diagnostic challenge that requires an open mind so as not to miss any rare cause. Parents should be counseled in detail about the nature of the condition and follow up regularly. This case is presented for its rarity, as early diagnosis of this condition will prevent complications.

REFERENCES

- [1] Dwivedi M, Misra SP. Blue rubber bleb nevus syndrome causing upper GI haemorrhage: a novel management approach and review. *Gastrointest Endosc.* 2002;55:943-46.
- [2] Liu Q, Chen YP, Li YM. Blue rubber bleb nevus syndrome: a report of one case associated with recurrent epistaxis. *Chin Med J.* 2007;120:731-33.
- [3] Kumar A, Negi SR, Vaishnav K, Jain K. Blue rubber bleb nevus syndrome: a rare case report. *Indian J Pathol Microbiol.* 2015;58:258-59.
- [4] Sahu MK, Simon EG, Joseph JA, Chacko A. Blue rubber bleb nevus syndrome: case report and review of the literature. *Journal of Digestive Endoscopy.* 2010;1:183-85.
- [5] Jin XL, Wang ZH, Xiao XB, Huang LS, Zhao XY. Blue rubber bleb nevus syndrome: a case report and literature review. *World J Gastroenterol.* 2014;20:17254-59.
- [6] Zahedi MJ, Darvish Moghadam S, Seyed Mirzaei SM, Dehghani M, Shafiei Pour S, Rasti A. Blue rubber bleb nevus syndrome as a rare cause of iron deficiency anemia: a case report and review of literature. *Middle East J Dig Dis.* 2013;5:235-39.
- [7] Aroor S, Varma C, Mundkur SC. Blue rubber-bleb nevus syndrome which was associated with an atrial septal defect: a case report. *Journal of Clinical and Diagnostic Research.* 2012;9:1566-67.
- [8] Xu Y, Zhou B, Zhang M, Luo D. An unusual case of blue rubber bleb nevus syndrome with unilateral linear distribution. *Indian J Dermatol Venereol Leprol.* 2013;79:269-70.
- [9] Suma GN, Ravi Prakash SM, Rao D, Goel S. Blue rubber bleb nevus syndrome: prominent oral findings. *Indian J Dermatol Venereol Leprol.* 2010;76:168-71.
- [10] Maisnam I, Das T, Kundu AK, Ghosh A. Blue rubber bleb nevus syndrome causing refractory anaemia. *J Assoc Physicians India.* 2010;58:246-49.
- [11] Kaur T, Singh S. Blue rubber bleb nevus syndrome: a case report. *Indian J Dermatol.* 2014;59:98-99.
- [12] Shin SH, Chae HS, Ji JS, Kim HK, Cho YS, Chang ED. A case of blue rubber bleb nevus syndrome. *Korean J Inter Med.* 2008;23:208-12.

PARTICULARS OF CONTRIBUTORS:

1. Consultant Pediatric Dermatologist, Department of Pediatric Dermatology, Indira Gandhi Institute of Child Health, Bangalore, Karnataka, India.
2. Professor of Pediatrics and Director, Department of Pediatrics, Indira Gandhi Institute of Child Health, Bangalore, Karnataka, India.

NAME, ADDRESS, E-MAIL ID OF THE CORRESPONDING AUTHOR:

Dr. Sahana M. Srinivas,
Consultant Pediatric Dermatologist, Department of Pediatric Dermatology,
Indira Gandhi Institute of Child Health, Bangalore-560029, India.
E-mail: drsahanasrinivas@rediffmail.com

FINANCIAL OR OTHER COMPETING INTERESTS: None.

Date of Submission: **Jan 19, 2015**
Date of Peer Review: **Apr 22, 2015**
Date of Acceptance: **May 23, 2015**
Date of Publishing: **Jul 01, 2015**