

Comparative Evaluation of Three Different Obturating Techniques Lateral Compaction, Thermafil and Calamus for Filling Area and Voids Using Cone Beam Computed Tomography: An Invitro study

RUCHI GUPTA¹, ANIL DHINGRA², NIDHI R PANWAR³

ABSTRACT

Introduction: The success of root canal treatment depends upon the proper sealing of root canal system. Improper apical seal leads to the microleakage which can be prevented by proper obturation technique.

Aim: To compare the quality of three different root canal obturation techniques: lateral compaction, Thermafil and Calamus by using cone beam computed tomography.

Materials and Methods: A total of 30 central incisors were selected. Biomechanical preparation was done by Reciproc file no 25. Teeth were divided into 3 groups of 10 teeth each according to the obturation technique i.e. Calamus, Thermafil

and lateral compaction. Cone beam computed tomography was used to measure filling area and voids at coronal, middle and apical third of the root canal after obturation by different techniques. Data was statistically analysed by One-Way Anova and multiple comparison of Tukey HSD tests.

Result: The maximum amount of obturating material was observed in Calamus group followed by Thermafil and lateral compaction. Minimum voids were seen in obturation by Calamus technique.

Conclusion: Within the limitations of this study, it can be concluded that Calamus may be a good obturation technique.

Keywords: Apical-third, CBCT, Hermatic seal, Microleakage, Obturation, Reciproc

INTRODUCTION

A three dimensional seal of the root canal system is achieved by proper root canal obturation to prevent the recurrence of bacterial infection. The microleakage between the root canal and the periapical tissues is hindered leading to death of any surviving microorganisms. This prevents the entry of nutrients and toxic bacterial products into the periapical tissues [1].

Various techniques have been developed to achieve the proper obturation of root canal system including the vertical compaction, lateral compaction and carrier based obturation [2-5]. Over the years, pitfalls with one technique have often led to the development of newer methods of obturation. Lateral compaction of GP is the gold standard technique [2]. Thermafil provides a void free obturation along with minimal sealer thickness and a higher degree of homogeneity [2]. Calamus is a recent technique of obturation of root canal system [6]. The ability to provide fluid tight apical seal determines the efficacy of a particular obturation technique [7]. Although the sealing properties of different obturation systems have been investigated, the effect of overall sealing performance with calamus obturating system in various levels of root canal is still unknown.

Numerous materials and techniques have been developed for filling root canals. It has been reported that the quality of adaptation between the surface of the root canal and the gutta percha is dependent on the rotary file used for biomechanical preparation [8-10]. Previous studies shows conflicting results regarding the role of files in the sealing ability of the obturating material. There is no dental literature in endodontics regarding the obturation of root canals after biomechanical preparation with Reciproc rotary files. The purpose of this study is to evaluate three obturation techniques - lateral compaction, Thermafil and Calamus at different levels after biomechanical preparation with Reciproc rotary system using Cone beam computed tomography

MATERIALS AND METHODS

This is an original in vitro research conducted in Department of Conservative Dentistry and Endodontics, Ghaziabad in November, 2014. In this study 30 periodontally compromised freshly extracted human single-rooted premolars, verified radiographically were selected. Teeth with curved roots, fractures, cracks or any other defects were excluded from the study. The consent from patients and ethical board was obtained for procuring the extracted teeth. They were stored in a 0.1% thymol. Access cavity preparation was done and working length was determined by inserting a size 10 K file (Dentsply Maillefer) into the root canal until it was visible at the apical foramen and subtracting 1mm from that length. Biomechanical preparation of the root canal using a single use instrument i.e. Reciproc R25 was done. A VDW Silver electric motor was used to activate the instrument in a reciprocating motion. Gently an in-and-out pecking motion was used to reach the apex with amplitude of approximately 3 mm. A brushing action was combined with a gentle apical pressure against the lateral walls. Irrigation is done by 25 mL of 2.5% NaOCl followed by 5 mL of 17% EDTA aqueous solution. Five mL of a 2.5% NaOCl solution was used for final irrigation. The canals were dried with paper points after irrigation. The same operator did all intracanal procedures to eliminate interoperator variability. Teeth were randomly divided into three experimental groups according to the obturation technique [10].

Calamus Technique

The Calamus Flow handpiece was used with a one-piece gutta percha cartridge and integrated cannula to dispense warm gutta-percha. The cartridges was used on a single patient [11]. The Calamus dual 3D obturation system (Dentsply Maillefer, Ballaigues, Switzerland) was used along with AH Plus root canal sealer (Dentsply De Trey, Konstanz, Germany).

Thermafill Technique

A size #25 verifier was checked for its fitting in the canal at the working length. The same size obturator was selected and heated in the ThermaPrep Plus Oven (Dentsply Maillefer, Holland). The canal was dried followed by application of AH Plus sealer to the coronal portion of the canal. Then the obturator was slowly placed in a single motion at the working length. The obturator was severed at canal orifice after cooling the gutta percha [3].

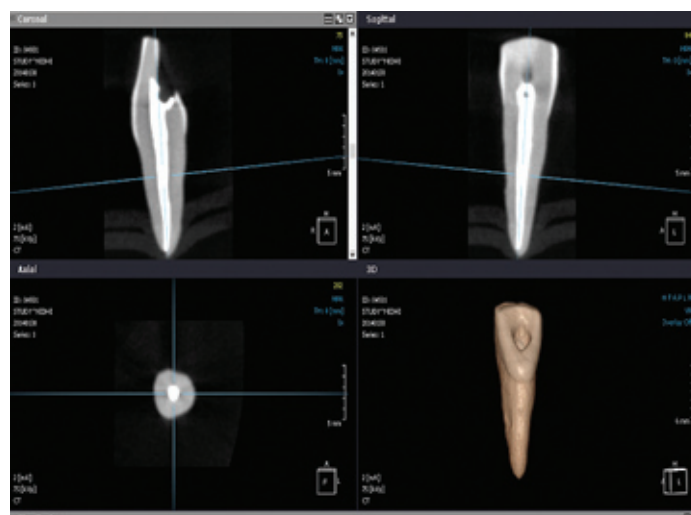
Lateral Compaction Technique

Cold lateral compaction was done by a master gutta-percha cone of size 25 and accessory gutta-percha points of size 20 and 15 with AH Plus sealer. The excess coronal gutta-percha was removed by a heated instrument [12].

The above mentioned three experimental groups were compared with control group which consists of two teeth without obturation. The canal access of all the teeth was restored with Cavit-G (3M Espe, Germany), and the teeth were stored under 100% humidity at 37°C. Teeth were radiographed in buccolingual and mesiodistal direction to confirm the adequacy of root fillings. Assessment of quality of obturation was done by calculating the filling area and voids in each tooth at coronal, middle and apical third of the root canal by CS9300 CBCT scanner (Carestream Healthcare India (P) Ltd, India) in the high resolution dental mode (i.e. 90 micron resolution) using the On Demand 3D App software.

RESULTS

The amount of filling area in the obturation in all the three groups is shown in [Table/Fig-1]. The CBCT images of the obturated tooth are shown in coronal, sagittal, axial and 3D view [Table/Fig-2]. Voids were observed in all obturated samples regardless of the groups examined. The data was statistically analysed by One-Way ANOVA test followed by multiple comparisons by Tukey HSD. A p-value of 0.05 was considered to be statistically significant. These results demonstrated that group I (Obturation by Calamus) resulted in maximum filling area followed by group II (Thermafill) and group III (Lateral compaction). Maximum amount of obturating material was seen with obturation by Calamus technique which was also statistically significant. Maximum amount of gutta-percha was found at coronal third and least in apical third of the root canal in all the groups [Table/Fig-1,2]. There were no voids with Calamus at three level cervical middle and apical, with Thermafill voids are seen at cervical region only but with lateral condensation voids are seen at all the three levels cervical and middle region.



[Table/Fig-2]: CBCT images of the obturated tooth (a) Coronal (b) Sagittal (c) Axial (d) 3D images

DISCUSSION

Improper obturation of root canal leads to post-operative complications resulting in failure of endodontic therapy. The root canal space is sealed perfectly by a three-dimensional obturation of the root canal system [11]. It prevents penetration of bacteria and their products into the periradicular tissues and create a favourable biological environment for the healing of peri-apical tissues.

The disposable instruments have been recommended to decrease instrument fatigue and cross contamination. It also reduces the cost and the number of NiTi rotary instruments required for root canal preparation. Reciproc instrument (VDW, Munich, Germany) is made of standard NiTi alloy with M-wire treatment [10,12]. Three sizes R25, R40 and R50 are used according to the initial canal diameter. The taper of the instrument is 0.08, 0.06 and 0.05 mm for the R25, R40 and R50 instruments, respectively. A reciprocating movement of 10 cycles per second is used. The instrument is rotated at 360 degrees at three reciprocating cycles [13]. There is no dental literature regarding the quality of obturation after using Reciproc rotary file for biomechanical preparation.

Different type of obturating systems can influence the quality of obturation [14]. In this study lateral compaction, Thermafill and Calamus were used for obturation to ensure which technique have the maximum voids and filling area after obturation. The quality of obturation after using Calamus obturating system has not been assessed yet. The Calamus dual 3D (Dentsply Maillefer, Ballaigues, Switzerland) Obturation System is one unit that conveniently

Descriptive Data									
		N(Number of specimens)	Mean	Std. Deviation	Std. Error	95% Confidence Interval for Mean		Minimum	Maximum
						Lower Bound	Upper Bound		
Apical	C(Calamus)	10	0.204400	0.0025033	0.0007916	0.202609	0.206191	0.2010	0.2090
	T(Thermafill)	10	0.192900	0.0045814	0.0014488	0.189623	0.196177	0.1860	0.1990
	LC(Lateral compaction)	10	0.110100	0.0045570	0.0014411	0.106840	0.113360	0.1040	0.1170
	Total	30	0.169133	0.0428982	0.0078321	0.153115	0.185152	0.1040	0.2090
Middle	C(Calamus)	10	1.286000	0.0026247	0.0008300	1.284122	1.287878	1.2810	1.2890
	T(Thermafill)	10	0.574400	0.0195914	0.0061953	0.560385	0.588415	0.5300	0.6000
	LC(Lateral compaction)	10	0.502200	0.0044422	0.0014048	0.499022	0.505378	0.4950	0.5090
	Total	30	0.787533	0.3599231	0.0657127	0.653136	0.921931	0.4950	1.2890
Coronal	C(Calamus)	10	2.594700	0.0024967	0.0007895	2.592914	2.596486	2.5910	2.5980
	T(Thermafill)	10	1.880100	0.0282703	0.0089399	1.859877	1.900323	1.8450	1.9260
	LC(Lateral compaction)	10	0.933900	0.0216151	0.0068353	0.918438	0.949362	0.9110	0.9800
	Total	30	1.802900	0.6921265	0.1263644	1.544456	2.061344	0.9110	2.5980

[Table/Fig-1]: Amount of filling area in the obturation

combines both Calamus "Pack" and Calamus "Flow" handpiece. With the Pack and Flow positioned side-by-side, a dense apical plug is created. Then Flow will be used to deliver the gutta-percha. An ergonomically designed hand piece has a 360 degree activation cuff which provides a smooth, continuous expression of gutta-percha [6].

The Calamus Pack handpiece with an Electric heat plugger (EHP) is utilized to thermosoften, remove and condense guttapercha in the downpacking phase of obturation. The EHPs are available in three ISO colour black, yellow, and blue which correspond to working end diameters and tapers of 40/03, 50/05, and 60/06, respectively. The cone beam computed tomography was used to outweigh the limitation of the methodologies previously applied in endodontic treatment studies, such as displacement of the filling debris during cleavage and two-dimensional imaging on a three-dimensional structure in a non-invasive manner [15,16].

The 3D obturation was best with Calamus as compared to Thermafill and lateral condensation. Best results with Calamus could be explained on the basis of the maximum inert core material, minimum amount of sealer and a higher degree of homogeneity associated with the calamus [6]. Poor results with Thermafill as compared to calamus can be explained by the fact that as in Thermafill obturation, guttapercha can flow through the apical foramen. Thermafill obturation has some other disadvantages like the carrier in the guttapercha may get stripped off in curved and elliptical canals. Worst results were shown by lateral compaction which lack homogeneity of gutta percha mass, less adaptation to canal walls, irregularities and increased number of voids. This is supported by previous studies [10]. Thermafill technique was superior to lateral condensation. It is less time consuming, resulted in filling of accessory canals with gutta percha, more homogeneous mass, had fewer voids and replicated the surface of the roots better.

Maximum amount of voids were also seen in lateral compaction followed by Thermafill and Calamus. More voids were seen in coronal as compared to middle and apical third. This can be due to more amount of guttapercha in coronal third of the root canal. The quality of root canal obturation in thirds of the root length was also assessed using micro-CT. The lowest mean volume of voids was found in the coronal and middle third. None of the tested materials led to a void free canal filling [15].

CONCLUSION

Within the limitations of this study, it can be concluded that none of the obturation technique is able to seal the root canal completely.

The Calamus may be a good alternative for perfect quality of 3D Obturation and it may be helpful in obtaining the good hermetic seal in endodontically treated teeth in future. Further research is required in determining the amount of filling area and voids in other obturation techniques.

REFERENCES

- [1] Weller RN, Kimbrough WF, Anderson RW. A comparison of thermoplastic obturation techniques: adaptation to the canal walls. *J Endod.* 1997;23:703-06.
- [2] Gencoglu N. Comparison of 6 different gutta-percha techniques (partII): Thermafill, JS Quick-fill, soft core, Microseal, system B, and lateral condensation. *Oral Surg Oral Med Oral Pathol Endod.* 2003;96:91-95.
- [3] Tasdemir T, Yesilyurt C, Ceyhanli TK, Celik D, Kursat Er. Evaluation of apical filling after root canal filling by 2 different techniques. *J Can Dent Assoc.* 2009;75:201.
- [4] Hale R, Gatti R, Glickman G, Opperman L. Comparative analysis of carrier-based obturation and lateral compaction: a retrospective clinical outcomes study. *Int J Dent.* 2012;9:1-8.
- [5] Robberecht L, Colard T, Claisse-Crinquette A. Qualitative evaluation of two endodontic obturation techniques: tapered single-cone method versus warm vertical condensation and injection system. an in vitro study. *J Oral Sci.* 2012;54:99-104.
- [6] Ruddle CJ. Filling root canal systems: the Calamus 3-D obturation technique. *Dent Today.* 2010;29(4):76, 78-81.
- [7] Emmanuel S, Shantaram K, Sushil KC, Manoj L. An in-vitro evaluation and comparison of apical sealing ability of three different obturation technique - lateral condensation, obtura ii, and thermafill. *J Int Oral Health.* 2013;5(2):35-43.
- [8] Von Fraunhofer JA, Fagundes DK, McDonald NJ, Dumsha TC. The effect of root canal preparation on microleakage within endodontically treated teeth: an invitro study. *IntEndod J.* 2000;33:355-60.
- [9] Taneja S, Chadha R, Gupta R, Gupta A. Comparative evaluation of sealing properties of different obturation systems placed over apically fractured rotary NiTi files. *J Conserv Dent.* 2012;15:36-40.
- [10] Zuolo AS, Mello JE, Cunha RS, Zuolo ML, Bueno CE. Efficacy of reciprocating and rotary techniques for removing filling material during root canal retreatment. *Int Endod J.* 2013;46:947-53.
- [11] Qureshi B, Munir B, Akbar I. A comparison of thermafill and lateral condensation techniques in obturation of root canal systems. *Pakistan oral & dental journal.* 2012;32:531-34.
- [12] Inan U, Aydin C, Tunca YM, Basak F. In vitro evaluation of matched-taper single-cone obturation with a fluid filtration method. *J Can Dent assoc.* 2009;75:123.
- [13] Alves FRF, Rocas IN, Almeida BM, Neves MAS, Zoffoli J, Siqueira JF. Quantitative molecular and cultural analysis of bacterial elimination in oval shaped root canals by a single file instrumentation techniques. *I Endod J.* 2012;45:871-77.
- [14] Dhingra A, Kochar R, Banerjee S, Srivastava P. Comparative evaluation of the canal curvature modifications after instrumentation with one shape rotary and wave one reciprocating files. *J Conserv.* 2014;17(2):138-41.
- [15] Keles A, Alcin H, Kamalak A, Versiani MA. 3D Micro-CT evaluation of root filling quality in oval-shaped canal. *Int Endod J.* 2014;47:1177-84.
- [16] Gupta R, Dhingra A, Neetika. Efficacy of various instrumentation techniques for removing filling material during root canal retreatment using cone beam computed tomography –an in-vitro study. *Int Org Sci Res J Dent Med Sci.* 2015;14:116-20.

PARTICULARS OF CONTRIBUTORS:

1. Professor, Department of Conservative Dentistry and Endodontics, Divya Jyoti College of Dental Sciences & Research, Delhi-Meerut Road, Modinagar, Uttar Pradesh, India.
2. Professor & Head, Department of Conservative Dentistry and Endodontics, Divya Jyoti College of Dental Sciences and Research, Delhi-Meerut Road, Modinagar, Uttar Pradesh, India.
3. Post Graduate Student, Department of Conservative Dentistry and Endodontics, Divya Jyoti College of Dental Sciences and Research, Delhi-Meerut Road, Modinagar, Uttar Pradesh, India.

NAME, ADDRESS, E-MAIL ID OF THE CORRESPONDING AUTHOR:

Dr Ruchi Gupta,
Professor, Department of Conservative Dentistry and Endodontics, Divya Jyoti College of Dental Sciences & Research,
Delhi-Meerut Road, Modinagar, Uttar Pradesh-201201, India.
E-mail: druchigupta@rediffmail.com

FINANCIAL OR OTHER COMPETING INTERESTS: None.

Date of Submission: **Nov 21, 2014**
Date of Peer Review: **Feb 17, 2015**
Date of Acceptance: **May 22, 2015**
Date of Publishing: **Aug 01, 2015**