

A Survivor of Neonatal Intestinal Mucormycosis

PRAGATI ADITYA SATHE¹, RATNAPRABHA KUNDLIKRAO GHODKE², BHUVANESHWARI MAHENDRA KANDALKAR³

ABSTRACT

Gastrointestinal mucormycosis (GIM) is a rare opportunistic fungal infection. One third of all patients are children and of these, 50% are infants. The most common clinical mimic is necrotizing enterocolitis (NEC). It has to be differentiated from this entity as the treatment is entirely different. High index of suspicion by the clinicians and the pathologists aids in early diagnosis and immediate treatment. If untreated, it has a frequent fatal outcome. Very few survivors of GIM are found in literature. We report a rare case of a surviving neonate of GIM.

Keywords: Enterocolitis, Fungal, Laparotomy

CASE REPORT

A full term male neonate, with birth weight 1.750 kilograms, was diagnosed to have an anorectal malformation at birth. A cut back anoplasty was performed on the third day of life. The baby was referred to our hospital one day later, for bilious vomiting and abdominal distension. On admission, the general condition was poor. The child was dehydrated and icteric. The tongue was coated with slough. On examination, there was mild epigastric distension. All haematological investigations except platelet count (40,000 per cu.mm) were within normal range. Total and direct bilirubin levels were 12.2 mg% and 6.8 mg% respectively. Mother tested negative for HIV antibody test. With the clinical and radiologic diagnosis of intestinal perforation, exploratory laparotomy was performed on the fourth day of life. A gangrenous jejuno-ileal segment was resected and an anastomosis was done. On excision, a ten centimeter long dull and dusky intestinal segment was received. Mesenteric vessel thrombosis was seen. On opening, the mucosa was blackish and edematous. The resection margins were viable. Histopathology showed transmural necrosis with neutrophilic inflammatory infiltrate and plenty of nuclear debris [Table/Fig-1a-d]. Also, seen transmurally, were pale staining, broad, aseptate fungal hyphae showing right angle branching suggestive of intestinal mucormycosis. The

morphology was different from *Aspergillus* where the hyphae are slender, septate and show acute angle branching. Mesenteric vessels showed fresh thrombi with fungal hyphae within. Gomori's methenamine silver stain highlighted the fungi black [Table/Fig-1a-d]. Material from tongue slough was sent for mycology culture after the diagnosis of mucormycosis was given on histopathology. However, culture results were noncontributory. The patient was treated with intravenous liposomal Amphotericin B. The patient responded well, had a functioning anastomosis at the time of discharge and is well after a follow up of six months.

DISCUSSION

GIM is the rarest form of mucormycosis accounting for 7% of all cases [1]. Among the affected children, about half of the cases are seen in infants [2]. In neonatal GIM, the colon is predominantly involved as opposed to stomach in childhood and adult forms. Since its first review in 1994, about 30 cases of neonatal GIM have been reported in English literature till date [1,3]. Of these, 22 are from India [1,3-5].

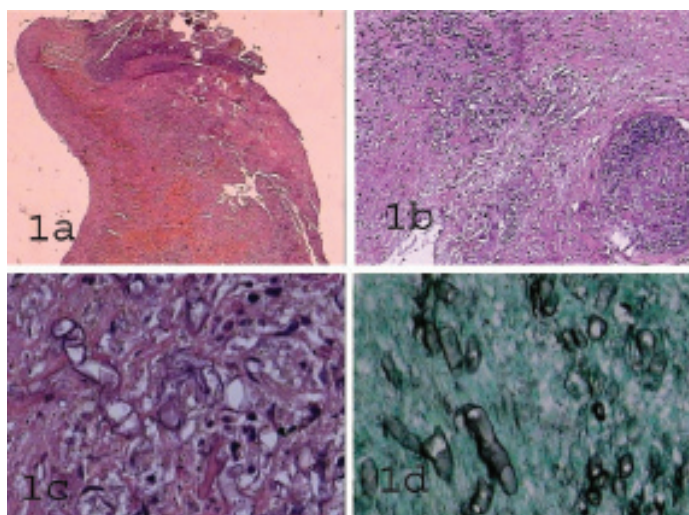
Low birth weight, prematurity, steroid therapy, gastrointestinal interventions, endotracheal intubation, indomethacin therapy are the main risk factors [2,6]. Our patient had two risk factors namely low birth weight and anorectal surgery. The fungus gains entry to the gastrointestinal tract by ingestion of fomites contaminated with fungal spores or by swallowing infected sputum or rarely by haematological dissemination from other primary sites of infection. The most common differential diagnosis is neonatal NEC [7]. The absence of pneumatosis intestinalis, poor response to antibiotics, widespread thrombosis of small vessels of the gut and demonstration of fungi differentiate GIM from classical NEC [1,7]. Aggressive early surgery to reduce fungal load followed by intravenous amphotericin B is the mainstay of treatment [1].

Survival also depends upon the extent of disease, the immunological status of patient and the virulence of the organism.

Only thirteen cases have survived so far according to literature [Table/Fig-2] [1,2,4-6]. Ours is the 14th case of a neonate surviving mucormycosis of the gastrointestinal tract.

CONCLUSION

To conclude, pathologists and clinicians need to have a high index of suspicion in all cases with symptoms of NEC, especially in a preterm child, who does not respond to antibiotic therapy.



[Table/Fig-1a-d]: a. Transmural necrosis of the ileal wall. (H&E, x100)
b. Necrotic intestinal wall and a mesenteric vessel with thrombus. (H&E, x100)
c. Broad, aseptate fungal hyphae. (H&E, x400)
d. Gomori's Methenamine stain showing the fungal hyphae. (H&E, x400)

Author	No. of cases	Age	Sex	Location	Predisposing factors	Clinical diagnosis/complaints
Kataria [8]	1	Day 1	Female	Colon	Postoperative	Necrotizing enterocolitis /Abdominal distension
Alexander [9]	1	Day 7	Female	Colon	Barium enema	Small left colon syndrome/Abdominal distension
Budhiraja [10]	1	Day 16	Male	Colon	Exchange blood transfusion	Abdominal distension
Jain [2]	1	Day 13	Male	Terminal ileum	Small for date	Abdominal distension, bilious vomiting, not passing stools
Michalak [6]	1	Day 1	Not mentioned	Stomach, appendix	Prematurity	Abdominal distension
Kecskes [6]	1	Day 1	Not mentioned	Colon	Prematurity	Abdominal distension
Siu [6]	1	Day 15	Male	Terminal ileum	Extremely low birth weight, prematurity	Abdominal distension
Sarin [1]	1	Day 2	Male	Terminal ileum	Nasogastric intubation	Necrotizing enterocolitis/Abdominal distension
Patra [4]	4	Day 8-22	Males 2 Females 2	Colon 2 Terminal ileum 2	Prematurity 3	Necrotizing enterocolitis 3 Total colonic aganglionosis 1
Agrawal [5]	1	Day 2	Not mentioned	Not mentioned	Not mentioned	Abdominal distension
Present case	1	Day 4	Male	Ileum	Cut back anoplasty, low birth weight	Abdominal distension

[Table/Fig-2]: Survivors of neonatal intestinal mucormycosis (n=14)

REFERENCES

- [1] Sarin YK. Intestinal mucormycosis in a neonate: a case report and review. *J Indian Assoc Pediatr Surg.* 2010;15:98-100.
- [2] Jain D, Kohli K. Neonatal gastrointestinal mucormycosis clinically mimicking necrotizing enterocolitis. *Eur J Pediatr Surg.* 2009;19:405-07.
- [3] Reimund E, Ramnos A. Disseminated neonatal gastrointestinal mucormycosis: A case report and review of the literature. *Pediatr Pathol.* 1994;14:385-89.
- [4] Patra S, Vij M, Chirla DK, Kumar N, Samal SC. Unsuspected invasive neonatal gastrointestinal mucormycosis: A clinicopathological study of six cases from a tertiary care hospital. *J Indian Assoc Pediatr Surg.* 2012;17:153-56.
- [5] Agrawal P, Saikia U, Ramanaathan S, Samujh R. Neonatal small intestinal zygomycosis misdiagnosed as intussusception in a two-day-old child with a review of the literature. *Fetal Pediatr Pathol.* 2013;32:418-21.
- [6] Siu KL, Lee WH. A rare cause of intestinal perforation in an extremely low birth weight infant – gastrointestinal mucormycosis: A case report. *J Perinatol.* 2004;24:319-21.
- [7] Dhingra KK, Mandal S, Khurana N. Unsuspected intestinal mucormycosis in a neonate presenting as necrotizing enterocolitis(NEC). *Eur J Pediatr Surg.* 2008;18:119-20.
- [8] Kataria R, Gupta DK, Mitra DK. Colonic mucormycosis in a neonate. *Pediatric Surgery International.* 1995;10:271-73.
- [9] Alexander P, Alladi A, Correa M, D'cruz AJ. Neonatal colonic mucormycosis-a tropical perspective. *J Trop Pediatr.* 2005;51:54-59.
- [10] Budhiraja S, Sood N, Singla S, Gupta V. Gastrointestinal mucormycosis in a neonate: Survival without antifungal therapy. *Indian J Gastroentero.* 2007;26:198.

PARTICULARS OF CONTRIBUTORS:

1. Associate Professor, Department of Pathology, Seth G. S. Medical College and KEM Hospital, Mumbai, India.
2. Assistant Professor, Department of Pathology, Seth G. S. Medical College and KEM Hospital, Mumbai, India.
3. Professor, Department of Pathology, Seth G. S. Medical College and KEM Hospital, Mumbai, India.

NAME, ADDRESS, E-MAIL ID OF THE CORRESPONDING AUTHOR:

Dr. Pragati Aditya Sathe,
A/7, Jeevan Sudha Society, C.D. Barfiwala Road, Andheri West, Mumbai-400058, India.
E-mail: pragatv@yahoo.com

Date of Submission: **Feb 05, 2015**
Date of Peer Review: **May 18, 2015**
Date of Acceptance: **Jun 07, 2015**
Date of Publishing: **Aug 01, 2015**

FINANCIAL OR OTHER COMPETING INTERESTS: None.