

# Appendicitis in Postpartum Period: A Diagnostic Challenge

DIVYA WADHAWAN<sup>1</sup>, SEEMA SINGHAL<sup>2</sup>, NIVEDITIA SARDA<sup>3</sup>, RENU ARORA<sup>4</sup>

## ABSTRACT

Infections that occur in the postpartum period are assumed to be related to pregnancy or delivery; however other causes should also be considered. Appendicitis is one of the most common conditions requiring laparotomy during pregnancy, but very few cases of postpartum appendicitis have been reported. We report two such cases and the challenges faced by clinicians in diagnosis of immediate postpartum appendicitis. The first case was managed on lines of puerperal sepsis and the second one as enteric fever. Appendicular pathology was detected incidentally on laparotomy. In postpartum patients with no obvious focus of sepsis, appendicitis should be kept in mind. A team approach involving sensitized obstetricians and surgeons is likely to reduce serious morbidities.

**Keywords:** Appendicular pathology, Laparotomy in puerperium, Puerperal sepsis

## CASE REPORT

### CASE 1

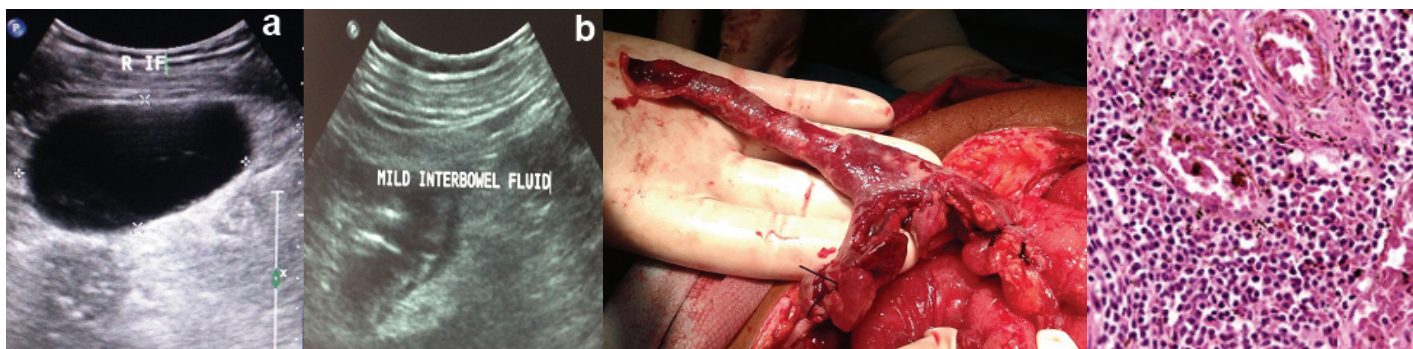
A 23-year-old, G3P2L1 female presented with 28 weeks of pregnancy and leaking per vaginum with labour pains and normal blood counts. She had an uneventful vaginal delivery. On first postpartum day, she developed high grade fever and mild pain abdomen. On examination her pulse rate was 112/min and respiratory rate was 34 per min. Per abdomen examination revealed a soft mildly distended, non-tender abdomen without guarding or rigidity & uterus was well contracted. Lochia was healthy. On 2<sup>nd</sup> postpartum day she had high grade fever with polymorphonuclear leukocytosis. Ultrasonography revealed minimal free fluid in pelvis with no retained products of conception. A clinical diagnosis of puerperal sepsis was considered and patient was started on injectable antibiotics. However, patient did not respond and had a rising trend of TLC. Ultrasound was repeated and it showed ascites with loculated collection in pouch of Douglas [Table/Fig-1a,b]. She was taken up for laparotomy with a provisional diagnosis of pelvic abscess. Intraoperatively, loculated pus collections were found throughout the abdomen. On exploration, an appendicular abscess was detected and appendectomy was performed. Uterus, fallopian tubes and ovaries were normal. Histopathology also confirmed the diagnosis of gangrenous appendicitis. In postoperative period she had burst abdomen, however, she gradually improved and was discharged on 15<sup>th</sup> postoperative day.

### CASE 2

A 27-year-old female, presented with history of preterm vaginal delivery. On first postpartum day, she developed low grade fever and abdominal pain. Subsequently, she was diagnosed as enteric fever, however, did not respond to injectable antibiotics and had continuous abdominal pain, high grade fever and vomiting. She was referred to us on day 17 as a case of puerperal sepsis. On admission pulse rate was 130/min, BP was 90/60mm of Hg, respiratory rate was 45/min, diffuse tenderness and guarding was present. Ultrasound revealed gross free fluid in peritoneal cavity with septations and the uterus was empty. Exploratory laparotomy was performed and 1.5 liter of pus was drained. An elongated, edematous, inflamed structure was found stuck with anterior abdominal wall which turned out to be appendix [Table/Fig-2], other organs were normal. Appendectomy was performed and she had an uneventful postoperative recovery. Appendicitis was confirmed later on histopathological examination [Table/Fig-3].

## DISCUSSION

Infections that occur in the postpartum period are assumed to be related, to pregnancy or delivery. The focus of puerperal morbidity should not be limited to uro-genital causes and non-urogenital causes of sepsis should also be considered. Appendicitis is one of the commonest non urogenital causes of puerperal morbidity [1]. The diagnosis of appendicitis in postpartum period remains a dilemma for both obstetricians and surgeons. The clinical features



[Table/Fig-1a,b]: Ultrasound films showing free fluid in Right para colic gutter with mild inter bowel fluid [Table/Fig-2]: Intraoperative photograph of Gangrenous Appendicitis [Table/Fig-3]: High power magnification showing suppurative appendicitis

are atypical and there is often an overlap of symptoms with other more common urogenital and non urogenital infections in immediate postpartum period which include puerperal endometritis, urinary tract infection, adnexal torsion, tubo-ovarian abscess, ovarian vein thrombosis, septic pelvic thrombophlebitis, pyelonephritis, pneumonia and cholecystitis [2]. Appendicitis is also described as one of the causes of continued puerperal sepsis. In a series of 52 cases of appendicitis in pregnancy by al Mulhim et al., [3], 3 patients (6%) presented in the puerperium. In another series by To WW et al., [4] 4 out of 31 patients (13%) presented with appendicitis in puerperium.

In the above cases provisional diagnosis of puerperal endometritis and enteric fever was considered and patients were managed on those lines. Although, pain and fever was present in first case and triad of acute appendicitis in second case, differential diagnosis of appendicitis was not considered. Usually appendix gets displaced during pregnancy with increased separation of peritoneum leading to decreased perception of somatic pain and localization, hence, abdominal pain may be inconclusive as a symptom [5]. Abdominal guarding and rigidity may be missed during puerperium, because of decreased muscle tone and white blood cell count and erythrocyte sedimentation rate are elevated due to physiological changes, making the diagnosis even more difficult [6].

Perforated appendicitis is known to cause preterm labour [7] and both the above cases had preterm labour. In hindsight, we believe that acute appendicitis in both the patients might have led to preterm labour. In another series of 22 patients of appendicitis and pregnancy five patients had preterm labour and all of them were found to have perforated appendix on laparotomy [7]. However, none of our patients complained of abdominal pain at presentation, either there was no pain or clinicians and patient were more concerned with labour pains or leaking per vaginum. In both the cases appendicular pathology was detected only during surgery.

There is release of inflammatory mediators during child birth that could aggravate an underlying subclinical process and result in frank disease expression in early puerperium. Altered physiology along with delayed diagnosis in puerperium is associated with a greater risk of perforation peritonitis, sepsis and mortality [1,8].

Imaging modalities are useful to reduce the incidence of negative laparotomies. USG helps to rule out other causes and CT scan is considered ideal for diagnosis in postpartum period.

## CONCLUSION

Appendicitis may be a cause of undetected, refractory sepsis in the postpartum period. It has a more calamitous outcome than appendicitis in other stages of pregnancy; therefore, a high level of clinical suspicion should help in clinching early diagnosis and surgical management. In postpartum patients with no obvious focus of sepsis, appendicitis should be kept in mind. A team approach involving sensitized obstetricians and surgeons is likely to reduce serious morbidities.

## REFERENCES

- [1] Belfort MA, Clark SL, Saade GR, et al. Hospital readmission after delivery: evidence for an increased incidence of nonurogenital infection in the immediate postpartum period. *Am J ObstetGynecol.* 2010;202:35.e1-7.
- [2] Basili G, Romano N, Bimbi M, Lorenzetti L, Pietrasanta D, Goletti O. Postpartum Ovarian Vein Thrombosis. *JSLs.* 2011;15(2):268-71.
- [3] Al-Mulhim AA. Acute appendicitis in pregnancy. A review of 52 cases. *Int Surg.* 1996;81(3):295-97.
- [4] To WW, Ngai CS, Ma HK. Pregnancies complicated by acute appendicitis. *Aust N Z J Surg.* 1995;65(11):799-803.
- [5] Gerstle RK. Postpartum Appendicitis Presenting as RUQ Pain. *Am Fam Physician.* 2008;77(3):282.
- [6] Brennan DF, Harwood-Nuss AL. Postpartum abdominal pain. *Ann Emerg Med.* 1989;18(1):83-89.
- [7] Tracey M, Fletcher HS. Appendicitis in pregnancy. *Am Surg.* 2000;66(6):555-59.
- [8] Savic M, Zaklina, Zikic S, Mitic D. Unrecognized perforated appendicitis in the third trimester of pregnancy: Case report. *Timockimedicinskiglasnik.* 2010;35(3-4):85-88.

### PARTICULARS OF CONTRIBUTORS:

1. Senior Resident, Department of Obstetrics and Gynaecology, VMMC and Safdarjang Hospital, New Delhi, India.
2. Associate Professor, Department of Obstetrics and Gynaecology, VMMC and Safdarjang Hospital, New Delhi, India.
3. Consultant and Professor, Department of Obstetrics and Gynaecology, VMMC and Safdarjang Hospital, New Delhi, India.
4. Consultant and Associate Professor, Department of Obstetrics and Gynaecology, VMMC and Safdarjang Hospital, New Delhi, India.

### NAME, ADDRESS, E-MAIL ID OF THE CORRESPONDING AUTHOR:

Dr. Seema Singhal,  
E 2, Ansari Nagar (West), AIIMS Campus, New Delhi, India.  
Email: drseemasinghal@gmail.com

FINANCIAL OR OTHER COMPETING INTERESTS: None.

Date of Submission: **Nov 04, 2014**

Date of Peer Review: **Jan 28, 2015**

Date of Acceptance: **Apr 28, 2015**

Date of Publishing: **Oct 01, 2015**