

JOURNAL OF CLINICAL AND DIAGNOSTIC RESEARCH

How to cite this article :

Gopal Y, Mallabadi R. FULL MOUTH REHABILITATION. Journal of Clinical and Diagnostic Research [serial online] 2007 April [cited: 2007 April 2]; 1:143-146.

Available from

[http://www.jcdr.net/back_issues.asp?issn=0973-](http://www.jcdr.net/back_issues.asp?issn=0973-709x&year=2007&month=April&volume=1&issue=2&page=143-146id=16)

[709x&year=2007&month=April&volume=1&issue=2&page=143-146id=16](http://www.jcdr.net/back_issues.asp?issn=0973-709x&year=2007&month=April&volume=1&issue=2&page=143-146id=16)

CASE REPORT

Full Mouth Rehabilitation

GOPAL Y, MALLABADI R

ABSTRACT

Full mouth rehabilitation cases are one of the most difficult cases to manage in dental practice. This is because such cases involve not only replacement of the lost tooth structure but also restoring the lost vertical dimensions. Full mouth reconstruction is basically a set of procedures that are aimed at correcting an improper bite position as well as restoring chipped or worn out teeth. Improper jaw position is implicated in various neuro-muscular disorders as well as in headache and neck ache. Correcting the jaw position not only restores proper function, but also helps in enhancing the cosmetic appearance of the patient.

CASE REPORT

Described below is the full mouth reconstruction with rampant caries.

Chief Complaint

Patient arrived at the office complaining of:

1. Leakage of saliva while talking
2. Hoarseness of voice
3. Chipped roots & teeth.

Investigations Undertaken

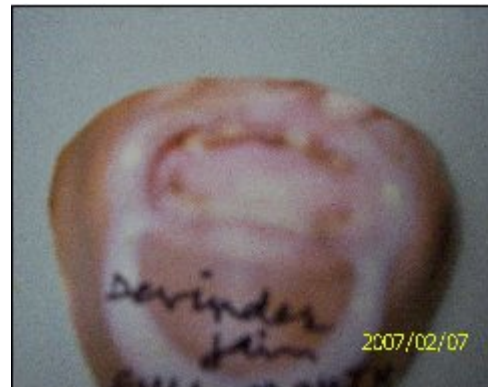
1. Full mouth IOPA x-rays
2. Routine medical check up

Provisional Diagnosis

Rampant caries along with generalized attrition. After a thorough examination, the following treatment plan was advised.

Treatment Plan

First of all periodontium was examined thoroughly, both clinically and radiographically. Secondly, endodontic therapy of all pulp involving teeth as a basic step should be done



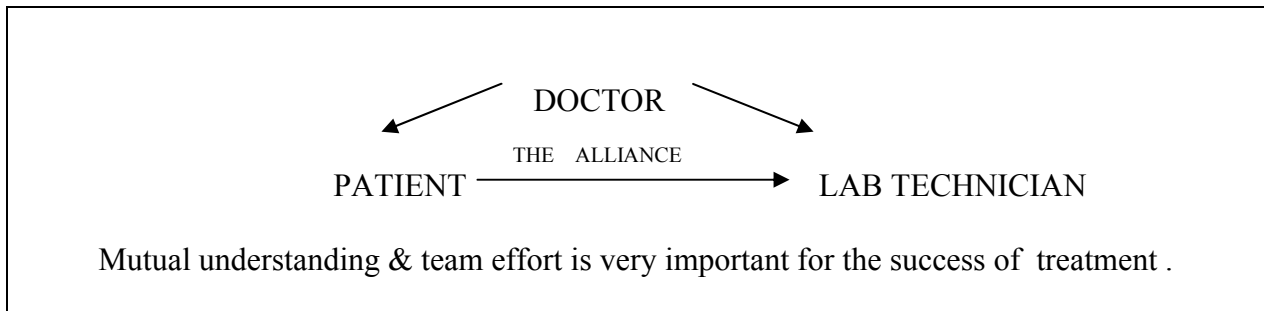
Table/Fig1. Pre-operative photograph demonstrating gross wear & tear of all teeth and loss of vertical dimension .

Treatment Rationale

The main aim of the treatment plan was to raise the vertical dimensions by increasing the height of molars.

Procedure

Alginate impression of upper & lower teeth was made and study casts were made. Two sets of study casts were prepared, one for lab technician & the other for the doctor



Notation

17,16,15,14,13,12,11,21,22,23,24,25,26,27

48,47,46,45,44,43,42,41,31,32,33,34,35,36,37

Teeth no.25 and 48 could not be restored because these were grossly decayed & infected, and therefore needed extraction. Teeth no.17, 26,27,34,36 did not require endodontic therapy and were restored as such. Endodontic therapies were started for the remaining teeth. There were a total of 20 teeth in the mouth which required extensive endodontic therapy. The most important step in this case was to **raise vertical dimension - V D**.

Method

Two equal lengths of pink modeling wax were taken. Some glass beads from glass bead sterilizer, around 2 mm in diameter, were packed in the folds of wax sheet & placed in between posterior teeth. Now, the patient was asked to bite on the wax sheet gently. Glass beads present in the wax bite help in giving 2 mm of free space required. After this, upper & lower jaw impressions were made using alginate impression material. Stone plaster was poured & models prepared. Recorded wax bite was placed in between upper & lower casts and articulation was accomplished as per the requirements of the patient.

Sequence Of Temporization

Firstly, upper posterior crowns were made with well formed cusps & fossae. For this, we had the option to choose prefabricated stainless steel crowns for exact anatomy.

Afterwards, lower posterior crowns were prepared in occlusion with the upper crowns. There should be good cusp to fossa relationship and Angel's class-I relation should be established, wherein the mesio

buccal cusp of upper first permanent molar should fall into mesio buccal groove of lower first permanent molar.

Occlusion is set in patient's mouth because of his jaw deviation and unbalanced occlusion. Articulating paper is used to remove high points and establish correct occlusion. For this, repeated visits are required for proper setting of crowns. This is a very important step, as the success of the full mouth rehabilitation hinges on correct setting of the crowns. Wherever the occlusion is set now, permanent crowns will be set in the same plane. While grinding temporary crowns for occlusion correction, occlusal table is also sometimes required to be narrowed down. Once the posterior crowns were set, then anterior crowns were built up. Screwed posts are used as retentive forms. Light cure composite is used to prepare core. For incisal plane, upper lip line is used as guide plane.

31, 21, 11,21,22,23 }
43, 42, 41,31,32,33 } are raised but
traumatic occlusion must be avoided at all costs.

After making anterior teeth, following changes were observed in the patient:

1. There was increase in confidence on the face of patient.
2. Looked younger.
3. Facial musculature became prominent. Wrinkles disappeared. Masseter muscle over closure was decreased.
4. Voice was clearer.
5. Sprinkling of saliva droplets while talking, stopped.
6. Gastric trouble due to improper chewing of food was relieved.
7. Three basic functions of teeth - mastication, aesthetics & phonetics were improved.

Technique of Replacing Posterior Temporary Crowns with PFM (Ceramic) Crowns

We divided full mouth into four quadrants ---

Upper right	Upper left
Lower right	Lower left

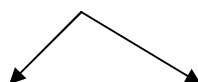
One quadrant is dealt with at one time and one guide for occlusion is left quadrant on each side. For example, while dealing with right side we can leave upper & lower 2nd molar as guide for occlusion.

Step 1 – We removed 16, 15, 14 temporary crowns and made an alginate impression. Impression contained 16, 15, 14 retainers & 17 crown. The lower impression was also made along with crowns, & poured. These upper & lower casts were sent to the lab for the fabrication of 16, 15, and 14 PFM crowns. These crowns will be finally glazed ones.

Step 2 - We removed right lower crowns leaving 47 in mouth as occlusal guide. After pouring the impressions, the casts were sent to the lab. We'll have to adjust some occlusion due to unbalanced occlusion in patient's mouth.

Step 3 – We Removed 17, 47 temporary crowns leaving 16, 15, 14 (in final glazed form) & 46, 45, 44 (brisk form) in mouth. Made impressions. Removed 46, 45, and 44 (in brisk form) crowns and then repeat lower impression. Sent impression casts --- one upper

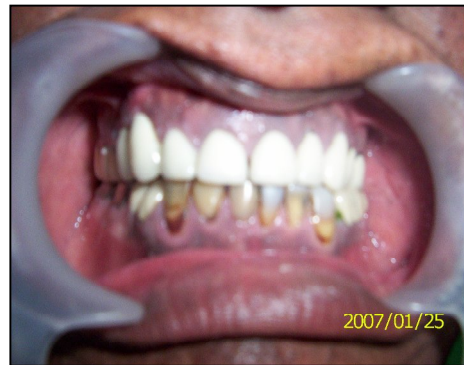And ----- two lower



With 46, 45, 44 without 47,46,45,44

to the lab. 46, 45, 44 in brisk form also sent along with the impression casts for making final. After

this one side(right side) was ready, three steps were done for the other side.



Table/Fig 2. Improved appearance after teeth restoration

Note - In case of multiple crowns, the order in which one makes trial, should remain the same while cementing the crowns e.g. in case of 47,46,45,44, one starts from 47 to 44, then cementation should also follow the same order and not the reverse.

Conclusion

Full Mouth Rehabilitation is very useful in correcting improper bite positions and also in augmenting the smile. In this case, the procedure acted as a template for the eruption of permanent teeth. More often than not, young children are good candidates for the procedure because the permanent teeth are yet to erupt. This gives the dentist an opportunity to shape and guide the occlusion in the permanent teeth.

The latest technology used to assist doctors in determining the jaw positions is called Tens, which is a low level electrical impulse machine that massages the muscles and releases the tension built up as a result of muscle overuse in imbalanced jaw positions.

Generally speaking the recovery stage is one of the most important stages in this procedure. Patients need to be constantly monitored for at least 12 months after the procedure in order to ensure that they do not accidentally revert to the previous jaw positions.

Conflict of Interest: None declared

References

[1] Bernardo JK, Maia EA, Cardoso AC, de Araujo Junior EM, Monteiro Junior S. Diagnosis and management of maxillary incisors affected by incisal wear: an

interdisciplinary case report; J Esthet Restor Dent. 2002;14(6):331-9.

[2] Versloot J, Veerkamp JS, Hoogstraten J. Dental Discomfort Questionnaire for young children following full mouth rehabilitation under general anaesthesia: a follow-up report. Eur Arch Paediatr Dent. 2006 Sep;7(3):126-9.

[3] Kirtley GE. Metal-composite copings in the aesthetic restoration of the severely compromised patient. Pract Proced Aesthet Dent. 2006 Mar;18(2):105-10; quiz 112, 122.

[4] Nash RW. Functional and esthetic rehabilitation using a Captek bridge and crowns opposing laminate porcelain veneers. Compend Contin Educ Dent. 1999 Feb;20(2):176-83.

[5] Landman P. Restoring aesthetics and vertical dimension in a bruxism case. Dent Today. 2000 Oct;19(10):80-4.