

# Primary Gastro Intestinal Lymphoma Presenting as Perforation Peritonitis

SUHAIB ABDUL REHAMAN<sup>1</sup>, CHANDRASHEKAR SHASTRY RAMACHANDRA<sup>2</sup>, REUBEN PRAKASH JACKAYA<sup>3</sup>

## ABSTRACT

Primary gastrointestinal lymphoma is very rare compared to gastrointestinal tract lymphoma arising Secondary to Primary nodal disease. Extra nodal lymphoma can involve any part of the gastrointestinal tract, most commonly being the stomach followed by small intestine and ileocecal region. They are indistinguishable from other benign and malignant conditions and clinically non-specific. Here, we have an interesting case where a patient presented with peritonitis and was found to have a perforated swelling in jejunum. Subsequently resection and anastomosis was done. Biopsy showed lymphoma. Patient was evaluated further by doing CECT of abdomen and thorax, which didn't show any other site of lymphadenopathy. Patient improved with chemotherapy and is on regular follow up. Perforation in patient undergoing treatment for lymphoma are common but presentation of primary gastrointestinal lymphoma as perforation is rare and needs proper evaluation and management.

**Keywords:** Intestinal perforation, Large B cell lymphoma, Lymphoma Non-hodgkins.

## CASE REPORT

A 47-year-old male patient presented with pain abdomen since 1 day. It was confined to epigastrium without any history of fever, vomiting, loose stools or constipation. No history of peptic disease in past. No history of fever, night chills or any lumps. On examination patient was tachycardic. Other vitals were stable. Abdomen was soft with tenderness confined to epigastrium. There was no guarding or rigidity. There was no obliteration of liver dullness. No hepato splenomegaly. Bowel sounds were sluggish. Rectal examination was normal. Other systems were normal.

Blood investigations showed total count of 11,000cells/cc with neutrophils comprising 76%. Other blood investigations including Serum amylase and lipase were normal. Ultrasound of abdomen showed features suggestive of Hollow viscus perforation. Erect chest X-ray showed thin rim of air under right diaphragm [Table/Fig-1]. Exploratory laparotomy was done with provisional diagnosis of hollow viscus perforation. Midline incision was given and the abdomen was opened in layers. We found a mass of about 4cm in mid part of jejunum with a perforation in the antimesenteric border, of about 1cm, at the proximal part of the mass [Table/Fig-2]. Resection of jejunum segment with the mass and the mesentery was done followed by end to end anastomosis. Whole bowel was examined for any other mass or swelling. Liver and peritoneum were normal. Abdomen was closed with a drain near perforation.

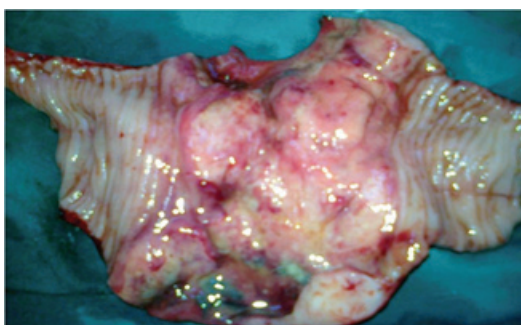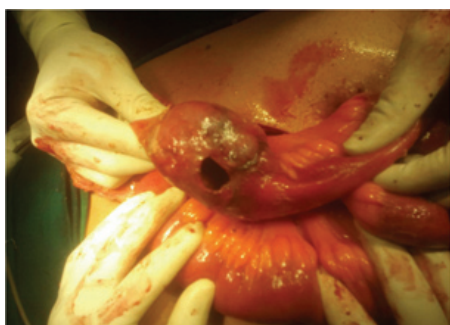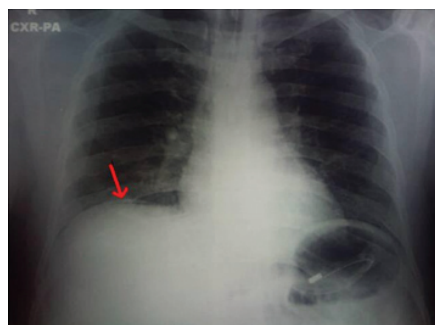The gross specimen showed segment of small intestine with the mesentery, measuring 10cm in length and 4cm in maximum diameter [Table/Fig-3]. Serosa shows a perforated area measuring 1x1cm. Cutting through antimesenteric border, lumen showed

ulceroproliferative neoplasm measuring 5x5x3 cm with cut section showing grey white, granular tissue infiltrating into serosa creating perforation. The microscopic sections studied from the growth shows a neoplasm composed of lymphoid cells arranged in sheets. Cells were 2-3 times the size of small mature lymphocytes, having vesicular nucleus with prominent nucleoli [Table/Fig-4]. Moderate nuclear pleomorphism was noted. Mitosis 1-2 /hpf and no areas of necrosis seen. The Immuno histochemistry was Positive for CD-20 and negative for Cytokeratin and CD-3 [Table/Fig-5]. Based on clinical and histopathological findings diagnosis of Diffuse Large B cell Lymphoma was made.

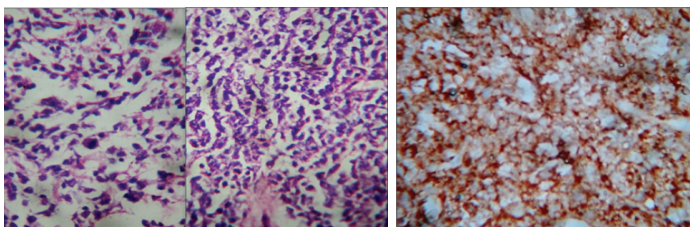
Post-op patient was started orally after 3 days, drain was removed on 7<sup>th</sup> post-op day and staples removed on 10<sup>th</sup> post-op day. Patient underwent CECT abdomen and chest to rule out any other site of lymphadenopathy. No evidence of lymphadenopathy was found in any other site. Peripheral smear was normal. Patient was staged as Stage I category patient according to Modified Ann Arbor staging and stage III according to the International Workshop. Patient was started on chemotherapy in follow up. Patient received 6 cycles of CHOP (Cyclophosphamide, Hydroxydoxorubicin, Oncovin and Prednisolone) regimen of chemotherapy. Patient was regularly followed up in the OPD every month upto 6 months and every 3 months upto 2 years and was doing well.

## DISCUSSION

Lymphoma of gastrointestinal tract is primary or secondary as part of systemic process. It accounts for 15-20% of all cases of NHL [1]. Some studies suggest an incidence of about 11-34%



[Table/Fig-1]: Erect Chest X-ray showing thin rim of air under right Diaphragm. [Table/Fig-2]: On table photograph, showing the jejunal mass with perforation. [Table/Fig-3]: Gross specimen after lay opening showing ulceroproliferative lesion.



**[Table/Fig-4]:** Microscopic images (H and E stain) (400x).

**[Table/Fig-5]:** IHC-CD20 positive (400x).

in all Non-Hodgkin's Lymphomas [2]. Primary gastrointestinal lymphoma, as compared to all GI malignancies is very rare, constituting only about 1%-4% of all gastrointestinal malignancies [3]. The most frequent sites of extranodal lymphoma in order of its occurrence are - the stomach, small intestine and ileocecal region [3]. The most common pathological type of gastrointestinal lymphoma in all sites of the gastrointestinal tract is Diffuse Large B-cell Lymphoma, even though other types have been shown to increase recently [3].

Some risk factors which have been found to be taking part in the pathogenesis of gastrointestinal lymphoma are Coeliac disease, *Helicobacter pylori* infection, *Campylobacter jejuni*, virus infection like HIV, EBV, HBV and HTLV-1, inflammatory bowel disease, Wegener's granulomatosis, rheumatoid arthritis, Wiskott-Aldrich syndrome and immunosuppression [1,4].

Ann Arbor staging is commonly employed to stage gastrointestinal lymphoma and the international prognostic index has been used to define the prognostic subgroups [Table/Fig-6,7]. Accurate staging and diagnosis of gastrointestinal lymphoma are important for planning the treatment in this heterogeneous group of lymphoma. Some still prefer the staging for Gastrointestinal NHL according to international workshop [5].

Criteria for labelling primary gastrointestinal lymphoma includes: Absence of peripheral lymphadenopathy at presentation, Total and differential white blood cell showing normal count, Lack of enlarged central lymph nodes, No lymphoma involvement of liver and spleen: Predominance of bowel lesion at the time of laparotomy with only involved lymph nodes in the immediate vicinity [6,7].

Primary lymphoma is usually localized to a single segment of intestine. Multicentricity occurs in 15 to 20% of cases [1]. Small intestinal lymphomas are usually large; 70% are greater than 5 cm. Gross appearance can be aneurysmal, ulcerative, polypoid, or annular. Tumour may invade and ulcerate the mucosa and extend through the serosa. Majority of primary intestinal NHL are B-cell type. T-cell lymphoma comprises only 10–25%. T-cell lymphomas tend to have a worse prognosis than B-cell tumours [8]. Most small bowel lymphomas are intermediate- to high-grade tumours. Some histological subtypes have been noted to occur at particular site as Mucosa-Associated Lymphoid Tissue lymphoma (MALT) in

I <sub>E</sub>	Tumour confined to small intestine without Nodal Involvement
II <sub>E</sub>	Regional Lymph node involvement
III <sub>E</sub>	Involvement of non resectable lymph nodes beyond regional basin
IV <sub>E</sub>	Spread to other nonlymphatic organs

**[Table/Fig-6]:** Modified Ann Arbor Classification of Primary Non-Hodgkin's Gastrointestinal Lymphoma [1].

I	Tumour confined to the gastrointestinal (GI) tract (Single primary site or multiple non-contiguous lesions)
II	Tumour extending in abdomen from primary GI site II1 - Local (paragastric or paraintestinal) II2 - Distant (mesenteric, para-aortic, paracaval, pelvic, inguinal)
III	Penetration of serosa to involve adjacent organs or tissues
IV	Disseminated extranodal involvement or a GI tract lesion with supradiaphragmatic nodal involvement

**[Table/Fig-7]:** Staging of gastrointestinal non-Hodgkin's lymphoma (GI-NHL) according to the International Workshop [5].

stomach, Mantle Cell Lymphoma (MCL) in terminal ileum, jejunum and colon, as well as Enteropathy-Associated T-cell Lymphoma (EATL) in jejunum, and Follicular Lymphoma (FL) in duodenum with a geographic variation in its distribution [9,10]. Microscopically DLBCL shows large cells which may be cleaved, non cleaved or immunoblastic. It may show lineage of B-cell by being positive for B-cell antigens (CD 20, CD 22, CD 19, CD 70A, and BSAP/PAX5) and very rarely positive for germinal centre cell markers (BCL6 and CD 10) [9].

Clinical presentation may vary from nonspecific abdominal complaints (fatigue, malaise, weight loss, and abdominal pain), Malabsorption, obstruction, or palpable mass may be present. Very rarely, small intestinal lymphomas may present with perforation. Males have more tendency to have perforation than females [11]. B-cell aggressive lymphoma was associated with more chances of perforation than in B-cell indolent lymphoma [11]. A study Group on intestinal NHL reported a lesser incidence of perforation in intestinal B-cell compared with T cell lymphomas [12].

In small bowel lymphomas CT scan may show findings like a mass, bowel wall thickening, displacement of adjacent organs, or luminal obstruction. Multiple lesions are present in 10–25% of patients. Biopsy of the submucosal lesion is done by endoscopy or CT guided biopsy, which may help in diagnosis.

Treatment of localized (stage I<sub>E</sub> and stage II<sub>E</sub>) lymphoma involves resection of the involved segment and adjacent mesentery. Stage III<sub>E</sub> and stage IV<sub>E</sub> is treated with chemotherapy. The role of adjuvant therapy after curative resection for stage I<sub>E</sub> and stage II<sub>E</sub> lymphomas is controversial. The 5-year survival in patients with resectable lymphoma approaches 80% [1]. Surgery plays a limited role in diffuse cases, although it may be required for accurate diagnosis. Radiotherapy has been reported as beneficial as an adjuvant or palliative treatment [13].

One of the common complications of gastro intestinal lymphomas that can occur either at diagnosis or during the course of treatment is perforation and peritonitis. The occurrence of perforations is life threatening and can lead to morbidity from wound infection, increase in duration of hospital stay, MODS, SIRS, undue delays in chemotherapy and ultimately mortality. Many studies have reported poor outcome of gastro Intestinal lymphomas when complicated by perforation [2,14,15]. Perforation of GI tract lymphomas is a significant clinical complication even with modern tumour imaging methods and effective chemotherapy for lymphoma. A 9% was the rate of perforation in biopsy proven GI tract lymphomas in a study conducted by Vaidya et al., [11]. Comparing studies, higher percentage of perforations occurred in the small bowel (59%), compared with the stomach (16%) or large bowel (22%) [11]. Ara et al., reported similar findings in their case series of eight patients with bowel perforations from lymphoma, where six of the eight perforations occurred in the small bowel and only two involved the large bowel [16].

## CONCLUSION

Morbidity and mortality increases significantly in primary gastro intestinal lymphomas presenting as perforation, but with proper understanding of the disease and timely intervention, management will yield good results as we saw in our patient.

## ACKNOWLEDGMENTS

I would like to thank Dr. Sushma Krishnamoorthy and Dr. Pravin Borkar for their help and guidance.

## REFERENCES

- [1] Charles JY, George DZ, Shackelford's Surgery of the Alimentary tract. 6<sup>th</sup> edition. Saunders Elsevier; 2007. Ch 25(856-870).
- [2] Gou HF, Zang J, Jiang M, Yang Y, Cao D, Chen XC. Clinical prognostic analysis of 116 patients with primary intestinal non-Hodgkin Lymphoma. *Med Oncol*. 2012;29(1):227-34.

- [3] Ghimire P, Wu GY, Zhu L. Primary gastrointestinal lymphoma. *World J Gastroenterol*. 2011;17(6):697-707. (URL: <http://www.wjgnet.com/1007-9327/full/v17/i6/697.htm>)
- [4] Müller AM, Ihorst G, Mertelsmann R, Engelhardt M. Epidemiology of non-Hodgkin's lymphoma (NHL): trends, geographic distribution, and etiology. *Ann Hematol*. 2005;84:1-12.
- [5] Rohatiner A, d'Amore F, Coiffier B, et al. Report on a workshop convened to discuss the pathological and staging classifications of gastrointestinal tract lymphoma. *Ann Oncol*. 1994;5:397-400.
- [6] Johnston MR, de Perrot M. Lymphoma. In: Devita VT, Lawrence TS, Rosenberg SA, Weinberg RA, editors. *Cancer: Principles and Practice of Oncology*. 8<sup>th</sup> ed. Philadelphia: Lippincott Williams & Wilkins; 2008. Pp. 2476-92.
- [7] Dawson IM, Cornes JS, Morson BC. Primary malignant lymphoid tumours of the intestinal tract. Report of 37 cases with a study of factors influencing prognosis. *Br J Surg*. 1961;49:80-89.
- [8] Domizio P, Owen R, Shepherd N, et al. Primary lymphoma of the small intestine: A clinicopathological study of 119 cases. *Am J Surg Pathol*. 1993;17:429-42.
- [9] Rizvi MA, Evens AM, Tallman MS, Nelson BP, Rosen ST. T-cell non-Hodgkin lymphoma. *Blood*. 2006;107:1255-64.
- [10] Jaffe ES, Harris NL, Stein H, Isaacson PG. Classification of lymphoid neoplasms: the microscope as a tool for disease discovery. *Blood*. 2008;112:4384-99.
- [11] Vaidya R, Habermann TM, Donohue JH, et al. Bowel perforation in intestinal lymphoma: incidence and clinical features. *Annals of Oncology*. 2013;24:2439-43.
- [12] Daum S, Ullrich R, Heise W, et al. Intestinal non-Hodgkin's lymphoma: a multicenter prospective clinical study from the German Study Group on intestinal non-Hodgkin's lymphoma. *J Clin Oncol*. 2003;21:2740-46.
- [13] Dickson BC, Serra S, Chetty R. Primary gastrointestinal tract lymphoma: diagnosis and management of common neoplasms. *Expert Rev Anticancer Ther*. 2006;6:1609-28.
- [14] Amer MH, el-Akkad S. Gastrointestinal lymphoma in adults: clinical features and management of 300 cases. *Gastroenterology*. 1994;106:846-58.
- [15] Kako S, Oshima K, Sato M, et al. Clinical outcome in patients with small-intestinal non-Hodgkin lymphoma. *Leuk Lymphoma*. 2009;50:1618-24.
- [16] Ara C, Coban S, Kayaalp C, et al. Spontaneous intestinal perforation due to non-Hodgkin's lymphoma: evaluation of eight cases. *Dig Dis Sci*. 2007;52:1752-56.

**PARTICULARS OF CONTRIBUTORS:**

1. General and Laparoscopic Surgeon, Department of Surgery, National Hospital, Calicut, India.
2. Senior Consultant Surgeon, Department of Surgery, CSI H.M.Hospital, Mysore, India.
3. Senior Consultant Surgeon and Head of Department, Department of Surgery, CSI H.M. Hospital. Mysore, India.

**NAME, ADDRESS, E-MAIL ID OF THE CORRESPONDING AUTHOR:**

Dr. Suhaib Abdul Rehaman,  
House No:10, 6<sup>th</sup> Cross, Shivaji Road, N.R. Mohalla, Mysore-570007, India.  
E-mail: [suhaib\\_rehaman@yahoo.co.in](mailto:suhaib_rehaman@yahoo.co.in)

**FINANCIAL OR OTHER COMPETING INTERESTS:** None.

Date of Submission: **Jul 01, 2015**  
Date of Peer Review: **Aug 19, 2015**  
Date of Acceptance: **Jan 12, 2016**  
Date of Publishing: **Mar 01, 2016**